



## Image of the Month

## Abdominal Pain in an Elderly Man Secondary to Giant Sigmoid Diverticula<sup>☆</sup>



### Dolor abdominal en el anciano secundario a divertículo sigmoideo gigante

Rocío Ruiz Guardiola,<sup>\*</sup> Juana Luisa Huertas Riquelme, Julio Sánchez Corral, Beatriz Garrido Benito

Servicio de Cirugía General y del Aparato Digestivo, Hospital Marina Baixa, Villajoyosa, Alicante, Spain

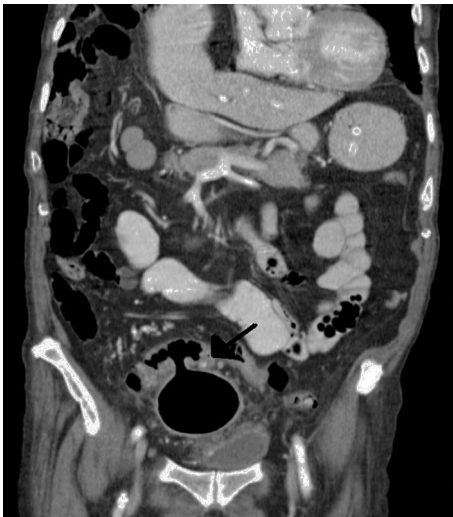

Fig. 1

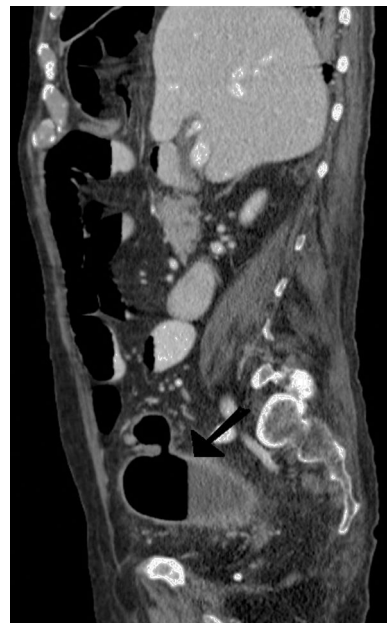


Fig. 2

The patient is a 93-year-old man with symptoms of diffuse abdominal pain, liquid diarrhea and vomiting over the previous 2 weeks. On examination, the patient presented a soft abdomen, with mild discomfort in the hypogastrium. Blood work revealed leukocyte levels of 15 000/ $\mu$ l and PCR 6 mg/dl. CT scan showed a large sigmoid diverticulum measuring 9.5 $\times$ 5.6 cm in the lower pelvis, with an air-fluid level, fecaloid content and inflammatory involvement of the adjacent fat, suggestive of acute diverticulitis (Figs. 1 and 2). The patient was hospitalized for medical treatment with intravenous antibiotics, with a favorable progress, so the patient was discharged seven days later.

<sup>☆</sup> Please cite this article as: Ruiz Guardiola R, Huertas Riquelme JL, Sánchez Corral J, Garrido Benito B. Dolor abdominal en el anciano secundario a divertículo sigmoideo gigante. Cir Esp. 2017;95:405.

<sup>\*</sup> Corresponding author.

E-mail address: [r Ruizguardiola@gmail.com](mailto:r Ruizguardiola@gmail.com) (R. Ruiz Guardiola).