



Image of the month

Ischioirectal Abscess With Intra and Preperitoneal Dissemination[☆]



Absceso isquiorrectal con extensión intra y preperitoneal

Natalia Rodríguez López,^{*} Ana María Paulos Gómez, Lucía Lesquereux Martínez, Manuel Bustamante Montalvo

Servicio de Cirugía General y del Aparato Digestivo, Hospital Clínico Universitario de Santiago de Compostela, Santiago de Compostela, A Coruña, Spain

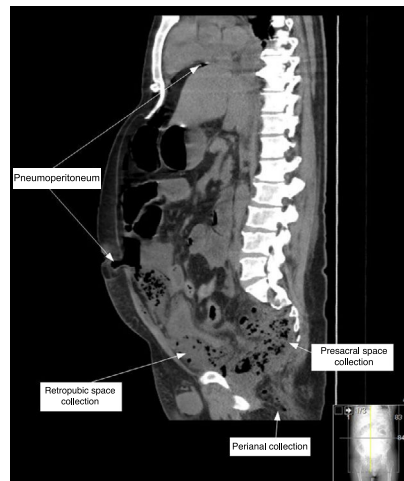


Fig. 1

The patient is a 50-year-old male with mental retardation, who reported vomiting after having undergone surgery for a left perianal abscess 10 days earlier. He presented abdominal distension, diffuse peritonism and right ischioirectal erythema. Abdominal computed tomography revealed pneumoperitoneum, intra-abdominal fluid and a fluid collection with gas in the presacral space, right Retzius and Bogros, with inflammatory alterations in the homolateral ischioirectal and ischioanal fossae (Fig. 1).

Midline laparotomy demonstrated pus coming out of the retropubic space, communicating with the right pararectal space, with extraperitoneal and perianal drainage, as well as diffuse purulent peritonitis, but no intraabdominal origin. A colostomy was created in the left iliac fossa.

The patient required prolonged hospitalization in the intensive care unit, with favorable evolution of the infection and wound. The patient did not require further surgery and was discharged on the 37th day post-op.

Diagnosis: perianal abscess with extension to the preperitoneal space and abdominal cavity.

[☆] Please cite this article as: Rodríguez López N, Paulos Gómez AM, Lesquereux Martínez L, Bustamante Montalvo M. Absceso isquiorrectal con extensión intra y preperitoneal. Cir Esp. 2017;95:295.

^{*} Corresponding author.

E-mail address: rodriguezlopeznatalia@gmail.com (N. Rodríguez López).