

splenic thrombosis, pleural effusion and incisional hernias, and a certain decrease in hospital stay.<sup>1,2</sup>

In conclusion, LPS is a demanding but valid technique that is feasible in the treatment of splenic lesions, especially those located in the poles of the spleen, that reduces certain postoperative complications and maintains splenic immunological function.

#### REFERENCES

- Balaphas A, Buchs NC, Meyer J, Hagen ME, Morel P. Partial splenectomy in the era of minimally invasive surgery: the current laparoscopic and robotic experience. *Surg Endosc.* 2015;29:3618-27.
- Lee SH, Lee JS, Lee SH, Yoon YH, Hong TH. Role of laparoscopic partial splenectomy for tumorous lesions of the spleen. *J Gastrointest Surg.* 2015;19:1052-8.
- Wang X, Wang M, Zhang H, Peng B. Laparoscopic partial splenectomy is safe and effective in patients with focal benign splenic lesion. *Surg Endosc.* 2014;28:3273-8.
- Ingle SB, Hinge CR, Patrike S. Epithelial cysts of the spleen. *World J Gastroenterol.* 2014;20:13899-903.
- Szczepanik AB, Meissner AJ. Partial splenectomy in the management of non parasitic splenic cysts. *World J Surg.* 2009;33:852-6.
- Hery G, Becmeur F, Mefat L, Kalfa D, Lutz P, Lutz L, et al. Laparoscopic partial splenectomy: indications and results of a multicenter retrospective study. *Surg Endosc.* 2008;22:45-9.
- Uranues S, Grossman D, Ludwig L, Bergamaschi R. Laparoscopic partial splenectomy. *Surg Endosc.* 2007;21:57-60.
- Cai YQ, Li CL, Zhang H, Wang X, Peng B. Emergency laparoscopic partial splenectomy for ruptured spleen: a case report. *World J Gastroenterol.* 2014;20:17670-3.
- Han XL, Zhao YP, Chen G, Wu WM, Dai MH. Laparoscopic partial splenectomy for splenic hemangioma: experience of a single center in six cases. *Chin Med J.* 2015;128:694-7.
- Ran B, Shao Y, Yimiti Y, Aji T, Sayding P, Jiang T, et al. Spleen-preserving surgery is effective for the treatment of spleen cystic echinococcosis. *Int J Infect Dis.* 2014;29:181-3.

José M. Ramia\*, Roberto de la Plaza Llamas, Aylhin Joana López-Marcano, José del Carmen Valenzuela Torres, José Manuel García Gil

Unidad de Cirugía Hepatobiliopancreática, Servicio de Cirugía General y Aparato Digestivo, Hospital Universitario de Guadalajara, Guadalajara, Spain

\*Corresponding author.

E-mail address: jose\_ramia@hotmail.com (J.M. Ramia).

2173-5077/

© 2017 AEC. Published by Elsevier España, S.L.U. All rights reserved.

## Recurrent Tracheoesophageal Fistula Repair With Gastro-Omental Free Flap in an Irradiated Patient<sup>☆</sup>



## Reparación de fístula traqueoesofágica recurrente con colgajo gastro-omental libre en un paciente irradiado

Tracheoesophageal puncture (TEP) and prosthesis insertion has become the technique of choice for voice and speech restoration in patients undergoing total laryngectomy.

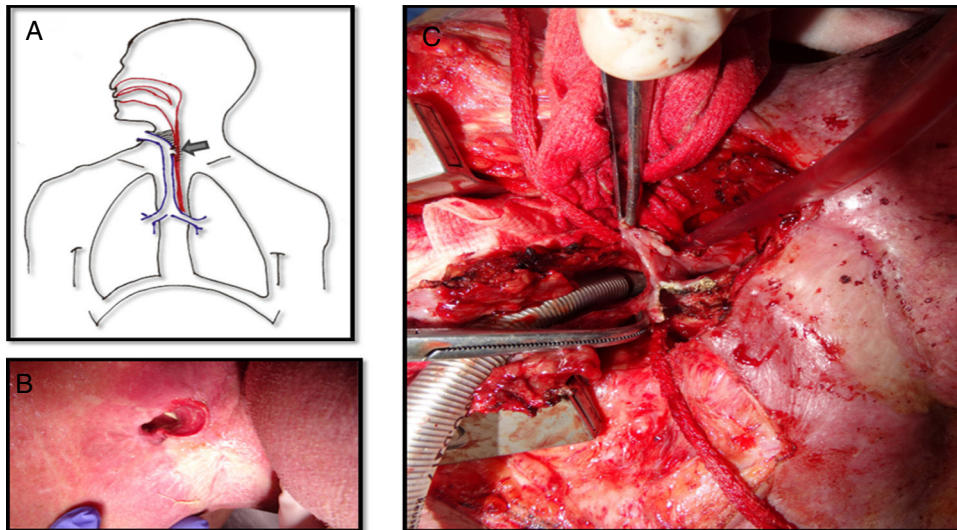
Enlargement of the tracheoesophageal fistula (TEF) may lead to leakage and aspiration of liquids causing severe complications such as aspiration pneumonia, vascular breakdown and even death.<sup>1,2</sup>

We report a case of a salvage reconstruction with a gastro-omental flap in a large persistent TEF in a 71 year old man in whom conservative treatment and the interposition of a muscular flap had failed and whose local and general physical condition made the resolution of the fistula particularly difficult. The application of this free flap in the context of a TEF has not been described to date.

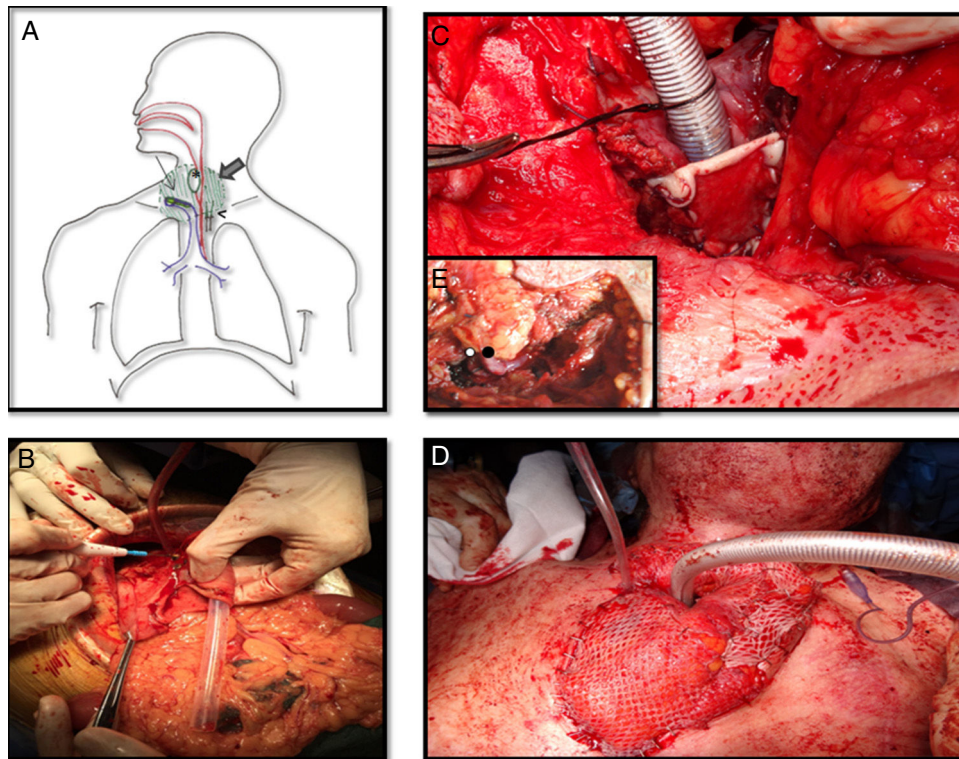
The patient had been treated eight years before for supraglottic squamous carcinoma with total laryngectomy and bilateral radical modified neck dissection therapy with the intraoperative insertion through a tracheoesophageal puncture (TEP) of a prosthesis (Provox) that allowed a successful speech rehabilitation. Postoperative Radiation therapy was performed.

During the patient follow-up at least two hospitalization episodes for bronchospirative pneumonia occurred due to a widening of the tracheoesophageal puncture. After some initial failed attempts to solve the problem with either removing temporary the prosthesis or placing a silastic lamina to close leakage zones between the Provox and the fistula, a silicone button was placed into the fistula with a rigid bronchoscope. It seemed that a definitive closure of the

<sup>☆</sup> Please cite this article as: Viñals Viñals JM, Tarrús Bozal P, Serra-Mestre JM, Bermejo Segú O, Nogués Orpí J. Reparación de fístula traqueoesofágica recurrente con colgajo gastro-omental libre en un paciente irradiado. *Cir Esp.* 2017;95:615-617.



**Fig. 1** - A. Picture showing the tracheoesophageal fistula with lot of fibrosis around it. B. The nasogastric tube is visualized through the tracheostoma which confirms a large fistula at this level. C. The trachea is detached from the esophagus. The posterior wall of the trachea has already been removed because the tissue was necrotic. The defect on the anterior wall of the esophagus is visualized.



**Fig. 2** - A. Schematic view of the reconstruction. Large arrow is pointing out the epiploon surrounding the tracheostoma and the esophagus. Thin arrow is on the skin graft covering the posterior side of the trachea. Head of arrow shows de microvascular anastomosis and finally de asterisk is into the stomach patch that makes up the anterior esophagus. B. Gastro-omental flap with its omentum portion below and the shaping of the stomach patch. C. At the tracheostoma level, the posterior wall of the trachea is formed by a skin graft. The omentum which will be placed around the tracheostoma and behind the skin graft will nourish it. D. The cervical trachea was moved and the new tracheal stoma was placed just 2 cm below it was before. Surrounding it the omentum covered by skin grafts. E. Vascular anastomosis under microscope between the right gastroepiploic vessels and the mammary internal ones at the third intercostal space. The white spot is on the arterial anastomosis and the black spot on the venous anastomosis.

tracheoesophageal communication was achieved but the silicone button was also lost twice over the next few years.

The tracheoesophageal fistula presented by this patient eight years after the primary surgery was about  $5 \times 2$  cm, extending from the level of the tracheostoma to below it, affecting the substomatic trachea as well (Fig. 1A and B). Due to the large size of the fistula the exchange of the silicone button was impossible and it couldn't be closed either with rigid bronchoscopy or esophagoscopy. Surgical correction with the interposition of a pectoral flap between the trachea and the esophagus was unsuccessfully attempted since the fistula rapidly recurred over few weeks.

Finally a gastro-omental flap was performed to try to solve the problem. Surgery was carried out by a multidisciplinary team integrated by otorhinolaryngologists, thoracic and plastics surgeons.

Patient obesity made it difficult to achieve good visualization of the fistula with a cervical approach so a partial upper sternotomy with unilateral J-shaped extension to the right through the third intercostal space was performed. Afterwards, the trachea was detached from the esophagus and the anterior wall of the esophagus and the posterior aspect of the trachea were debrided (Fig. 1C).

Meanwhile a second team raised the gastro-omental flap, a composite flap which includes a portion of the greater curvature of the stomach, which was harvested in an elliptic shape just a bit larger than the esophagus, and greater omentum pediculated on the right gastroepiploic vessels (Fig. 2B).

The inset procedure of the flap into the neck was carried out before performing the vessels anastomosis. The stomach patch was fashioned to rebuild the anterior esophagus wall and the omentum was placed around the tracheostoma and between the trachea and the esophagus. In order to avoid a lower mediastinal tracheostomy with high risk of further complications due to compression of the great vessels, tracheal length was preserved. We achieved it by conserving all cartilaginous rings and only debriding the posterior membranous trachea which was in contact with the esophagus. Then a split-thickness skin graft from the thigh was used to resurface the posterior wall of the trachea on the tracheostoma level as well as to prevent the airway obstruction by the omentum. Its epidermal side was stitched to the posterior edges of the trachea and its dermal face was in contact with the surrounding omentum so that it could nourish it (Fig. 2C). Finally a microsurgery anastomosis between the internal mammary vessels and the gastroepiploic ones was performed without vein graft requirement. The omentum placed around the tracheostoma was covered by skin grafts and the sternotomy was left open to avoid the compression of the flap (Fig. 2D and E).

During the first three days of the postoperative period a nasogastric tube was used for stomach aspiration to protect the stomach suture. Afterwards on the fourth postoperative day it was used for patient feeding. Post-operative evaluation with radiologic barium swallow test ten days after surgery and with computerized scanner visualization evidenced the patency of the digestive tract and the absence of fistula. Patient discharge occurred 25 days after surgery and the nasogastric tube was removed when oral intake was well tolerated on the 45th postoperative day. Over the next sixteen months of follow-up the

omentum atrophied significantly improving neck appearance and the patient continued tolerating oral diet without need to endoscopic balloon dilatation.

The initial management of TEF usually involves a combination of various conservative measures such as changes in the size of the prosthesis, temporary prosthesis withdrawal, TEP site injection, suture placement around the puncture or the placement of silicone button prostheses in order to close the fistula.<sup>3</sup>

However, in patients with a high risk of wound breakdown, toxicity by radiotherapy, high levels of contamination at the local site and with previous flaps failed, as well as in obese patients in whom breathing and coughing may increase instability, we believe that the insertion of a gastro-omental free flap is a good alternative.<sup>4-7</sup>

The gastric mucosa can be easily customized to the defect without adding significant weight (this is the main disadvantage of muscle flaps, which present excessive bulking). Furthermore, the long omental pedicle allows the creation of the anastomosis to the extra cervical vessels outside the contaminated and radiated area. The omentum can fill all dead spaces and also provides highly vascular tissue rich in growth factors and progenitor cells which help the injured tissue to heal and also protect the anastomosis of the defect and exposed vessels. Although there is some concern about the peptic ulceration of the recipient site, mucus production from the transferred stomach mucosa and atrophy of the denervated gastric glands makes this complication fairly rare. In addition, intensive therapy with proton-pump inhibitors is used for the first three months before atrophy of gland occurs. Besides, the greater antrum, which is the portion of stomach harvested, is sparsely populated by gastric parietal cells.<sup>8-10</sup>

## REFERENCES

- Hutcheson KA, Lewin JS, Sturgis EM, Kapadia A, Risser J. Enlarged tracheoesophageal puncture after total laryngectomy: a systematic review and meta-analysis. *Head Neck*. 2011;33:20-30.
- Andrews JC, Mickel RA, Hanson DG, Monahan GP, Ward PH. Major complications following tracheoesophageal puncture for voice rehabilitation. *Laryngoscope*. 1987;97:562-7.
- Mirza S, Head M, Robson AK. Silicone septal button in the management of a large tracheo-oesophageal fistula following primary puncture in a laryngectomee. *ORL J Otorhinolaryngol Relat Spec*. 2003;65:129-30.
- Yu P. One-stage reconstruction of complex pharyngoesophageal, tracheal, and anterior neck defects. *Plast Reconstr Surg*. 2005;116:949-56.
- Gehrking E, Raap M, Sommer KD. Classification and management of tracheoesophageal and tracheopharyngeal fistulas after laryngectomy. *Laryngoscope*. 2007;117:1943-51.
- Dewey EH, Castro JR, Mojica J, Lazarus CL, Su HK, Alpert EH, et al. Reconstruction of expanding tracheoesophageal fistulae in post-radiation therapy patients who undergo total laryngectomy with a bipaddled radial forearm free flap: Report of 8 cases. *Head Neck*. 2016;38 Suppl 1:E172-8.
- Weber RS, Berkey BA, Forastiere A, Cooper J, Maor M, Goepfert H, et al. Outcome of salvage total laryngectomy following organ preservation therapy: The Radiation Therapy Oncology Group trial 91-11. *Arch Otolaryngol Head Neck Surg*. 2003;129:44-9.

8. Viñals JM, Rodrigues TA, Lopez CC, Payro JM, Porté JA, Sildenafil DP, et al. Outcomes of gastro-omental free flap reconstruction for salvage laryngopharyngectomy for pharyngeal and laryngeal cancer after concurrent chemoradiotherapy. *Ann Plast Surg.* 2014 [Epub ahead of print].
9. Patel RS, Gilbert RW. Utility of the gastro-omental free flap in head and neck reconstruction. *Curr Opin Otolaryngol Head Neck Surg.* 2009;17:258-62.
10. Vernik J, Singh AK. Omentum: Power to heal and regenerate. *Int J Artif Organs.* 2007;30:95-9.

Juan Maria Viñals Viñals<sup>Q1</sup><sup>a</sup>, Pau Tarrús Bozal<sup>a,\*</sup>,  
Jose Maria Serra-Mestre<sup>b</sup>, Oriol Bermejo Segú<sup>a</sup>,  
Julio Nogués Orpí<sup>c</sup>

<sup>a</sup>Departamento de Cirugía Plástica y Reconstructiva, Hospital Universitario de Bellvitge, L'Hospitalet de Llobregat, Barcelona, Spain

<sup>b</sup>Plastic and Reconstructive Surgery Department, Second University of Naples, Naples, Italy

<sup>c</sup>Departamento de Otorrinolaringología, Hospital Universitario de Bellvitge, L'Hospitalet de Llobregat, Barcelona, Spain

\*Corresponding author.

E-mail address: [pau.tarrus@bellvitgehospital.cat](mailto:pau.tarrus@bellvitgehospital.cat)  
(P. Tarrús Bozal).

2173-5077/

© 2017 AEC. Published by Elsevier España, S.L.U. All rights reserved.

## “Iliac Hernia”, an Original Form of Ventral Hernia That Is Probably not so Uncommon<sup>☆</sup>



### «Hernia transilíaca». Una original modalidad de eventración probablemente no tan infrecuente

The iliac wing is frequently used as a donor area for autogenous bone tissue for grafts in orthopedic surgery due to the quality and quantity of bone available and its easy accessibility. Herniation of the intra-abdominal viscera through the created bone defect is a potentially serious complication.

We present the case of a 76-year-old patient with metabolic syndrome (body mass index 36), who had been treated for bilateral coxarthrosis secondary to congenital dislocation of the left hip using a Müller-type bilateral prostheses at the age of 36. The patient required replacement of the left prosthetic socket due to de-cementation and replacement of the left prosthesis with autogenous bone graft of the iliac wing in the acetabular fundus at the ages of 48 and 53, respectively. The patient reported episodes of colic abdominal pain for several months, and physical examination revealed an irreducible swollen mass in the left gluteal region. Abdominal computed tomography showed a transiliac hernia and an umbilical hernia (Figs. 1 and 2). The surgical intervention consisted of: subumbilical midline laparotomy; incision of the left parietal peritoneum to mobilize and introduce into the abdominal cavity the segments of the descending and sigmoid colon that were herniated and incarcerated; access to the retroperitoneal space and implantation of a 20×20 cm polypropylene mesh, extended in retroperitoneal position to widely cover the hernia orifice and the adjacent musculoskeletal structures, without being in contact with the visceral peritoneum; the mesh was

affixed with several cardinal non-absorbable stitches and maintained in its correct position by the intra-abdominal pressure itself. The laparotomy was closed with a double continuous suture of slowly absorbable material and repair of the umbilical hernia. There were no postoperative complications. After one year of follow-up, physical examination has shown no hernia recurrence.

Obtaining autogenous bone graft from the wing of the ilium has a morbidity rate between 12% and 20%, which is even higher if the donor area is the anterior part of the iliac crest and not the posterior (23% vs 2%, respectively). Among the various postoperative complications,<sup>1</sup> the most important is “iliac hernia”, which is a term used in the literature to describe this condition, although it is occasionally classified as a lumbar hernia. This condition, described by Oldfield in 1945, is a poorly documented entity that is probably underestimated because fewer than 40 cases have been reported since its first publication<sup>2,3</sup>; however, its incidence is estimated from 5% to 9%.<sup>1,4</sup>

Its etiopathogenesis is a consequence of the surgical defect in the coxal bone, almost always related with having obtained a bone graft or, less frequently, after fractures,<sup>5</sup> debridement due to osteomyelitis, and on rare occasion due to a congenital bone defect.

Its appearance has been reported between the first days following the operation and up to 15 years after the bone

<sup>☆</sup> Please cite this article as: Martínez Rodenas F, Torres Soberano G, Hernández Borlan R, Moreno Solórzano JE, Llopart López JR. «Hernia transilíaca». Una original modalidad de eventración probablemente no tan infrecuente. *Cir Esp.* 2017;95:618-620.