



Image of the month

Alveolar Echinococcus, a Rare Cause of Liver Transplantation[☆]



Equinococosis alveolar: una causa infrecuente de trasplante hepático

Recep Sade, Gokhan Polat,* Hayri Oğul, Mecit Kantarci

Department of Radiology, Medical Faculty, Ataturk University, Erzurum, Turkey

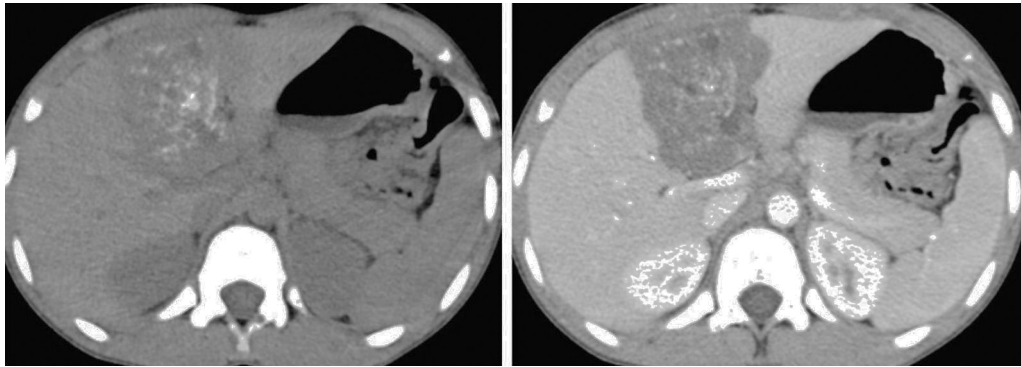


Fig. 1

A 14-year-old child came to our pediatric clinic complaining of intermittent abdominal pain. Liver function tests showed deterioration. Multidetector computed tomography was performed, which revealed a non-enhanced solid mass. Computed tomography discovered calcifications in the mass (Fig. 1). With a pathology specimen, the mass was diagnosed as alveolar echinococcosis. The patient is currently awaiting liver transplantation.

Echinococcosis is an endemic parasitic disease, but it has begun to be seen in Europe. Symptoms may occur too late, and liver involvement can lead to liver failure. It is a particularly rare cause of liver transplantation in children.

[☆] Please cite this article as: Sade R, Polat G, Oğul H, Kantarci M. Equinococosis alveolar: una causa infrecuente de trasplante hepático. Cir Esp. 2017;95:404.

* Corresponding author.

E-mail address: dr.g.polat@gmail.com (G. Polat).