



Scientific letters

Chronic Recurrent Abdominal Pain as a Result of Arcuate Ligament Syndrome[☆]



Dolor abdominal crónico recurrente, a consecuencia del síndrome del ligamento arcuato medio

In spite of the technological advances in endovascular treatments, median arcuate ligament syndrome (MALS) requires a surgical approach to eliminate the abnormal anatomical structures that cause extrinsic compression to the coeliac artery (CA). If the endovascular treatment is not accompanied by adequate release of the compressive muscular and ligament structures, the symptoms usually recur early on. We present the case of a male patient with this syndrome who presented occlusion of the CA after simple angioplasty requiring decompression surgery and aortocoeliac bypass, which provided satisfactory results (Figs. 1 and 2).

The patient is a 27-year-old man, a carpenter by profession, with a history of intense tobacco habit and type I diabetes mellitus, with poor metabolic control. Over the previous 3 years, he had experienced postprandial epigastric pain and vomiting, leading to a weight loss of 50 kg, with no definitive diagnosis. Finally, a study done by the Digestive Tract Department at another hospital provided the diagnosis of MALS. Doppler ultrasound showed turbulent flows with a peak systolic velocity of 440 cm/s in the CA. In addition, gadolinium-enhanced magnetic resonance angiography of the visceral aorta confirmed stenosis of the CA of more than 70%.

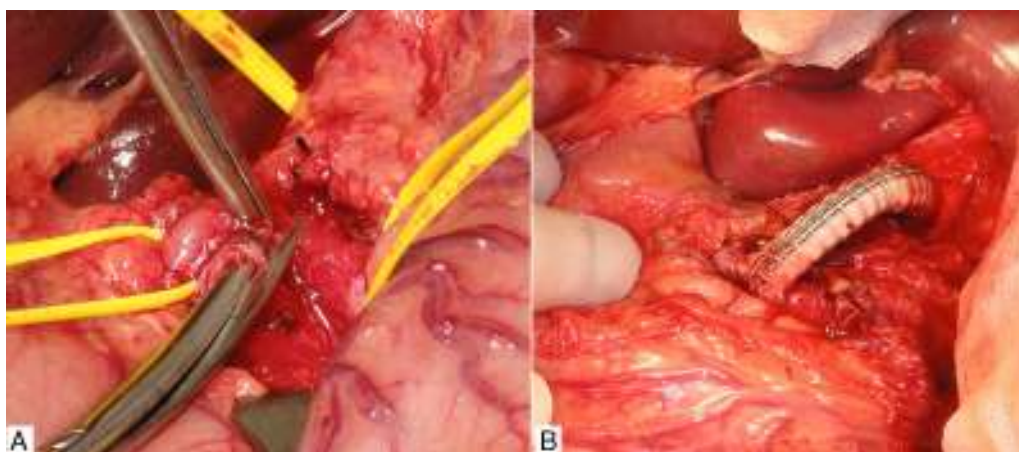


Fig. 1 – (A) Division of the median arcuate ligament; and (B) stent bypass from the supracoeliac aorta up to the trifurcation of the coeliac trunk.

[☆] Please cite this article as: Novo Martínez GM, Rodríguez Morata A, Alonso Argüeso G, Reyes Ortega JP, Gómez Medialdea R. Dolor abdominal crónico recurrente, a consecuencia del síndrome del ligamento arcuato medio. Cir Esp. 2016;94:301-303.

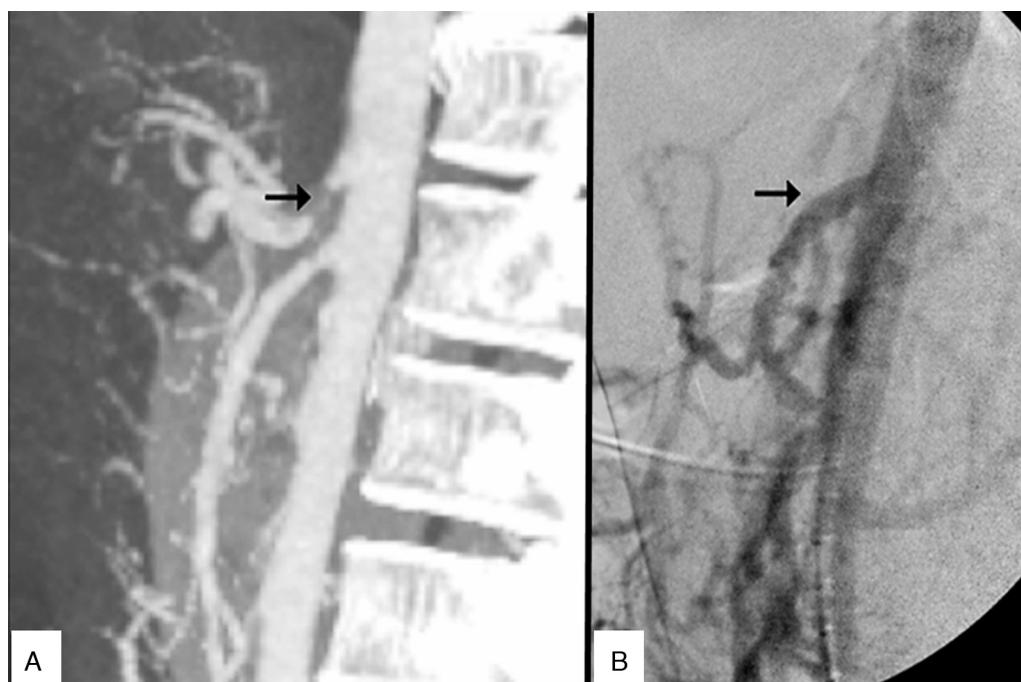


Fig. 2 – (A) Early-onset occlusion of the coeliac trunk after simple percutaneous angioplasty; and (B) optimal intraoperative arteriography study of the stent bypass from the supracoeliac aorta up to the trifurcation of the coeliac artery.

In the interventional radiology unit at that same hospital, the patient underwent percutaneous transluminal angioplasty of the CA with a balloon catheter measuring 5 mm in diameter by 20 mm in length, which provided good immediate results and resolution of the symptoms. Nonetheless, the patient quickly presented the same symptoms once again.

Given the unfavourable progress, with frequent visits to the emergency department for intravenous medication for pain control, the patient was referred to the Angiology and Vascular Surgery Department at our hospital. Upon examination, the patient was moderately thin, pulses were symmetric, ankle-brachial indices were normal, and no abdominal bruit was detected. Doppler ultrasound and CT angiography confirmed CA occlusion.

We decided to schedule open surgery, which involved supraumbilical abdominal midline incision and periaortic decompression by means of adhesiolysis of the CA and its 3 branches. In addition, we divided the surrounding crura of the diaphragm and a multitude of neighbouring fibrous adhesions.

Prior to the surgical approach of the CA, intraoperative arteriography demonstrated the obstruction. The revascularisation consisted of an antegrade bypass from the supracoeliac aorta up to the origin of the CA branches with a 7 mm Dacron[®] gelatine-impregnated stent (Grupo Cardiva). After creating the bypass, the intraoperative arteriogram was satisfactory.

The patient was discharged on the third day with no further incidents, and he continued to be asymptomatic at the successive follow-up visits.

The median arcuate ligament connects the crura of the diaphragm to both sides of the aortic hiatus and is situated above the CA.¹ An abnormally low insertion of the diaphragm and/or an excessively high origin of the CA can cause median arcuate ligament syndrome. It is more prevalent in women,

and its incidence is around 2 out of every 100,000 patients with recurring abdominal pain.²

Radiological studies show that some 50% of asymptomatic persons can have varying degrees of extrinsic pressure on the CA during forced expiration, but this does not mean that they should be diagnosed with MALS. In patients with this syndrome, compression is exerted both during inspiration as well as expiration.³

Chronic compression of the CA causes symptoms that vary greatly. The most common is the existence of chronic abdominal pain and weight loss due to chronic intestinal ischaemia. The most uncommon is the development of splanchnic artery aneurysm with possible rupture.^{4,5} There have also been rare reports of retrosternal pain associated with physical exercise.⁶

The treatment of choice for MALS involves surgical decompression, which can be open or laparoscopic,⁷ to eliminate the fibres that encompass or compress the CA. If there are associated intrinsic lesions of the CA with stenosis or obstruction, it is necessary to associate endovascular treatment using stents or aortocoeliac bypass. Endovascular therapy, without associated surgical decompression, is not recommended due to the high risk for early restenosis, similar to other extrinsic arterial compressions.²

It is important to consider MALS as a possible diagnosis in patients with chronic recurring abdominal pain and vomiting, especially in young patients and when other diseases have been excluded.⁸ If arteriography of the abdominal aorta were necessary for confirmation in the diagnostic phase, we must avoid the temptation to perform balloon angioplasty on the stenotic lesion since, without associated surgical decompression, early recurrence is very likely and symptoms may even become worse.

REFERENCES

- San Norberto EM, Montes JM, Romero A, Núñez E, Vaquero C. Síndrome del ligamento arcuato medio: a propósito de tres casos y revisión de la literatura. *Angiología*. 2012;64:167-72.
- Grotemeyer D, Duran M, Iskandar F, Blondin D, Nguyen K, Sandmann W. Median arcuate ligament syndrome: vascular surgical therapy and follow-up of 18 patients. *Langenbecks Arch Surg*. 2009;394:1085-92.
- Horton KM, Talamini MA, Fishman EK. Median arcuate ligament syndrome: evaluation with CT angiography. *Radiographics*. 2005;25:1177-82.
- Matsumura Y, Nakada TA, Kobe Y, Hattori N, Oda S. Median arcuate ligament syndrome presenting as hemorrhagic shock. *Am J Emerg Med*. 2013;31:1152-4.
- Storm J, Kerr E, Kennedy P. Rare complications of a low lying median arcuate coeliac ligament. *Ulster Med J*. 2015;84:107-9.
- Karavelioğlu Y, Kalçık M, Sarak T. Dunbar syndrome as an unusual cause of exercise-induced retrosternal pain. *Türk Kardiyol Dern Ars*. 2015;43:465-7.
- Berard X, Cau J, Déglise S, Trombert D, Saint-Lebes B, Midy D, et al. Laparoscopic surgery for coeliac artery compression syndrome: current management and technical aspects. *Eur J Vasc Endovasc Surg*. 2012;43:38-42.
- Hill E, Sultan M, Chalhoub W, Jackson P, Mattar M. Median arcuate ligament syndrome: a cause of postprandial abdominal pain in a patient with ulcerative colitis. *J Med Cases*. 2014;5:344-6.

Gloria María Novo Martínez^{a*}, Alejandro Rodríguez Morata^b, Gonzalo Alonso Argüeso^b, Juan Pedro Reyes Ortega^b, Rafael Gómez Medialdea^b

^aHospital Universitario de León, León, Spain

^bHospital Clínico Universitario Virgen de la Victoria, Málaga, Spain

*Corresponding author.

E-mail address: glori_mry@hotmail.com (G.M. Novo Martínez).

2173-5077/

© 2016 Published by Elsevier España, S.L.U. on behalf of AEC.

Treatment of Presacral Bleeding After Colorectal Surgery With Bakri Balloon[☆]



Tratamiento de la hemorragia presacra tras cirugía colorrectal mediante el uso del balón de Bakri

Presacral bleeding (PB) is a non-pulsatile haemorrhage due to the disruption of the presacral venous plexus (PVP). These haemorrhages are difficult to manage and are sometimes non-controllable with conventional surgical manoeuvres.¹ The use of tamponade balloons is suggested as a feasible and effective option.

The Bakri balloon is a silicone balloon designed for the treatment of uterine bleeding in postpartum haemorrhage² (Fig. 1). In our series, the balloons were inserted vaginally, in perineal wounds after rectal resection or anally through the open rectal stump and filled with sterile saline solution (maximum capacity 500 mL).

The first patient underwent surgery for disease recurrence in the rectovaginal septum after resection for sigmoid adenocarcinoma. The operation involved hysterectomy and bilateral adnexectomy, resection of the posterior vaginal wall and resection of the rectum with a colorectal mechanical anastomosis and loop ileostomy. On the 5th day post-op, the patient was re-operated on due to anastomotic leak and the remaining colonic segment was resected up to the efferent

loop of the ileostomy, presenting PB that required packing. Seven days after this reoperation, the packing material was removed but, 7 days later, the patient once again underwent surgery for suspicion of another PVP haemorrhage. The approach was vaginal, and 3 balloons were inserted vaginally.

The second patient was treated surgically for disease recurrence in the right hemipelvis after abdominoperineal resection due to rectal adenocarcinoma. Surgery involved midline laparotomy with tumour resection. During surgery, PB began that was not controllable by electrocoagulation, suture or haemostatic biological materials, so a balloon was inserted through the perineum.

The third patient, with a history of subtotal colectomy due to familial adenomatous polyposis and an ileal pouch done at another hospital (without proctectomy), presented a tubular adenoma with high-grade dysplasia in the rectal stump 5 years later. Surgery involved midline laparotomy with division of the ileum above the pouch plus resection of the rectum up to the pectinate line and associated ileostomy in the RIF. During the postoperative period, the patient

[☆] Please cite this article as: Lopez-Lopez V, Abrisqueta J, Lujan J, Ferreras D, Parrilla P. Tratamiento de la hemorragia presacra tras cirugía colorrectal mediante el uso del balón de Bakri. *Cir Esp*. 2016;94:303-305.