



Image of the month

Giant Incisional Hernia Containing the Stomach and Bowel Loops[☆]



Hernia incisional gigante que contiene estómago y asas intestinales

Alberto García García,^{*} María Teresa Espín Jaime, José Ángel Flores García, Jesús Salas Martínez

Servicio de Cirugía General, Hospital Infanta Cristina, Badajoz, Spain

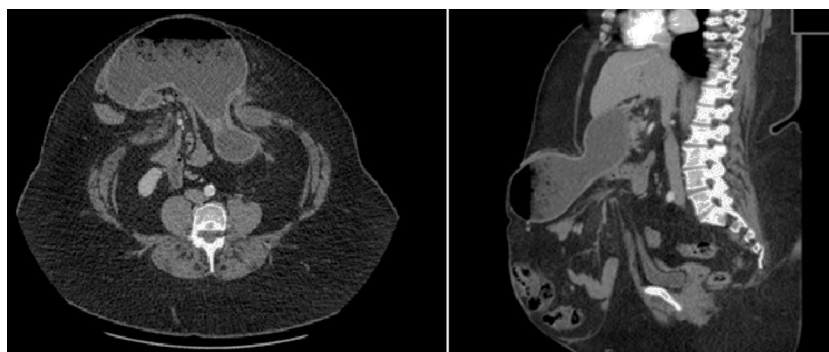


Fig. 1

The patient is a 54-year-old woman with a history of obesity (BMI=50.40). In 2012, she underwent surgery for incarcerated umbilical hernia, which did not require intestinal resection.

She currently presented a midline laparotomy incisional hernia, which had caused several hospitalizations due to intestinal obstruction that had resolved with conservative measures. Abdominal CT revealed a giant incisional hernia containing the gastric body, antrum and small bowel loops, with no signs of complications (Fig. 1).

The patient underwent scheduled surgery to treat the morbid obesity and incisional hernia. Gastric bypass was performed with a Proceed[®] 30×30 cm mesh placement on the abdominal wall.

The postoperative period was uneventful, and the patient was discharged 7 days after surgery.

Diagnosis

Giant incisional hernia involving the gastric body, antrum and small bowel loops, with no signs of complications.

[☆] Please cite this article as: García García A, Espín Jaime MT, Flores García JÁ, Salas Martínez J. Hernia incisional gigante que contiene estómago y asas intestinales. Cir Esp. 2015;93:e25.

^{*} Corresponding author.

E-mail address: Alberto.garciahn@gmail.com (A. García García).