

CIRUGÍA ESPAÑOLA

www.elsevier.es/cirugia


Scientific letters

Transcatheter Arterial Embolization in the Management of Acute Bleeding From Advanced Gastric Cancer[☆]



Embolización arterial percutánea en el tratamiento de la hemorragia digestiva secundaria a cáncer gástrico avanzado

More than 10% of patients with unresectable gastric adenocarcinoma present gastrointestinal bleeding either at the time of diagnosis or afterwards.^{1,2} The resulting symptoms are variable, from progressive anemia due to evident or hidden chronic hemorrhage to hemodynamic shock.¹ In any case, the morbidity of these hemorrhages notably worsens the patient's quality of life. Endoscopic techniques have been seen to be effective for the control of bleeding secondary to gastric cancer and are the first line of treatment. Nonetheless, the incidence of recurrent bleeding reaches 29%–80%, and in many cases there are lesions that are not susceptible to endoscopic control, such as extensive mucous membrane lesions with capillary bleeding, deep ulcers with vessels larger than 2 mm, very vascularized tumors with arterial infiltration or lesions that are not accessible endoscopically.^{2,3} Traditionally, surgery has been the treatment of choice in these cases as it improves the efficacy to control bleeding, although it involves elevated morbidity and mortality.^{2,4–6} Interventional radiology can be an effective alternative for patients with recurring or persistent hemorrhage after endoscopy.^{2,3,7}

We present the case of a 64-year-old woman diagnosed in April 2012 with locally-advanced gastric adenocarcinoma (body-fundus) cT3N2M0. Neoadjuvant chemotherapy was decided upon. On May 12th, she came to the Emergency Department due to upper gastrointestinal bleeding (UGIB) in the form of melenas, with hemodynamic instability and severe anemia seen on lab work (Hb: 5.9 g/dl). Gastroscopy showed evidence of a mamelonated, friable mass that extended from the cardias along the lesser curvature until the incisura, with capillary bleeding (Fig. 1) that was treated

with adrenalin (1:10 000) and argon fulguration, but hemostasis was not achieved. We decided to perform arterial embolization (Fig. 2) using the selective catheterization of the left gastric artery with particles from 700–900 μ and SpongostanTM. Good results were seen on the follow-up angiography. After having controlled the hemorrhage, the patient initiated chemotherapy in accordance with the XELOX model. On the follow-up computed tomography done in July 2012, a marked decrease was observed in the wall thickness of the lesser curvature of the stomach in the area of the body and antrum, and the lymphadenopathies had also reduced in size. Nonetheless, multiple new bone metastases were found. The patient died in December 2012 due to disease progression.

Arterial embolization is a safe, effective alternative in these cases of persistent or recurrent hemorrhage, especially in critical patients or those with high risk for surgery. It is a less aggressive technique with fewer complications, and its main advantage is the avoidance of emergency surgery in these patients,^{4,8} which reaches very high rates of morbidity and mortality.⁹ In addition, most patients with hemorrhage secondary to gastric cancer are found in advanced stages of the disease, so any type of surgical treatment is usually palliative. Prognosis is poor, with a mean survival of less than a year. The control of active bleeding can improve the clinical course and immediate survival, although the prognosis is determined by tumor stage and progression.²

Even though there are several studies in favor of the use of arterial embolization to control bleeding in peptic ulcers and postoperative pseudoaneurysms with rates of technical and clinical efficacy that range from 69% to 100%

[☆] Please cite this article as: Romera Barba E, Castañer Ramón-Llín J, Sánchez Pérez A, García Marcilla JA, Vázquez Rojas JL. Embolización arterial percutánea en el tratamiento de la hemorragia digestiva secundaria a cáncer gástrico avanzado. Cir Esp. 2014;92:492–494.

^{☆☆} Presented as an informational poster at the 23rd National Meeting of ISDE, San Sebastián (Spain) from May 2–3, 2013.

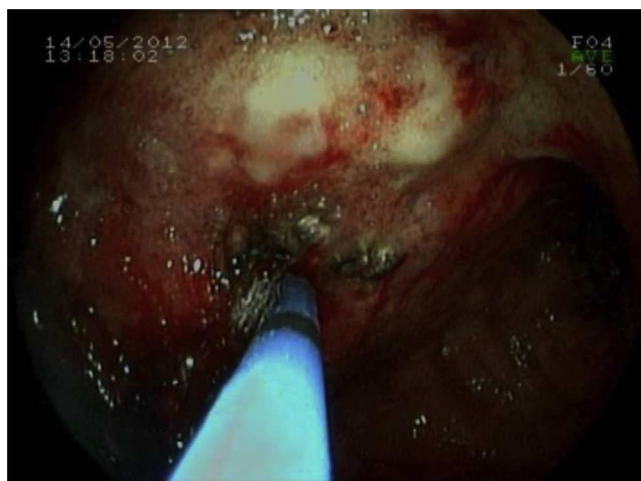


Fig. 1 – Endoscopy: mamelonated mass with diffuse hemorrhage; fulguration with argon.

and 63% to 97%, respectively, few include gastric cancer and are usually small series.^{2,4-6,8}

The clinical efficacy of embolization for controlling bleeding secondary to gastric cancer ranges between 43% and 75%.² It is greater in those cases that demonstrate the presence of contrast extravasation on arteriography, followed by those that show uptake of the tumor. Since the hemorrhage is often diffuse or intermittent, it is not rare for the arteriography to be negative in spite of there being active hemorrhage seen on endoscopy. In this context, Lee et al.² and Shin et al.⁷ propose that “blind” embolization in these cases, guided by the endoscopic information about the possible origin of the hemorrhage, could be equally beneficial.

Although embolization is considered a safe technique above the ligament of Treitz due to the rich collateral

circulation of the stomach and duodenum, the main risk is ischemia and necrosis. There have been case reports of acute ischemia post-embolization. The majority, however, are late-onset and present as duodenal stenosis due to embolization of the gastroduodenal artery,^{5,6} with a higher risk in patients with a history of radiotherapy or previous gastric surgery.⁷

Recent studies based on small series have also demonstrated the benefit of radiotherapy as treatment for bleeding in gastric cancer, although there are no studies comparing its efficacy with endoscopic techniques and embolization. Therapy regimes have been used with dose fractions from 30 Gy in 10 sessions to 54 Gy in 30 sessions, achieving control of the hemorrhage in 55%–75% of the patients who complete the treatment.¹⁰ The duration of the hemostatic effect can be approximately 11–12 months and is even greater than that achieved with endoscopic techniques in cases of diffuse hemorrhage. Nonetheless, radiotherapy has limitations in the control of serious acute bleeding (accompanied by hemodynamic instability), given the need for urgent treatment. On the other hand, it can potentially cause gastritis, ulcer and hypochlorhydria (if a significant volume of parietal cells are irradiated). In addition, these consequences can exacerbate nausea, vomiting, dyspepsia, pain and can induce hemorrhage that is not related with the tumor. In this manner, radiotherapy has its role mainly in cases of chronic hemorrhage, where it has been shown to reduce the need for transfusions and improve the quality of life of these patients.

In conclusion, in patients with bleeding gastric cancer that is either unresectable or involves high surgical risk, transcatheter arterial embolization can be a safe and effective technique to control bleeding. Prospective studies are necessary to establish its routine use as an alternative to surgery in the management of these patients when endoscopic techniques have failed.

REFERENCES

1. Pereira J, Phan T. Management of bleeding in patients with advanced cancer. *Oncologist*. 2004;9:561–70.
2. Lee HJ, Shin JH, Yoon HK, Ko GY, Gwon DI, Song HY, et al. Transcatheter arterial embolization in gastric cancer patients with acute bleeding. *Eur Radiol*. 2009;19:960–5.
3. Koh KH, Kim K, Kwon DH, Chung BS, Sohn JY, Ahn DS, et al. The successful endoscopic hemostasis factors in bleeding from advanced gastric cancer. *Gastric Cancer*. 2013;16:397–403.
4. Wong TC, Wong KT, Chiu PW, Teoh AY, Yu SC, Au KW, et al. A comparison of angiographic embolization with surgery after failed endoscopic hemostasis to bleeding peptic ulcers. *Gastrointest Endosc*. 2011;73:900–8.
5. Jairath V, Kahan BC, Logan RF, Hearnshaw SA, Dore CJ, Travis SP, et al. National audit of the use of surgery and radiological embolization after failed endoscopic haemostasis for non-variceal upper gastrointestinal bleeding. *Br J Surg*. 2012;99:1672–80.
6. Loffroy R, Estivalet L, Cherblanc V, Sottier D, Guiu B, Cercueil JP, et al. Transcatheter embolization as the new reference standard for endoscopically unmanageable upper gastrointestinal bleeding. *World J Gastrointest Surg*. 2012;4:223–7.

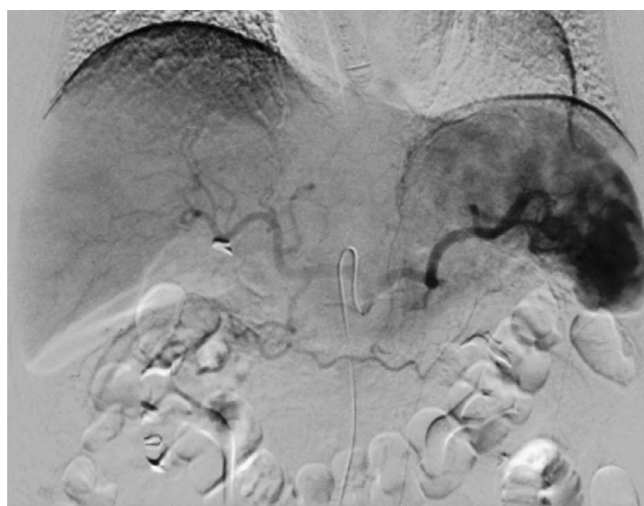

Fig. 2 – Selective arteriographies from the left gastric and celiac trunk; the left gastric artery is selectively catheterized, verifying the selective uptake of the tumor, covering the entire lesser curvature.

7. Shin JH. Recent update of embolization of upper gastrointestinal tract bleeding. *Korean J Radiol.* 2012;13 Suppl. 1:31-9.
8. Ang D, Teo EK, Tan A, Ibrahim S, Tan PS, Ang TL, et al. A comparison of surgery versus transcatheter angio-graphic embolization in the treatment of nonvariceal upper gastrointestinal bleeding uncontrolled by endoscopy. *Eur J Gastroenterol Hepatol.* 2012;24:929-38.
9. So JB, Yam A, Cheah WK, Kum CK, Goh PM. Risk factors related to operative mortality and morbidity in patients undergoing emergency gastrectomy. *Br J Surg.* 2000;87:1702-7.
10. Asakura H, Hashimoto T, Harada H, Mizumoto M, Furutani K, Hasuike N, et al. Palliative radiotherapy for bleeding from advanced gastric cancer: is a schedule of 30 Gy in 10 fractions adequate? *J Cancer Res Clin Oncol.* 2011;137:125-30.

Elena Romera Barba*, Juan Castañer Ramón-Llín, Ainhoa Sánchez Pérez, José Antonio García Marcilla, José Luis Vázquez Rojas

Servicio de Cirugía General y del Aparato Digestivo, Hospital General Universitario Santa Lucía, Cartagena, Spain

*Corresponding author.

E-mail address: percentila@hotmail.com (E. Romera Barba).

2173-5077/\$ – see front matter

© 2013 AEC. Published by Elsevier España, S.L.U. All rights reserved.

Cervical Esophageal Hemangioma[☆]



Hemangioma de esófago cervical

Hemangiomas are benign vascular tumors that usually derive from organs such as the skin, liver or kidneys and are usually diagnosed in childhood. Histologically, there are 3 types: cavernous, hamartomatous and arteriovenous malformations. The esophageal location of hemangiomas is uncommon, representing 3% of all benign tumors of this organ; they are usually single lesions situated in the lower third of the esophagus. Esophageal hemangiomas may cause obstructive and/or hemorrhagic symptoms: dysphagia, dyspnea, hypersalivation, episodes of aspiration, recurring respiratory infection, hematemesis and melenas. Diagnosis in adults of a hemangioma in the hypopharynx or the cervical esophagus is a clinical rarity, and only a few isolated cases have been published in the medical literature.¹ We present the clinical case of a cervical esophageal hemangioma diagnosed in an adult.

The patient was a 68-year-old woman with no medical history of interest. During computed tomography (CT) study for chronic cough (Fig. 1) a lesion measuring 2.6 cm × 2.1 cm × 3.3 cm was detected in the proximal third of the esophagus, which obstructed almost the entire lumen and protruded over the posterior wall of the trachea. After the administration of intravenous contrast, there was mild homogeneous uptake, giving the mass a solid appearance. These findings were not considered conclusive for diagnosis. Endoscopic ultrasound (EUS), after passing Killian's area, showed a subepithelial lesion in the right lateral-cervical region that was completely passable and measured 26 mm × 17 mm, which seemed dependent upon the muscular tissue itself. It was rather heterogeneous and presented hypo- and hyperechoic images. The differential diagnosis included leiomyoma and

gastrointestinal stromal tumor (GIST). Therefore, a positron emission tomography-CT (PET-CT) was performed, which detected no fluorodeoxyglucose (FDG) uptake in the mass.

With the findings from the EUS and PET-CT, the probable diagnosis of leiomyoma was established. Although the patient reported no digestive symptoms, we decided to operate because of the uncertain exact nature of the lesion and its possible subsequent evolution. We used a left lateral cervical approach, which is the usual approach to the cervical esophagus in our department, and the mass was identified in the esophageal wall. After longitudinal myotomy, the lesion was observed to be benign in appearance, lobulated, dark blue in color and soft in consistency, which are characteristics compatible with hemangioma. We decided to perform an enucleation of the mass. It was closely adhered to the mucous membrane, which we opened in order to complete the separation from the mucosa without rupturing the tumor.

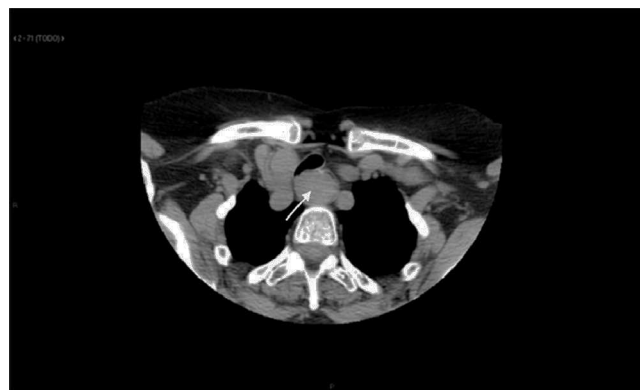


Fig. 1 – Cervicothoracic computed tomography: lesion in the cervical esophagus that practically closes the esophageal lumen.

[☆] Please cite this article as: Alvarez Martín MJ, García Navarro A, Díez Vigil JL, Becerra Massare P, Ferrón Orihuela A. Hemangioma de esófago cervical. *Cir Esp.* 2014;92:494-495.