

Image of the month

Sudden onset of abdominal mass[☆]

Masa abdominal de aparición súbita

Emma Espinar, Andrea Soria, Jaime Jimeno Fraile, David Parés^{*}

Servicio de Cirugía General y Digestiva, Parc Sanitari Sant Joan de Déu, Universitat de Barcelona, Sant Boi de Llobregat, Barcelona, Spain

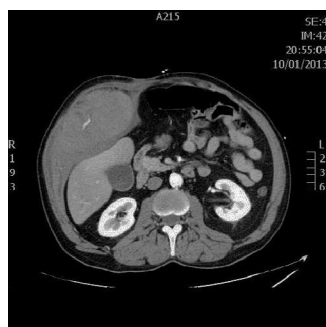


Fig. 1

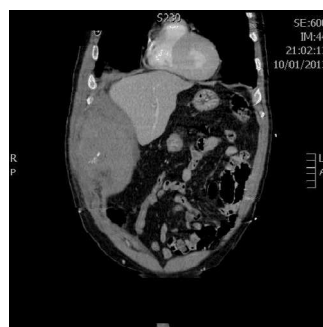

Fig. 2

The patient was a 58-year-old man with a tobacco habit of 20 cigarettes/day, ischemic cardiomyopathy and chronic obstructive pulmonary disease. He came to the Emergency Department due to the sudden appearance of a mass in the right abdomen after a fit of coughing. He was admitted with BP 125/75 mmHg and 102 bpm, and we observed a large mass in the right flank and hypochondrium during physical examination. The lab work showed hemoglobin 13.3 mg/dL and hematocrit 37.29%. A simple abdominal radiograph showed no alterations. Meanwhile, computed tomography of the abdomen with intravenous contrast revealed a large hematoma of the right rectus abdominis muscle sheath measuring 20 cm×14cm×70 cm with signs of active bleeding (Figs. 1 and 2).

[☆] Please cite this article as: Espinar E, Soria A, Jimeno Fraile J, Parés D. Masa abdominal de aparición súbita. Cir Esp. 2014;92:e39.

^{*} Corresponding author.

E-mail address: David.pares@pssjd.org (D. Parés).