

Image of the month

Cystic Hepatic Neoplasm[☆]

Neoplasia quística hepática

Alba Manuel Vázquez,^{*} Teresa Carrascosa Mirón, Sagrario Fuerte Ruiz,
Alberto Carabias Hernández

Servicio de Cirugía General y Digestiva, Hospital Universitario de Getafe, Madrid, Spain

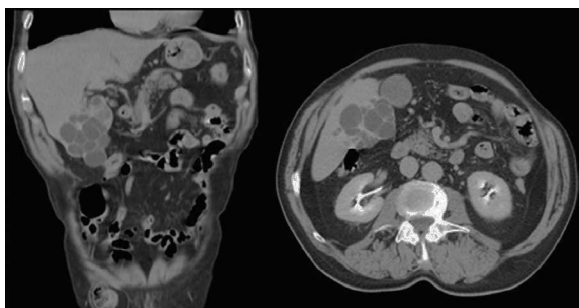


Fig. 1

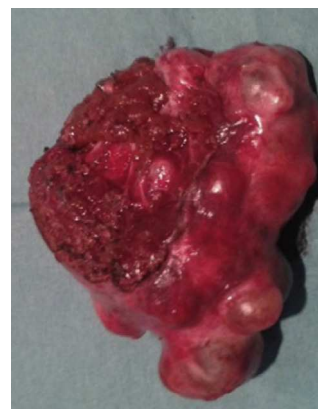

Fig. 2

On a follow-up CT scan for gallbladder neoplasm, a 72-year-old male presented an incidental finding of a multilocular, multicystic lesion of the liver with images of solid nodules in the wall of segment V and exophytic growth (Fig. 1). The differential diagnosis included cystadenoma versus cystadenocarcinoma of the biliary tree.

The patient was treated by a right subcostal laparotomy, where we observed a mass coinciding with the radiological description (Fig. 2). The liver lesion was resected, with no complications during the procedure. The patient was discharged on the third postoperative day.

The pathology of the specimen was compatible with benign mucinous cystic neoplasm of the liver (previously known as cystadenoma).

[☆] Please cite this article as: Manuel Vázquez A, Carrascosa Mirón T, Fuerte Ruiz S, Carabias Hernández A. Neoplasia quística hepática. Cir Esp. 2014;92(6):e35.

^{*} Corresponding author.

E-mail address: alba_manuel_vazquez@hotmail.com (A. Manuel Vázquez).

2173-5077/\$ – see front matter © 2014 AEC. Published by Elsevier España, S.L. All rights reserved.