

Image of the month

Cholecystocolic Fistula[☆]

Fístula colecistocólica

Beatriz de Andrés Asenjo,^{*} Jesús González Perea, Francisca Moreno Racionero,
José Rabadán Jiménez

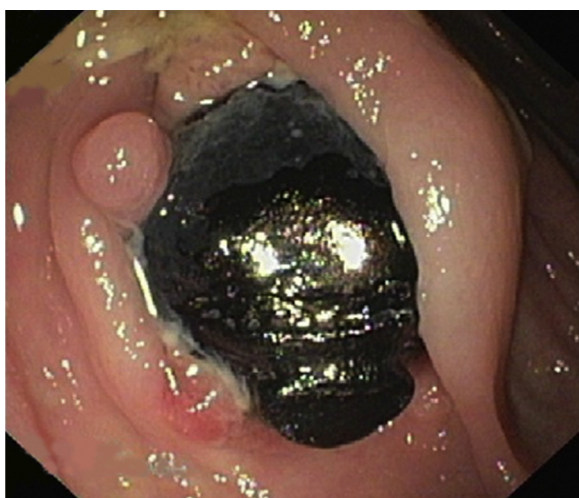

Fig. 1

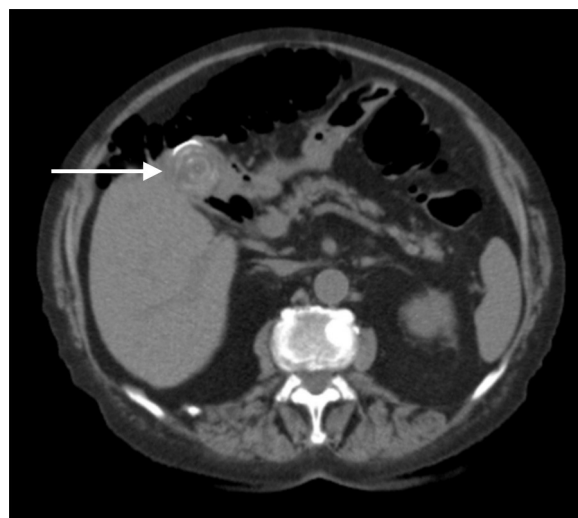


Fig. 2

The patient is an 87-year-old woman with a deteriorating general condition during the previous 4 months with diffuse abdominal pain, melenas, loss of appetite and weight loss.

The work-up showed anemia (7.4 g/dl). Colonoscopy revealed angiodysplasias in the right colon and a 2 cm calculus impacted in the proximal transverse colon between 2 folds of the mucus membranes (Fig. 1). Abdominal CT (Fig. 2) demonstrated pneumobilia, cystic mass in the head of the pancreas and a large calculus in the fundus of the gallbladder in contact with the hepatic angle of the colon. The patient refused surgical treatment.

Diagnosis: cholecystocolic fistula.

[☆] Please cite this article as: de Andrés Asenjo B, González Perea J, Moreno Racionero F, Rabadán Jiménez J. Fístula colecistocólica. Cir Esp. 2014;92:e27.

^{*} Corresponding author.

E-mail address: beatrizdeandres007@yahoo.es (B. de Andrés Asenjo).