

Image of the month

Rupture and Migration of a Reservoir Catheter in the Subclavian Vein[☆]



Rotura y migración de catéter de reservorio en vena subclavia

Dieter Morales-García,^{*} Manuel García de Polavieja, José Antonio Blasco Velarde, Manuel Gómez Fleitas

Servicio de Cirugía General y del Aparato Digestivo, Hospital Universitario Marqués de Valdecilla, Santander, Cantabria, Spain

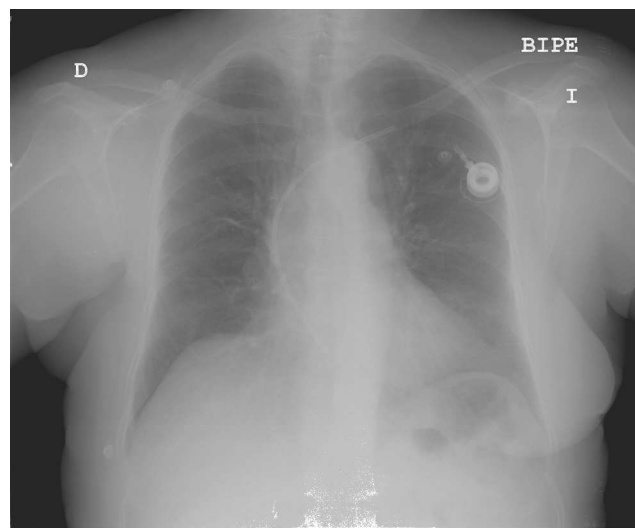


Fig. 1

The patient was a 66-year-old woman with breast cancer who had undergone chemotherapy. She had had a subcutaneous venous catheter implanted through the left subclavian vein six months earlier. She came to the Emergency Department due to sharp pain in the left hemithorax that radiated towards the shoulder. Physical examination was normal. Chest radiography (Fig. 1) showed that the reservoir catheter had broken and migrated due to the compression between the collar bone and first rib. The tube was extracted using a Dormia catheter and the reservoir port was withdrawn.

[☆] Please cite this article as: Morales-García D, García de Polavieja M, Blasco Velarde JA, Gómez Fleitas M. Rotura y migración de catéter de reservorio en vena subclavia. Cir Esp. 2014;92:126.

^{*} Corresponding author.

E-mail address: dms11@me.com, djmoralesgarcia@aecirujanos.es (D. Morales-García).
2173-5077/\$ – see front matter © 2013 AEC. Published by Elsevier España, S.L. All rights reserved.