

## Image of the Month

Unusual Cutaneous Metastasis of Transitional Carcinoma<sup>☆</sup>

## Metástasis cutánea excepcional de carcinoma transicional

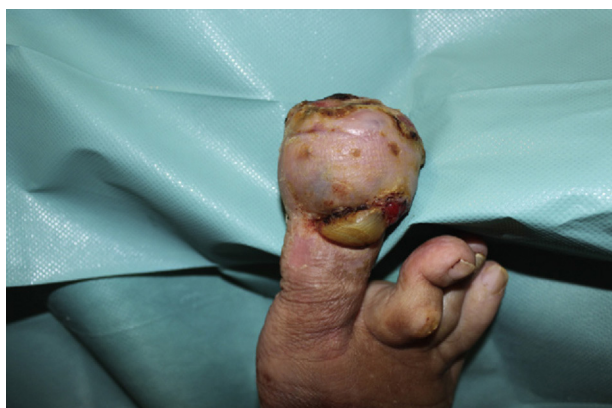M. Angoso Clavijo,<sup>a,\*</sup> J.I. González Muñoz,<sup>a</sup> Á. Santos-Briz Terrón,<sup>b</sup> E. Fonseca<sup>c</sup><sup>a</sup> Servicio de Cirugía, Hospital Universitario de Salamanca, Salamanca, Spain<sup>b</sup> Servicio de Anatomía Patológica, Hospital Universitario de Salamanca, Salamanca, Spain<sup>c</sup> Servicio de Oncología, Hospital Universitario de Salamanca, Salamanca, Spain

Fig. 1

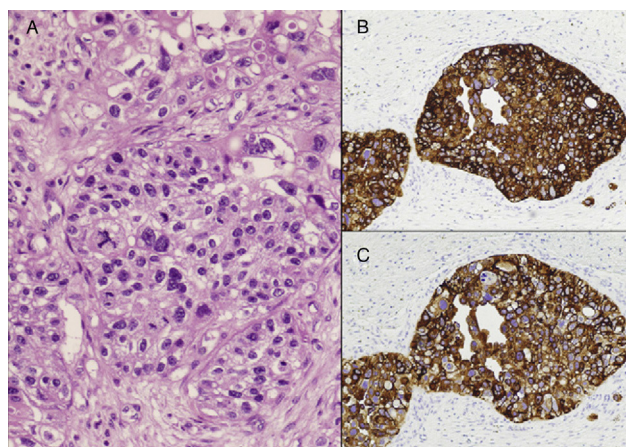


Fig. 2

A 73-year-old male with a history of transitional bladder carcinoma (T1N0M0) treated by TUR and bladder instillations with BCG and mitomycin in 2007 and 2009 presented in 2011 with a respiratory infection and was diagnosed with lung (FNA puncture +) and bone metastases. A month later, he developed an ulcerated lesion on the distal extremity of the left hallux, which was biopsied (Fig. 1). It was diagnosed as a cutaneous metastasis of urothelial carcinoma (Fig. 2). Given its rapid growth, the decision was made to perform a transmetatarsal amputation of the toe. The wound is currently completely healed and the patient continues treatment with chemotherapy.

Diagnosis: cutaneous metastasis of transitional carcinoma.

<sup>☆</sup> Please cite this article as: Angoso Clavijo M, et al. Metástasis cutánea excepcional de carcinoma transicional. Cir Esp. 2013;91:e3.

\* Corresponding author.

E-mail address: angosom@wanadoo.es, cardiakez@yahoo.es (M. Angoso Clavijo).

2173-5077/\$ – see front matter © 2011 AEC. Published by Elsevier España, S.L. All rights reserved.