


Diagnóstico Prenatal

www.elsevier.es/diagnprenat



Case report

Anophthalmia and microphthalmia: A clinical case with a prenatal diagnosis



Fátima Silva^{a,*}, Marta Osório^b, Conceição Brito^b, Ana Sousa^b, Cristina Godinho^b, Francisco Valente^b, Anabela Gomes^c

^a Department of Obstetrician/Gynecology, Centro Hospitalar Vila Nova de Gaia/Espinho, Vila Nova de Gaia, Portugal

^b Department of Obstetrician, Prenatal Diagnosis Unit, Centro Hospitalar Vila Nova de Gaia/Espinho, Vila Nova de Gaia, Portugal

^c Neonatology, Centro Hospitalar Vila Nova de Gaia/Espinho, Vila Nova de Gaia, Portugal

ARTICLE INFO

Article history:

Received 24 May 2013

Accepted 22 July 2013

Available online 24 October 2013

Keywords:

Anophthalmia

Microphthalmia

Ultrasound

ABSTRACT

Introduction: Anophthalmia and microphthalmia are serious eye malformations that describe, respectively, the absence of an eye and the presence of a small eye within the orbit. These conditions are the most frequent congenital eye malformations in the newborn, and the precise aetiology remains unknown, but they may occur in isolation or as part of a syndrome, with chromosomal, monogenic and environmental causes already identified. The pre- and post-natal diagnosis can be made using imaging techniques and genetic analysis. The authors present a clinical case diagnosed prenatally.

Case report: A 35 year-old primiparous woman, with normal first trimester examinations and karyotype 46,XX, in whom the ultrasound at 18/23 weeks revealed an asymmetry of ocular globes, with a small diameter of the left orbit. This study was complemented with foetal magnetic resonance that confirmed a severe microphthalmia in the left eye, with difficulty in observing the integrity of the optic nerve. The interruption of the pregnancy was discussed, but the parents did not want this. The remaining routine examinations were normal. The pregnancy was terminated at 37 weeks, palpebral closure with absence of ocular globe of the left eye and opacification of cornea and microphthalmia in the right eye was confirmed.

Conclusion: This case shows that a difficult diagnosis of a rare pathology can be made in utero by ultrasound. However, some are impossible to diagnosis, and this must be explained to parents.

© 2013 Asociación Española de Diagnóstico Prenatal. Published by Elsevier España, S.L.

All rights reserved.

Anofthalmia y microftalmia: caso clínico con el diagnóstico prenatal

RESUMEN

Introducción: Anofthalmia y microftalmia son malformaciones graves en los ojos que describen, respectivamente, la ausencia de un ojo y de la presencia de un ojo pequeño dentro de la órbita. Estas condiciones son la malformación ocular congénita más frecuente en el recién nacido, y la etiología exacta se desconoce, pero pueden ocurrir en forma aislada

Palavras chave:

Anofthalmia

Microftalmia

Ecografía

* Corresponding author.

E-mail address: fatimasilva.15@gmail.com (F. Silva).

2173-4127/\$ – see front matter © 2013 Asociación Española de Diagnóstico Prenatal. Published by Elsevier España, S.L. All rights reserved.

<http://dx.doi.org/10.1016/j.diapre.2013.07.005>

o como parte de un síndrome, con chromosomal, monogénica y las causas ambientales ya identificados. Los autores presentan un caso clínico diagnosticado prenatalmente.

Reporte de un caso: Primípara, de 35 años, con exámenes trimestrales primero normales y cariotipo 46, XX. En 18/23 semanas, la ecografía reveló una asimetría de los globos oculares, con un pequeño diámetro en órbita izquierda. Este estudio se complementa con resonancias magnética foetal, que confirmó una microftalmia severa de la izquierda con dificultad en la observación de la integridad del nervio óptico. Nesse momento se discutió la interrupción del embarazo, pero los padres no aceptó. Los restantes exámenes de rutina fueron normales. El embarazo se dio por terminada a las 37 semanas, y se confirmó el cierre palpebral con la ausencia de globo ocular a la izquierda y la opacificación de la córnea y microftalmia en el ojo derecho.

Conclusión: Este caso demuestra que un diagnóstico difícil de una patología poco frecuente, se puede hacer en el útero por ecografía. Sin embargo, algunos son imposibles de diagnóstico y esto debe ser explicado a los padres.

© 2013 Asociación Española de Diagnóstico Prenatal. Publicado por Elsevier España, S.L. Todos los derechos reservados.

Introduction

Anophthalmia and microphthalmia are eye malformations that are responsible for visual impairment, or reduced vision, in newborn and children. Anophthalmia refers to complete absence of the globe in the presence of ocular adnexa (eyelids, conjunctiva and lachrymal apparatus), and microphthalmia is defined as a globe with a total axial length that is at least two standard deviations below the mean for age. Microphthalmia can be classified according to the anatomic appearance and the severity of the reduction of the globe: severe microphthalmia refers to a globe with a corneal diameter less than 4 mm and a total axial length less than 10 mm at birth.¹

These ocular malformations can be unilateral or bilateral, and can be isolated or occur with other malformations as part of a syndrome. The precise aetiology is heterogeneous and remains unknown, but there are environmental agents that may be involved, genetic factors, and probably vascular disruption. The known environmental causes include rubella, alcohol, thalidomide, retinoic acid and hydantoin. The heritable causes include the chromosome abnormalities (aneuploidy, deletions, rearrangements), and single gene disorders (syndromic or non syndromic).

The prenatal diagnosis, that is now available, permits the early diagnosis of these diseases and the awareness to other malformations or signs that may preview the prognosis, which must be carefully explained to parents. The sonography has a vital role in *in utero* diagnosis, complemented by magnetic resonance.^{2,3}

Case report

We present a case of a primipara woman, 35 years old, with no relevant medical history. This pregnancy was planned, followed in private Obstetrician up to the 20th week.

The first trimester exams were normal, including the 12th week ultrasound. Because of the age and maternal anxiety, the expectant performed amniocentesis at 15th week, for cytogenetic study, that revealed a normal cariotipo: 46,XX.

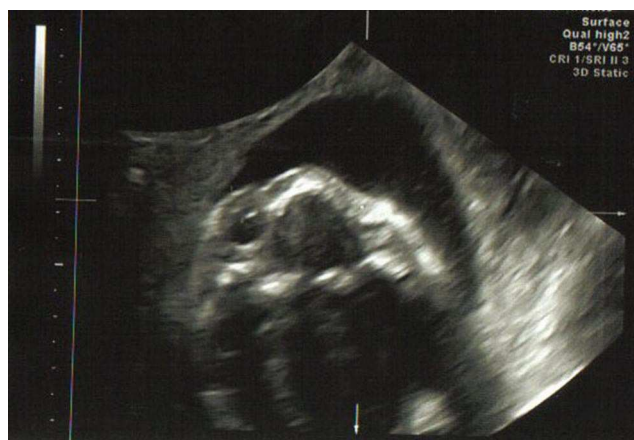

Fig. 1 – Obstetric ultrasound at 20 weeks; asymmetry of foetal ocular globes.

In the second trimester, first at 20 and later at 23 weeks, the morphologic ultrasonography revealed an asymmetry of ocular globes (Figures 1 and 2), with a small diameter in the left orbit with a total axial length of 8 mm (Figures 3 and 4). This

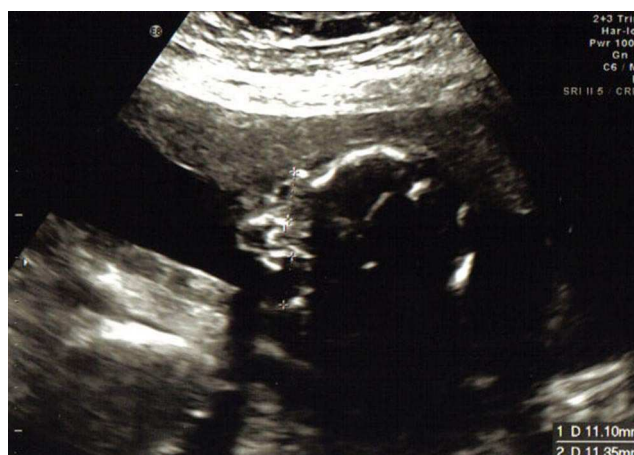

Fig. 2 – Obstetric ultrasound at 20 weeks; asymmetry of foetal ocular globes.

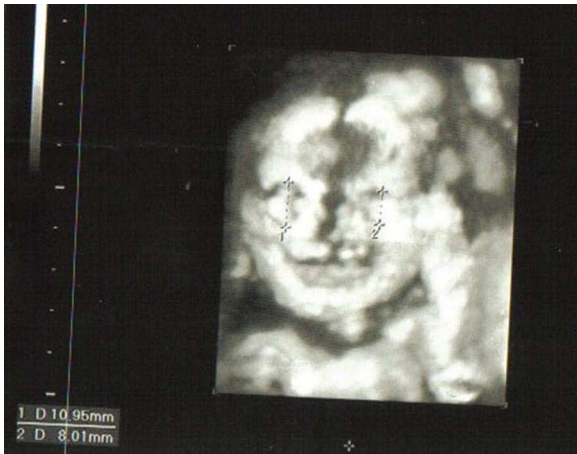

Fig. 3 – 3D ultrasound at 23 weeks; asymmetry of foetal ocular globes.

study was complemented with foetal magnetic resonance that confirmed a severe left microphthalmia, with difficult in observation of optic nerve integrity.

It was explained to the couple the unknown prognostic concerning to the future visual acuity and the termination of this pregnancy was debated, but the parents rejected this intervention.

The other routine tests, done at this gestational age, were normal. In the subsequent ultrasounds the ocular globes asymmetry became more obvious.

At 36 weeks the pregnant woman was admitted in the Obstetrics Department with tensional elevation and proteinuria (suspicion of mild preeclampsia). In ultrasound exam it was detected a symmetrical intra uterine growth restriction and fluxometric alterations. The pregnancy was interrupted at 37 weeks, with surgical delivery, due to induction failure. The newborn female was born with Apgar scores 8/10 (first and fifth minute) and a weight of 2300 g. She was admitted in Neonatology Unity because of low weight and ocular malformation evaluation.

The first physical examination confirmed ocular congenital malformation (Figure 5), that was not coincident with

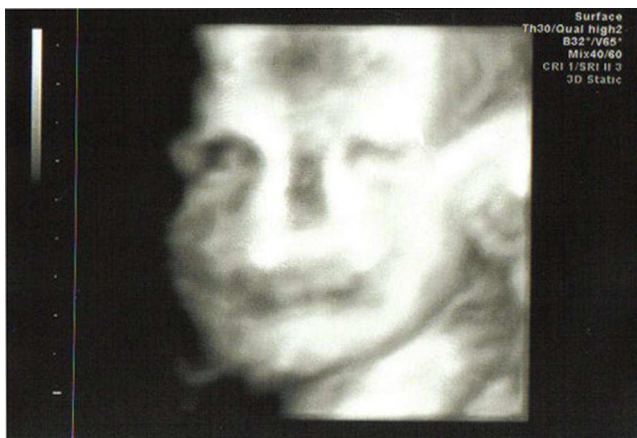

Fig. 4 – 3D ultrasound at 23 weeks; asymmetry of foetal ocular globes.

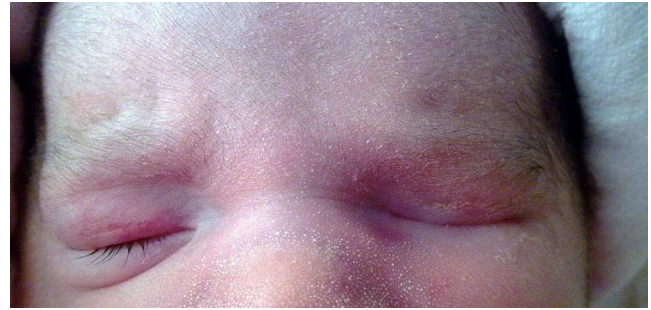

Fig. 5 – Newborn with left palpebral closure.

the prenatal supposed: left palpebral closure with absence of ocular globe, and opacification of cornea and microphthalmia in the right eye. An ophthalmologic evaluation was done in neonatal period, confirming total visual impairment. An oculoplastic surgeon evaluation was also performed, in order to analyse prosthetic intervention and surgery. The child remains in surveillance in paediatric and ophthalmologic consultation, without any surgical intervention until now.

Discussion/conclusion

Anophthalmia and microphthalmia are heterogeneous diseases and it is extremely difficult to predict the morbidity in the future of these children.

This case is an example of a rare pathology which diagnosis can be made in prenatal period. This intra uterine diagnosis is not easy or frequent, however, the advances in technology of ultrasonography machines, like the use of 3D images, help and permit this anticipation.

In the case reported only the diagnosis of ocular malformation was made in *uterus*, because we verified that the newborn had anophthalmia in the left eye and microphthalmia in the right eye, not the left microphthalmia suspected by the prenatal ultrasounds and by the foetal magnetic resonance, which had supported our diagnostic hypothesis of isolated unilateral microphthalmia. Although, we consider that the prenatal finding of ocular malformation allowed us to alert the parents for this pathologies and prepare them for the treatments that can be offer in the neonatal and paediatric life.

The aetiology of these congenital ocular malformations has a very important role in the prognosis; however we know many causes that are not totally understood, mostly the genetics, which remains as the most likely cause for the appearance of this malformation in the presented case report.

The management of anophthalmia/microphthalmia is mostly supportive, but many surgical interventions have been proposed in the last years to obtain a good cosmetic outcome with periocular symmetry. Early intervention and therapy to optimise psychomotor development, educational endeavours, life skills and mobility are essential.⁴ The treatment may include evaluation by an oculoplastic surgeon in order to analyse prosthetic intervention and surgery.⁵

Actually this child remains waiting for surgical intervention, in order to improve her quality of life.

Ethical disclosures

Protection of human and animal subjects. The authors declare that the procedures followed were in accordance with the regulations of the responsible Clinical Research Ethics Committee and in accordance with those of the World Medical Association and the Helsinki Declaration.

Confidentiality of Data. The authors declare that they have followed the protocols of their work centre on the publication of patient data and that all the patients included in the study have received sufficient information and have given their informed consent in writing to participate in that study.

Right to privacy and informed consent. The authors declare that no patient data appears in this article.

Conflict of interests

The authors declare that there are no conflicts of interest.

REFERENCES

1. Guthoff RF. Anophthalmia and microphthalmia. *Ophthalmologe*. 2003;100:501–2.
2. Paquette L, Randolph L, Incerpi M, Panigrahy A. Fetal microphthalmia diagnosed by magnetic resonance imaging. *Fetal Diagn Ther*. 2008;24:182–5.
3. Roth P, Roth A, Clerc-Bertin F, Sommerhalder J, Maillet R. Prenatal ultrasonic measurements of the eye and the interorbital distance. *J Gynecol Obstet Biol Reprod (Paris)*. 1999;28:343–51.
4. Bernardino R. Congenital anophthalmia: a review of dealing with volume. *Middle East Afr J Ophthalmol*. 2010;17:156–60.
5. Llorent-González S, Peralta-Calvo J, Abelairas-Gómez JM. Congenital anophthalmia and microphthalmia: epidemiology and orbitofacial rehabilitation. *Clin Ophthalmol*. 2011;5:1759–65.