

ORIGINAL ARTICLE

Lumbar synovial cysts: Presentation of a series of 10 cases and literature review[☆]



O. Lista-Martínez^{a,*}, V.M. Moreno-Barrueco^b, J. Castro-Castro^a, P. Varela-Rois^a,
A. Pastor-Zapata^a

^a Servicio de Neurocirugía, Complejo Hospitalario Universitario de Orense, Orense, Spain

^b Servicio de Cirugía Ortopédica y Traumatología, Hospital HM Modelo, A Coruña, Spain

Received 12 May 2016; accepted 23 July 2016

KEYWORDS

Synovial cyst;
Lumbar spine;
Instability;
Surgical management

Abstract

Introduction: Although they are frequently described in the literature, lumbar synovial cysts are a relative uncommon cause of low back and radicular leg pain.

Objective: To evaluate the treatment and surgical outcomes of the lumbar synovial cysts operated on in our hospital during a 5 year period.

Material and methods: A retrospective study was conducted on patients surgically treated in our department from August 2009 to September 2014, using a visual analogue scale for the clinical follow-up in the first year after surgery.

Results: After the surgical treatment (surgical removal of the synovial cyst with or without instrumented arthrodesis with transpedicular screws) of 10 patients (5 female and 5 male) with a mean age of 70.2 years (range 50–80), the clinical outcome was satisfactory in 80% of the patients, with the resolving of their symptoms.

Conclusions: Lumbar synovial cysts have to be considered in the differential diagnosis in patients with low back and radicular leg pain. The majority of the patients are in their sixties and have lumbar degenerative spondylopathy. Nowadays, surgical resection of the lumbar synovial cysts and spinal fusion are the recommended treatment, because it is thought that the increased movement of the spine is one to the causes of the cyst formation. More studies are still needed, hence the relevance of this article.

© 2016 SECOT. Published by Elsevier España, S.L.U. All rights reserved.

[☆] Please cite this article as: Lista-Martínez O, Moreno-Barrueco VM, Castro-Castro J, Varela-Rois P, Pastor-Zapata A. Quistes sinoviales lumbares: presentación de una serie de 10 casos y revisión de la literatura. Rev Esp Cir Ortop Traumatol. 2017;61:28–34.

* Corresponding author.

E-mail address: olallalista@hotmail.com (O. Lista-Martínez).

PALABRAS CLAVE

Quiste sinovial;
Columna lumbar;
Inestabilidad;
Manejo quirúrgico

Quistes sinoviales lumbares: presentación de una serie de 10 casos y revisión de la literatura**Resumen**

Introducción: Los quistes sinoviales lumbares son una causa infrecuente de dolor lumbar y radicular, aunque cada vez se describen con más frecuencia en la literatura.

Objetivo: Analizar el tratamiento y resultados quirúrgicos de los quistes sinoviales lumbares intervenidos en nuestro centro en un período de 5 años.

Material y métodos: Se realizó un estudio retrospectivo de pacientes tratados quirúrgicamente en nuestro servicio entre agosto de 2009 y septiembre de 2014, empleando la escala visual analógica para seguimiento clínico durante el año posterior a la cirugía.

Resultados: Tras el tratamiento quirúrgico (exéresis del quiste con o sin artrodesis instrumentada con tornillos transpediculares), de 10 pacientes (5 mujeres y 5 varones) de edades comprendidas entre los 50 y 80 años (edad media 70,2 años), la evolución clínica fue satisfactoria en el 80% de ellos con resolución de su sintomatología.

Conclusiones: Los quistes sinoviales lumbares deben ser considerados en el diagnóstico diferencial de pacientes con dolor lumbar y radicular. La mayoría de estos pacientes están en la 6.^a década de la vida y presentan generalmente una espondilopatía degenerativa lumbar. En la actualidad, se recomienda la exéresis de los quistes sinoviales con artrodesis instrumentadas con tornillos transpediculares, ya que se considera que el aumento de movilidad podría ser una de las causas de su aparición; aunque todavía se necesitan más estudios al respecto, de ahí el interés de este trabajo.

© 2016 SECOT. Publicado por Elsevier España, S.L.U. Todos los derechos reservados.

Introduction

Lumbar synovial cysts (LSC) appear in the zygapophyseal joint capsule of the lumbar spine. Von Gruker was the first to describe these lesions in 1880. In 1974 Kao *et al.*¹ were the first authors to report symptomatic nerve compression secondary to a lumbar synovial cyst and called these juxtafacet cysts. Their aetiology is unknown but it is believed that the extrusion of synovial fluid by the facet joint and the progressive growth of residual myxoid degeneration could be one of the causes. Increased mobility and repetitive micro traumas may possibly be influential to their formation.^{1,2}

The majority of LSC patients are in their sixties and generally present with lumbar degenerative spondylosis. This is less frequent in younger patients where trauma is considered to principally be a possible trigger for formation.²

The prevalence of LSC is unknown and it is probable that no uniform distribution exists in all populations (0.65–10%). They are most frequently found in the lumbar region (85–95% of cases) and in females and usually mimic the symptoms of a lumbar herniated disc, leading to lower back pain and radicular pain.³ Neurological deficit is extremely rare. In young adults and children they are rare but cases have been reported in the literature.²

Material and methods

A retrospective descriptive study was conducted on a series of 10 patients surgically treated in our LSC department, with a histologically confirmed diagnosis, between August 2009 and September 2014, both inclusive. This study was carried

out in compliance with the ethical regulations of the hospital research committee. The cysts were identified by lumbar sacral spine magnetic resonance imaging (MRI).

The patients underwent surgery following the initial failure of conservative treatment, consisting of a lack of response to analgesic and rehabilitation treatment. No infiltration techniques were used on these patients due to the possible risk of bleeding. All the patients gave their informed written consent and received the same pre-operative antibiotic prophylaxis in accordance with the Preventative Medicine Service protocol at the hospital. Surgical treatment comprised isolated excision of the synovial cyst with or without associated spinal instrumentation. Progressive follow-up after hospital discharge was for a minimum of a year with patients attending a consultation 3, 6, 9 and 12 months after surgery. A visual analogue scale (VAS) and control X-rays were used for all clinical follow-up.

Following identification of the cases, analysis was made of the epidemiology, clinical characteristics, imaging findings, therapeutic approach, patient evolution and any complications.

Results

10 patients surgically treated for LSC at our hospital during the period mentioned above were identified. There were 5 women and 5 men with ages ranging between 50 and 80 (mean age 70.2 years).

Clinical presentation consisted of: radicular pain in 4 patients (40%), claudication in 2 (20%), Lower back pain and

radicular pain in 2 (20%) and radicular pain with claudication in the other 2 (20%).

Diagnostic radiology was performed only with MRI and computerised tomography was not performed in any cases.

In 60% of cases lesion location was facet joint at L4–L5 level (4 on the right side and 2 on the left side) and in 40% of cases it was facet joint at L3–L4 level (2 on the right side and 2 on the left side).

Seven patients who presented with canal stenosis and grade I spondylolisthesis in addition to synovial cysts underwent laminectomy, synovial cyst excision and spinal fixation surgery with transpedicular screws. One of the patients underwent this secondary surgery following failure of initial surgery with isolated excision of the cyst by hemilaminectomy and facetectomy (case 5). Two patients underwent hemilaminectomy and excision of the synovial cyst, respecting the facets and one patient, the oldest in our series (case 4), who in addition to the cyst also presented with canal stenosis underwent laminectomy at this level with cyst excision but without instrumented arthrodesis in this case.

In the 7 patients who required arthrodesis with transpedicular screws, the screws were guided by navigation and intraoperative computerised tomography. Of the 40 implanted screws, one of them was intraoperatively reinserted owing to an initial malposition (case 8), which led to an error percentage of 2.5%. There were no intraoperative complications in the other patients. Three patients underwent spine fusion instrumentation at level one; two patients at level two and the other two patients at level three.

Intraoperatively yellowish-brownish well defined extradural masses were distinguished which were the continuation of the facet joint along its medial surface and filled with a clear or xanthochromic liquid (except in case 8 which contained haematic matter).

In all patients the diagnosis of synovial cyst was confirmed by pathological anatomy which revealed the presence of conjunctive tissue lesions with calcium deposits, areas of haemorrhaging and fibrosis with granulation tissue lined by a thick wall of a specialised synovial epithelium.

The minimum follow-up of all patients was one year. 80% of patients experienced relief of previous symptoms and a lowering of at least 6 points in the VAS. Seven patients are currently discharged from hospital, and one patient died a year and a half after surgery from an acute coronary syndrome which was not associated with surgical intervention (case 4). Another two patients continue to present with mild mechanical lower back pain (VAS 1–2) which is relieved with analgesics (case 5 and 8). None of the 3 patients who did not undergo spinal instrumentation have showed any signs of clinical instability in follow-up to date or recurrence of synovial cysts (Table 1).

Discussion

LSCs are an uncommon cause of lumbar and radicular pain, although they are described in the literature with increasing frequency. Synovial cysts may appear at vertebral level but most frequently occur in the joints of the extremities. In the spine they are located at extradural level in the continuation of the degenerated facet joint along its medial surface,

generally in the L4–L5 space (as in 60% of our cases), this being the most mobile section of the spine and the one most associated with spondylolisthesis and osteoarthritis, leading to instability and facet arthrosis which plays an essential role in the formation of the above-mentioned cysts.^{2–4} L4–L5 level is the most affected space, followed by L5–S1, L3–L4, and L2–L3 (unlike our series in which the second level most affected was L3–L4).

Their pathogenesis is widely debated although it is generally accepted that they forms part of the degenerative spinal process, where spinal instability and trauma are significant.^{3–6} The definitive association of these cysts with osteoarthritis (40.5%), spondylolisthesis (43.4%), and disc degeneration (13.2%) highlights their degenerative nature.^{3–5}

LSC are in fact local instability markers of the functional spinal unit, and therefore their expansion or regression is closely linked to local physiological factors such as vascularisation of the synovial fluid of the joint, the possibility of intracystic haemorrhages and the degree of local inflammation of the facet. The disruption of a facet increases instability of the functional spinal unit and increases the biomechanical stress of the contralateral facet joint which accelerates its degeneration.^{4–6}

Microscopically synovial cysts contain xanthochromic or clear fluid, are enclosed by the spinal epithelium which is pseudostratified around a fibrous grainy tissue with myxoid changes and presents a demonstrable communication with the joint capsule.^{6–10}

The most frequent symptom is lower back or radicular pain (55–97%), as occurred in our cases, although neurogenic claudication and cauda equine syndrome may also present. This is usually a case of a progressive lower back pain or long term claudication with or without associated radiculopathy, which may, on occasions present in a more acute or sub acute manner if associated with intracystic haemorrhaging of the lesion (as in case 8).

MRI is the technique of choice for diagnosis, since it reveals the cystic nature of the lesion. Intermediate signal intensity of extradural masses extending along the medial side of the facet joint which compress the dural sac are observed.^{3,6,11–14} These are well defined epidural masses, which are normally T1 isointense and T2 hyperintense or isointense, although intensity may vary depending on the protein content, previous haemorrhage and/or calcification. Fig. 1 – T2 sagittal (isointense) and T1 axial (isointense) of right LSC L4–L5 (case 7) – and Fig. 2 – T1 sagittal (isointense), and T2 sagittal and axial sagittal (hypertense, haematic material) of left LSC L4–L5 (case 8). Anticoagulant treatment, trauma, herniated disc, vascular anomalies, and neovascularisation in the synovial coating of the cyst are risk factors for intracystic haemorrhaging.¹⁵ The presence of gas on the inside of the cyst may be a pathognomonic event.⁶

Differential diagnosis with other juxtafacet cysts (ganglion cysts, yellow ligament cysts and posterior longitudinal ligament cysts) is important because it conditions the type of surgery and approach used.^{6–9,12,16} Non synovial cysts are not in direct contact with the zygoapophyseal joint and there is an absence of a specialised epithelial coating resulting in no major degenerative changes being provoked in the biomechanics of the so-called functional spinal unit. A contra-lateral approach may therefore

Table 1 Our series of 10 cases.

Patients	Age	Clinical symptoms	Year	Findings	Surgery	Complications	Evolution
1. Male	57	Sciatica	2009	LSC L4–L5 D	HL + CE	No	EVA 0. Discharged
2. Male	76	Sciatica	2010	LSC L4–L5 D	HL + CE	No	EVA 0. Discharged
3. Female	77	Sciatica	2011	Listesis L4–L5 G1 + LSC L4–L5 I	L + CE + IATS 1 level	No	EVA 0. Discharged
4. Male	80	Claudication	2011	Stenosis L4–L5 + LSC L4–L5 D	L + CE	No	Death (ACS) EVA 1 EVA 2
5. Female	70	Lower back pain + sciatica	2012 2014	LSC L3–L4 I Listesis L4–L5 G1 + stenosis L5–S1	HL + FCT + CE L + IATS 2 levels	No	EVA 2
6. Male	50	Lower back pain + sciatica Claudication	2013	Stenosis L3–L4–L5–S1 + LSC L3–L4 I	L + CE + IATS 3 levels	No	EVA 0. Discharged
7. Female	73	Sciatica	2013	Stenosis L4–L5–S1 + LSC L4–L5 D	L + CE + IATS 2 levels	No	EVA 0. Discharged
8. Male	74a	Lower back pain + sciatica	2014	Stenosis L4–L5 + LSC L4–L5 I	L + CE + IATS 1 level	Relocation IO screw	EVA 1
9. Female	76a	Sciatica + claudication	2014	Stenosis + listesis L3–L4 G1 + LSC L3–L4 D	L + CE + IATS 1 level	No	EVA 0. Discharged
10. Female	69	Sciatica + claudication	2014	Listesis L5–S1 G1 + LSC L3–L4 D	L + CE + IATS 3 levels	No	EVA 0. Discharged

IATS: instrumented arthrodesis with transpedicular screws; R: right; CE: cyst excision; FCT: facetectomy; G1: grade 1; HL: hemilaminectomy; L: left; IO: intraoperative; L: laminectomy; LSC: lumbar synovial cysts; ACS: acute coronary syndrome.

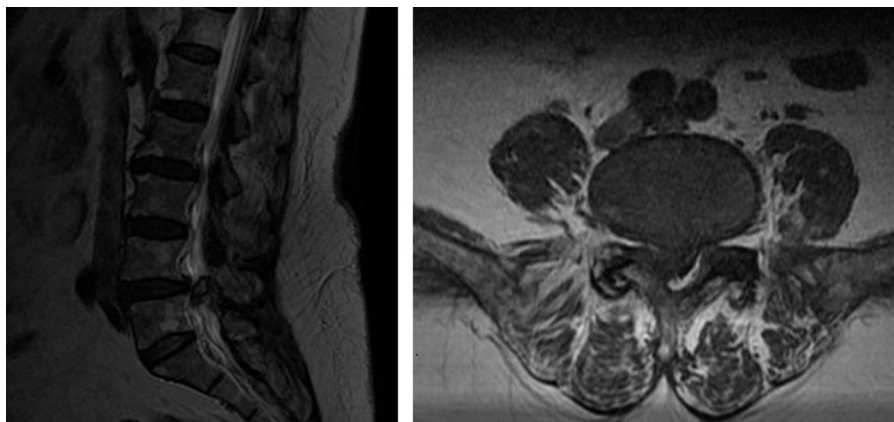


Figure 1 T2 sagittal (isointense) and T1 axial (isointense) of right LSC L4–L5 (case 7).

be used without the need for surgical resection of the adjacent facet.^{8,9} On the contrary, true synovial cysts are the last phase of joint degeneration and there is therefore a much higher risk of instability and a tendency for a more aggressive approach in fusion, particularly data regarding associated degenerative changes (disc collapse,

listesis) and lumbar pain (not only radicular) are present. In addition to the differential diagnosis with other juxtafacet cysts, infections and tumours such as neurofibroma, schwannoma or metastasis^{6,8,9} must be ruled out with the use of erythrocyte sedimentation rate and reactive protein C studies.

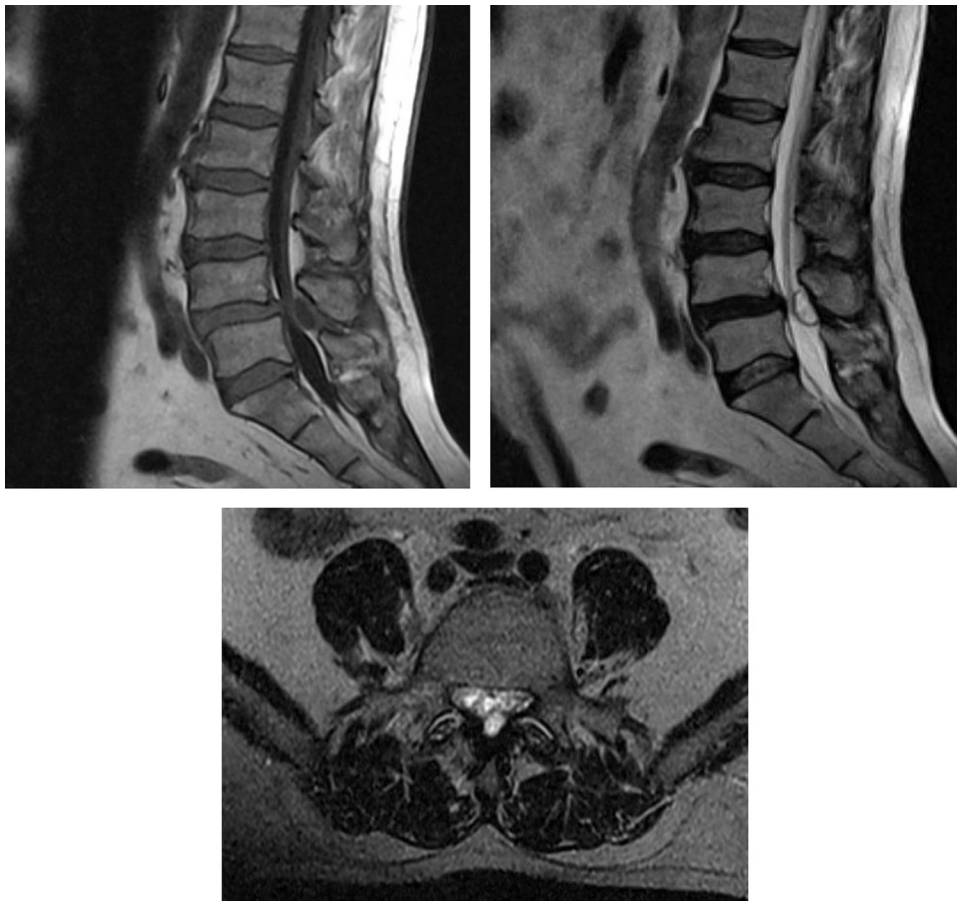

Figure 2 T1 sagittal (isointense), and T2 sagittal and axial (hypertense, haematic material) of left LSC L4–L5 (case 8).

When these cysts do not respond to conservative treatment, there is great controversy regarding the best surgical approach. A surgical approach may range from simple excision of the synovial cyst with hemi or laminectomy, to minimally invasive techniques or even synovial cyst removal with associated instrumentation.

The advantage of open surgery is that it provides extensive and appropriate exposure of the cysts and areas of attachment, leading to macroscopic confirmation for excision (Fig. 3) – intraoperative image of synovial cyst right L3–L4 (case 9). Its disadvantage is that it presents the need to carry out medial facetectomy which when combined with an already degenerated spine, increases the risk of instability, with the dilemma of whether to use transpedicular screws for attachment or not.

Minimally invasive spine surgery with tubular retractors for access was described by Foley *et al.*¹⁷ in 1997. The paramedian ipsilateral lumbar spine approach has minimised incision, reduced blood loss, and decreased postoperative pain, but there is still the need for surgical resection of the medial facet and thus potentially accelerating the risk of degeneration and possibility of recurrence of the synovial cyst or segmental instability.^{8,9,12,15} In the light of this, the minimally invasive contralateral approach has been described, using a contralateral hemilaminectomy with preservation of the degenerated facet, to prevent possible future instability of the joint complex and recurrence of

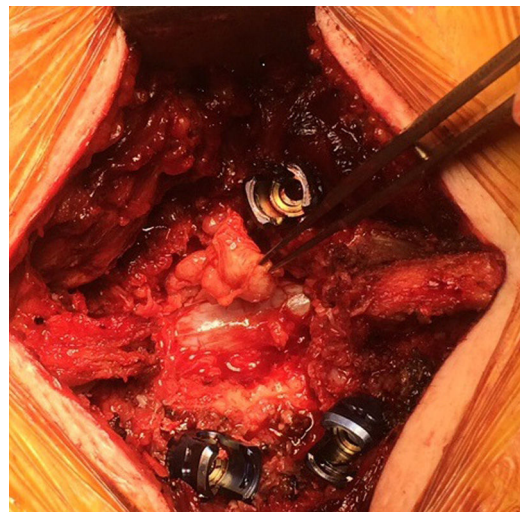


Figure 3 Intraoperative image of synovial cyst at right L3–L4 level (case 9).

the cyst (1.3%–10.8%) and the need for spine fusion. The problem with this technique is that it is more demanding from a surgical point of view, with a higher risk of incidental durotomy, epidural haematoma and cerebrospinal fluid leakage.^{8,9,11–13,15,16}

Laminectomy with instrumented fusion demands a more aggressive approach, associated with greater blood loss, higher neurological risk and long term risk of disease of the adjacent disc presenting. However, in a retrospective study of 39 cases, Khan *et al.* concluded that the patients who undergo spinal instrumentation with laminectomy would tend to have better results in scales of clinical improvement if they were compared with those who had simply undergone spinal decompression surgery.¹⁰ Notwithstanding, in our case 4, despite having carried out an excision of synovial cyst and a laminectomy, we did not carry out instrumented arthrodesis, due to greater aggressiveness and longer time in surgery, which would have increased the surgical risk of a patient aged 80.

The recurrence of synovial cysts after surgery varied between 1.3% and 10.8%. The risk of post surgical instability after isolated decompression is low but may support the adjuvant arthrodesis approach, generally when facetectomy is carried out or when there is proof of preoperative instability.^{3,6,8,12,15,18-20}

This review has several limitations: firstly there were only 10 cases in the series and secondly a long term follow-up was required to reach relevant conclusions. However, we believe that in young patients where it is presupposed that trauma is the trigger of the cyst and there are no instability data we should firstly implement a more conservative approach with simple excision of the cyst and close monitoring with dynamic radiographs to detect instability data if they appear. In older patients where instability of the degenerated spine is the actual cause of the LSC and where their physical condition allows it, we consider that an excision of the cyst would be better indicated, together with an associated spinal instrumentation.

Conclusions

LSCs are a rare pathology, but responsible for lower back and radicular pain, especially in patients of advanced age, although they may exceptionally present in young people (<40). They are degenerative lesions of juxtafacet location. MRI is the diagnostic technique of choice.

Surgical resection should be considered a treatment option in patients who do not respond to conservative treatment. Unfortunately, the surgical approach to be followed continues presently to be under debate. We believe that the possibility of using spinal instrumentation should be considered to prevent spinal instability and recurrence of the cyst, personalising each case (size of cyst, age and patient circumstances, compromise of neighbouring structures, lumbar and/or radicular pain, degree of preoperative listesis and degeneration of facet joint). After excision of a synovial cyst where partial facetectomy is required there is the possibility in the future of requiring a spinal fusion and for this reason these patients must be closely monitor for any possible appearance of clinical instability.

Level of evidence

Level of evidence II.

Ethical disclosures

Protection of people and animals. The authors declare that this investigation did not require experiments on humans or animals.

Confidentiality of data. The authors declare that they have followed the protocols of their workplace on the publication of patient data.

Right to privacy and informed consent. The authors declare no patient data appears in this article.

Conflict of interests

The authors have no conflict of interests to declare.

References

1. Kao CC, Winkler SS, Turner JH. Synovial cyst of spinal facet. Case report. *J Neurosurg.* 1974;41:372-6.
2. Kalevski S, Haritonov D, Peev N. Lumbar intraforaminal synovial cyst in young adulthood: case report and review of the literature. *Global Spine J.* 2014;4:191-6.
3. Ganau M, Ennas F, Bellisano G, Ganau L, Ambu R, Faa G, et al. Synovial cysts of the lumbar spine — pathological considerations and surgical strategy. *Neurol Med Chir (Tokyo).* 2013;53:95-102.
4. Jin HS, Bae JY, In CB, Choi EJ, Lee PB. Epiduroscopic removal of a lumbar facet joint cyst. *Korean J Pain.* 2015;28:275-9.
5. Onofrio BM, Mh AD. Synovial cysts of the spine. *Neurosurgery.* 1988;22:642-7.
6. Zhembo Z, Huanting L, Jin W, Haifeng G, Yuan F, Ming L. Hemilaminoplasty for the treatment of lumbar intraspinal synovial cysts (LISCs) and literature review. *Eur Spine J.* 2014.
7. Ganau M, Ennas F, Ambu R, Faa G, Maleci A. Excision of synovial cysts: pathology matters. *J Neurosurg Spine.* 2013;19:266-7.
8. Mattei T, Rodriguez A. True synovial cysts of the lumbar spine: an epiphenomenon of instability of the functional spine unit. *Neurosurg Rev.* 2013;36:495-500.
9. Rhee J, Nasr Anaizi A, A Sandhu F., Voyadzis J. Minimally invasive resection of lumbar sinovial cysts from a contralateral approach. Report of 2 cases. *J Neurosurg Spine.* 2012;17:453-8.
10. Khan A, Girardi F. Spinal lumbar sinovial cysts. Diagnosis and management challenge. *Eur Spine J.* 2006;15:1176-82.
11. Cambron SC, McIntyre JJ, Guerin SJ, Li Z, Pastel DA. Lumbar facet Joint Synovial Cysts: does T2 signal intensity predict outcomes after percutaneous rupture? *Am J Neuroradiol.* 2013;34:1661-4.
12. Epstein N, Baisden J. The diagnosis and management of synovial cysts: efficacy of surgery versus cyst aspiration. *Surg Neurol Int.* 2012;3:S157-66.
13. Huang K, Owens T, Wang T, Moreno J, Bagley J, Giant L. Completely calcified lumbar juxtafacet cyst: report of an unusual case. *Global Spine J.* 2014;4:175-8.
14. Park HS, Sim HB, Kwon SC, Park JB. Hemorrhagic lumbar synovial cyst. *J Korean Neurosurg.* 2012;52:567-9.
15. Satiro Timbo L, Rosembegf LA, Brandt RA, Botticini Peres R, Kyosen Nakamura O, Frota Guimaraes J. Can lumbar hemorrhagic synovial cyst cause acute radicular compression? Case report. *Einstein.* 2014;12:509-12.
16. Kozar S, Jeromel M. Minimally invasive CT guided treatment of intraspinal synovial cyst. *Radiol Oncol.* 2014;48:35-9.
17. Foley KT, Smith MM. Microendoscopic discectomy. *Tech Neurosurg.* 1997;3:301-7.

18. Cannarsa G, Clark SW, Chalouhi N, Zanaty M, Heller J. Hemorrhagic lumbar synovial cyst: case report and literature review. *Nagoya J Med Sci.* 2015;77:481–92.
19. Shah R, Lutz G. Lumbar intraspinal synovial cyst: conservative management and review of the world's literature. *Spine J.* 2003;3:479–88.
20. Pindrik J, Macki M, Bydon M, Maleki Z, Bydon A. Midline synovial and ganglion cysts causing neurogenic claudication. *World J Clin Cases.* 2013;1:285–9.