

Symptomatic Ribbing's disease

M. Matas, L. Torrededia and O. Via-Dufresne

Department of Orthopedic and Trauma Surgery. Germans Trias i Pujol University Hospital. Badalona. Barcelona. Spain.

Symptomatic Ribbing disease

Introduction. Ribbing disease is a sclerosing bone dysplasia that is rarely symptomatic. This condition is diagnosed by exclusion, and the most effective surgical treatment is intramedullary reaming.

Case report. A forty eight year-old woman presented with a seven-month history of pain in the lower left extremity. Plain films showed a sclerotic area in the mid tibial shaft. CT scan revealed endosteal and cortical thickening with narrowing of the medullary canal. MRI did not show involvement of the surrounding soft tissues and technetium 99m bone scanning showed high uptake at the level of the lesion. Histological examination of a tibial cortex sample obtained by incisional biopsy revealed an area of new bone formation with non specific changes excluding neoplastic or infectious causes. The patient was diagnosed with Ribbing Disease and treated by intramedullary tibial reaming. The pain subsided immediately.

Conclusion. Ribbing disease is a rare condition where relevant clinical information combined with imaging and histological evaluation are critical diagnostic tools.

Key words: Ribbing disease, multiple diaphyseal sclerosis, endosteal sclerosis periosteal sclerosis.

Introducción. La enfermedad de Ribbing es una displasia ósea esclerosante que raramente es sintomática. Se diagnostica por exclusión y el tratamiento quirúrgico mediante fresado endomedular es el más efectivo.

Caso clínico. Mujer de 48 años de edad con clínica de dolor en la pierna izquierda de 7 meses de evolución. En la radiografía se apreciaba una lesión esclerosa en el centro de la diáfisis. La tomografía computarizada mostraba esclerosis endomedular y periosteal con obliteración del canal medular; en la resonancia magnética no se apreciaba afectación de partes blandas y en la gammagrafía ósea se observó hiper captación al nivel de la lesión. El estudio anatomopatológico de la biopsia incisional mostraba cambios inespecíficos y descartó patología neoplásica o infecciosa. Se diagnosticó enfermedad de Ribbing y la paciente fue tratada mediante fresado endomedular. El dolor mejoró inmediatamente.

Conclusiones. La enfermedad de Ribbing es una entidad poco frecuente en la que una buena historia clínica y familiar, un estudio iconográfico exhaustivo y la histología pueden ayudar a su diagnóstico.

Palabras clave: enfermedad de Ribbing, esclerosis diafisaria múltiple, esclerosis endostal, esclerosis periosteal.

Ribbing's disease is a rare form of sclerosing bone dysplasia, characterized by the exuberant yet benign formation of endosteal and periosteal bone in the shaft of long bones, particularly the tibia and the femur.

Although rarely symptomatic, it can cause pain and numbness in the affected limb. Pain is of an inflammatory

nature, appears progressively and seldom disappears with conventional pain killers or anti-inflammatory drugs.

We present the clinical case of a patient who reports pain in the left leg that developed over the past 7 months. Clinically and radiologically, the signs present are characteristic of the typical chronology of Ribbing's disease.

Corresponding author:

M. Matas Pareja.
Ctra. del Canyet s/n.
08916 Badalona. Barcelona. Spain
E-mail: 37168mmp@comb.es

Received: February 2006

Accepted: April 2007.

CASE REPORT

The patient is a 48-year-old female, referred to our Department because she had been suffering from pain in the left leg for the past 7 months; she reported no previous trauma.

ma. The pain, which had appeared gradually, was constant, profound and of variable intensity; it became worse during the night and affected the patient's night-time sleep. Although it was not a typically mechanical pain, the patient reported that on some occasions it got more acute after taking physical exercise.

The physical examination revealed an antalgic limp.

No deformity was observed in the affected limb and the patient was fever-free. On palpation, an increase in the temperature of the mid-tibial shaft (*vis-à-vis* the contralateral leg) was perceived, but no erythema or numbness were observed; palpation of the area was not painful.

The patient presented with good distal trophism with pulses symmetrical to those of the contralateral limb. She did not reveal alterations in sensitivity and the muscle balance of the affected limb was within normal values.

The anteroposterior and profile radiographs of the left tibia showed a thickening of the intramedullary cortex, with a slight enlargement of the periosteal cortex in the mid-tibial shaft (fig. 1A). There was a longitudinal extension at the diaphyseal level. General analytical studies, including those with acute phase reactants, were within normal values. A bone scan was performed that showed an intense increase in uptake at the level of the lesion, indicating the presence of augmented osteoblastic activity (fig. 1B).

The computed axial tomography (CAT) showed endosteal sclerosis with obliteration of the medullary space and, to a lesser extent, periosteal sclerosis of the middle third of the tibia (fig. 1C). At the level of the mid-third of the fibula sclerosis (mainly of a periosteal kind) could be observed. A magnetic resonance imaging study (MRi) was performed, which showed sclerosis in the medullary cavity of the left tibia, with periosteal thickening and with no involvement of the surrounding soft tissues (fig. 1D).

In view of these complementary tests the conclusion was drawn that the patient presented with a (seemingly benign) sclerosis in the shaft of the tibia and the fibula that was compatible which was identified as Ribbing's disease (multiple diaphyseal sclerosis) as a first diagnostic option. An open incisional biopsy was carried out of the site. The pathological study showed cortical bone with an increase in the number of osteocytes per bone unit as well as a rise in the number of Haversian canals. There was also an increase in osteoblastic activity at the site with lack of bone resorption. All of this is compatible with a diagnosis of multiple diaphyseal sclerosis (Ribbing's disease). Subsequently, an endomedullary reaming of the tibia was performed through the sclerosed area until the patency of the tibial medullary canal was restored (fig. 2).

The patient's symptoms disappeared in the early post-operative period. At 5 years, and after several clinical and radiological follow-up sessions, the patient is asympto-

matic, with no radiological changes having occurred since the first post-op follow-up visit.

DISCUSSION

Ribbing's disease or familial multiple diaphyseal sclerosis was first described by Ribbing in 1949¹. According to Greenspan² it is one of several sclerosing bone dysplasias that affect intermembranous ossification. It has a recessive hereditary autonomic pattern characterized by sclerosis and hyperostosis of the shaft of long bones (tibia, femur, fibula and radius).

It affects mature bone structures, which means that symptoms start developing after puberty.

The natural history of the disease presents with great variability since there may be unilateral, bilateral (symmetrical or asymmetrical) or multifocal (typically of an asynchronous nature) involvement.

The disease is rarely accompanied by symptoms but if symptoms do occur they take the form of gradually intensifying pain that on some occasions can become unbearable. This pain has been attributed to factors like an increase in intraosseous pressure and the occurrence of a medullary infarction³.

Conventional radiographs may show sclerosis at the expense of a thickening of the endomedullary cortical and periosteal bone. After evaluating 6 patients with Irving's disease, Seeger et al⁴, show that the disease is circumscribed to the intermediate level of the affected shaft, which undergoes a spindle-shaped thickening.

Ribbing's disease is diagnosed by exclusion, so it will be necessary to make a differential diagnosis ruling out conditions that may be characterized by clinical, iconographic or even pathological similarities to Ribbing's disease.

Unilateral involvement must be distinguished from stress fractures, osteosarcoma, adamantinoma, fibrous dysplasia, histiocytosis, osteomyelitis, lymphoma, intramedullary sclerosis and melorheostosis.

If involvement is bilateral, one must rule out metastatic lesions, other bone dysplasias and metabolic and endocrine disorders. A good medical record can help rule out a stress fracture and the patient's family history can point in the direction of bone dysplasia.

Analytical tests can help differentiate Ribbing's disease from other pathologies: a hemogram with a normal leukocyte levels and acute phase reactants rules out systemic diseases (lymphoma) and osteomyelitis; a biochemical study can help diagnose metabolic and endocrine diseases (Ribbing's disease may at times present with elevated alkaline phosphatase^{5,6} levels). Imaging techniques can also be of use: a CT-scan aids in ruling out malignant lesions and osteoid osteoma; MRi is useful to detect malignant lesions involving the soft tissues; bone gammagraphy with tech-

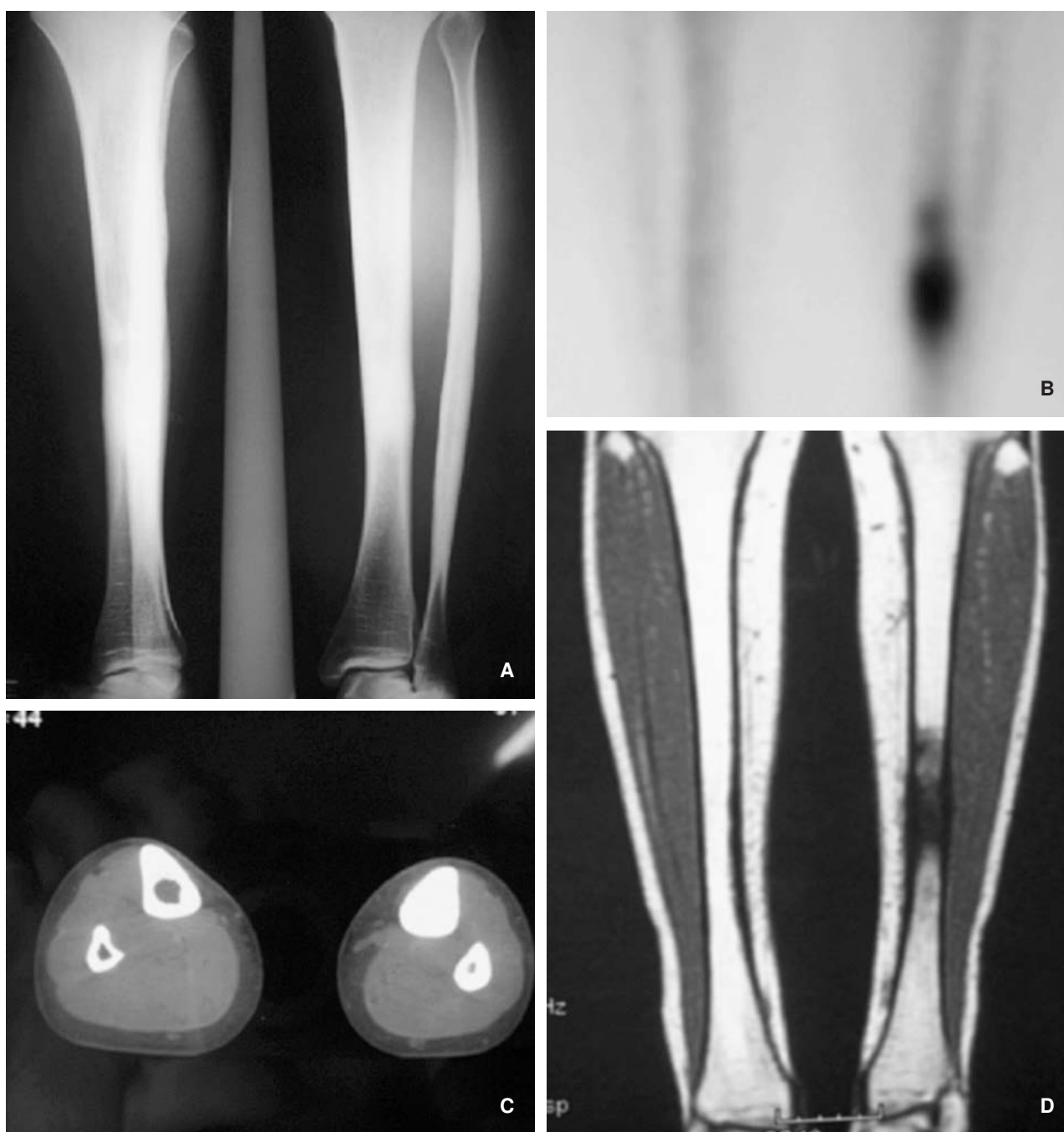


Figure 1. (A) Plain anteroposterior and lateral films of the left tibia and fibula showing the endomedullary cortical thickening (B) Bone gamma-graphy showing intensely increased uptake at the level of the lesion. (C) Computed tomography showing formation of new endomedullary bone that obliterates the medullary cavity. (D) Magnetic resonance image showing periosteal thickening with no involvement of the soft tissues.

netium can help rule out metastatic lesions and detect other diseased sites; bone gammagraphy with labeled leucocytes can help rule out osteomyelitis, but there are no data in the medical literature to justify the use of this test to diagnose Ribbing's disease.

There are two conditions that can sometimes be hard to distinguish from Ribbing's disease because of their clinico-

radiological similarities: intramedullary sclerosis (it has no hereditary pattern, it usually affects women, pain tends to be mechanical⁷ and does not present with periosteal sclerosis) and Camuratti-Engelmann's disease^{5,6,8} (of autosomal dominant inheritance, it appears during childhood, located in the metaphysis, its evolution is symmetrical, synchronous and progressive and can cause deformities, it sometimes af-

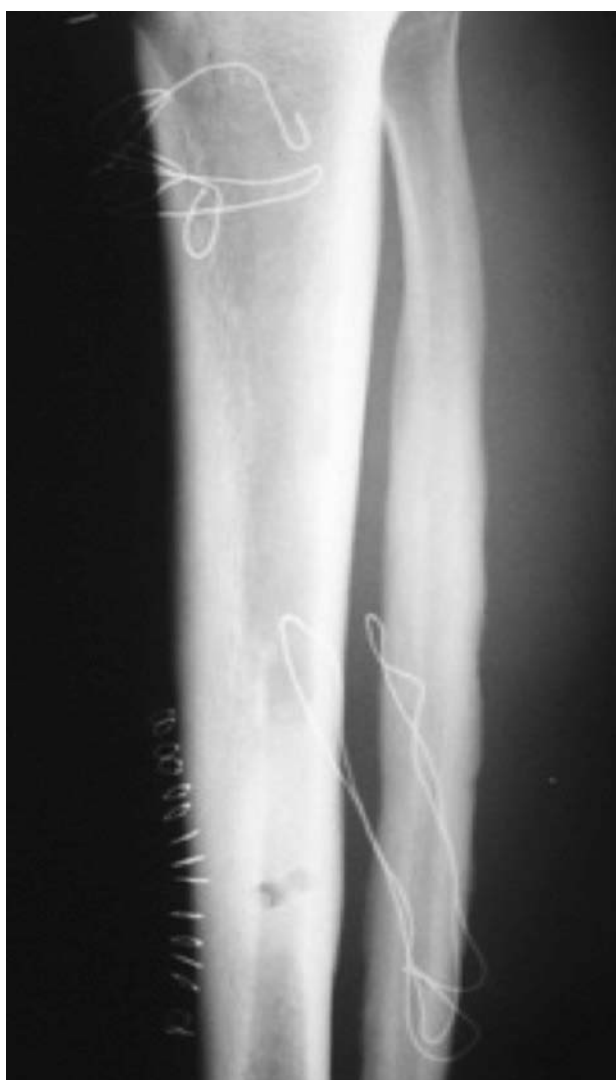

Figure 2. X-ray follow-up after reaming the intramedullary canal of the affected tibia.

fects the skull, mandible, vertebrae and upper limbs and pathological tests show bone resorption).

As regards the treatment of Ribbing's disease, there is a publication³ that shows the ineffectiveness of treatment with pamidronate. Other publications^{2,4} suggest intramedullary reaming as the method of choice to restore the medullary canal and therefore resolve the bone sclero-

sis. With these hypotheses, and in view of the good results obtained by these authors, it was decided to carry out an intramedullary reaming in our patient, which afforded her an excellent improvement as from the early post-op period.

In a nutshell, Ribbing's disease is a rare and scarcely symptomatic disease, characterized by both intramedullary and periosteal sclerosis, which must be suspected once other more prevalent conditions have been ruled out. It should be added that a full clinical history of the patient is essential as well as a correct iconographic interpretation in order to accurately diagnose this disease.

Intramedullary reaming is the treatment of choice to resolve the symptoms. Even if the disease evolves in a benign way, a clinical-radiological follow-up is necessary to detect sclerotic lesions in other parts of the body.

REFERENCES

1. Ribbing S. Hereditary, multiple diaphyseal sclerosis. *Acta Radiol.* 1949;31:522-36.
2. Greenspan A. Sclerosing bone dysplasias: A target-site approach. *Skeletal Radiol.* 1991;20:561-83.
3. Ziran N, Hill S, Kovacs J. Ribbing disease: radiographic and biochemical characterization, lack of response to pamidronate. *Skeletal Radiol.* 2002;31:714-9.
4. Seeger LL, Hewel KC, Yao L, Gold RH, Mirra JM, Chandnani VP, et al. Ribbing disease (multiple diaphyseal sclerosis): imaging and differential diagnosis. *AJR Am J Roentgenol.* 1996;167:689-94.
5. Shier CK, Krasicky GA, Ellis BI, Kottamasu SR. Ribbing's disease: Radiographic-scintigraphic correlation and comparative analysis with Engelmann's disease. *J Nucl Med.* 1987;28:244-8.
6. Beals RK, Pearson JM, Mansoor A. Ribbing disease: a case report. A review of the literature, and a description of novel treatment. *J Bone Joint Surg Am.* 2002;84A:2050-5.
7. Chanchairujira K, Chung CB, Man Lai Y, Haghighi P, Resnick D. Intramedullary osteosclerosis: imaging features in nine patients. *Radiology.* 2001;220:225-30.
8. Makita Y, Nishimura G, Ikegawa S. Intrafamilial phenotypic variability in Englemann disease (ED): Are ED and Ribbing disease the same entity? *Am J Med Genet.* 2000;91:153-6.

Conflict of interests

The authors have declared that they have no conflict of interests.