

## Multiple Biliary Hamartomas, The “Von Meyenburg Complexes”

Joel O. Jáquez-Quintana, Erick A. Reyes-Cabello, Francisco J. Bosques-Padilla

Gastroenterology Division, Hospital Universitario “Dr. José Eleuterio González”, Universidad Autónoma de Nuevo León, Monterrey, Mexico.

### ABSTRACT

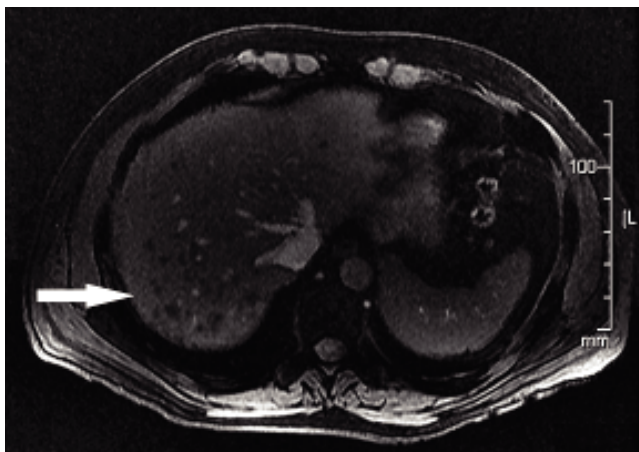
Multiple biliary hamartomas are rare benign malformations of the intrahepatic bile ducts first described by von Meyenburg in 1918. They originate from embryonic bile ducts that fail to involute. These are generally asymptomatic and usually encountered as an incidental finding at imaging, laparotomy or autopsy.

**Key words.** Liver. Liver cyst. Biliary tract. Intrahepatic cholangiocarcinoma. Magnetic resonance cholangiopancreatography.

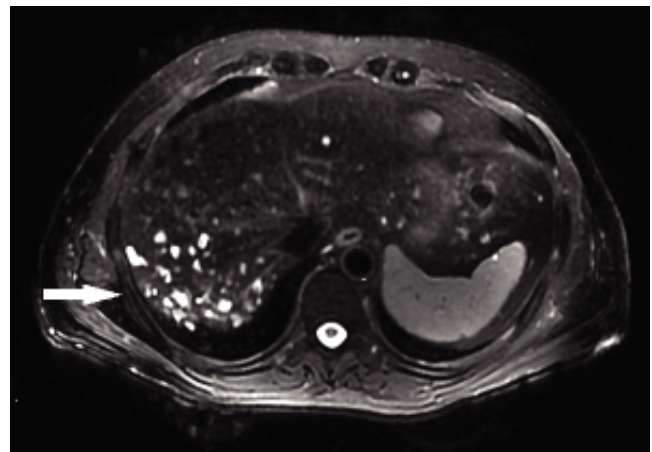
### CASE PRESENTATION

50-year-old man with no medical history was referred due to abnormal liver function tests. Aspartate aminotransferase was 61 IU/L (normal, 0 to 38) and gamma-glutamyl transpeptidase 90 IU/L (normal, 12 to 64). Abdominal ultrasound showed multiple hyper and hypoechoic areas in the

liver. Magnetic resonance cholangiopancreatography (MRCP) was also performed. A T1-weighted MR image (Figure 1) revealed multiple hypointense diffuse liver lesions of variable size (< 15 mm). A T2-weighted MR image (Figure 2) revealed these lesions as hyperintense, with MRCP (Figure 3) not showing communication between the cystic lesions and the biliary tract.



**Figure 1.** T1-weighted MR image reveals multiple hypointense lesions of the liver and of variable size.



**Figure 2.** T2-weighted MR image these lesions appear hyperintense (white arrows).



**Figure 3.** MRCP shows no communication of the lesions with the biliary duct.

## DISCUSSION

These findings were consistent with multiple biliary hamartomas or "von Meyenburg complexes",<sup>1,2</sup> which are a variety of benign cystic lesions of the liver that consist of focal collections of ductlike structures embedded in a fibrous stroma resulting from ductal plate malformation involving the small interlobular bile ducts.<sup>1</sup> Biliary hamartomas are rare, clinically asymptomatic, and diagnosis is usually incidental.<sup>1-3</sup> Technical advances in radiology have made them easily detectable, providing a more accurate diagnosis to avoid biopsy, which should be performed for confirmation of diagnosis when in doubt.<sup>3,4</sup> CT scans can detect multiple, nodular and irregular cystic liver lesions, smaller than 15 mm, with low attenuation and no enhancement on contrast injection.<sup>5,6</sup> MRCP can also help in the differentiation of von Meyenburg complexes from liver metastases, polycystic disease and Caroli's disease,<sup>2</sup> requiring the administration of intravenous gadolinium. Contrast enhancement is seen in metastatic lesions and Caroli's disease,<sup>6</sup> and a lack of communication with the biliary tree can be observed in the latter.<sup>4</sup> Even though prevalence of this entity has been reported to be low at autopsy, ranging from 0.69% and as high as 5.6%,<sup>5,7</sup> when its diagnosed patients require monitoring because some reports have shown malignant transformation to intrahepatic cholangiocarcinoma.<sup>6-8</sup> The use of Ca 19-9 to diagnose malignant transformation should be discouraged, since per-

sistent elevation of this tumor marker has been described in patients with multiple biliary hamartomas without malignancy.<sup>9,10</sup>

We suggest periodic clinical monitoring and determination of Ca 19-9, and in case of alarm symptoms or elevation of tumor marker, perform MRCP with gadolinium. If a suspicious lesion is found, consider confirming diagnosis with a biopsy.

## CONFLICT OF INTEREST

No conflict of interest statement.

## REFERENCES

- Tohmé-Noun C, Cazals D, Noun R, Menassa L, Valla D, Vilgrain V. Multiple biliary hamartomas: magnetic resonance features with histopathologic correlation. *Eur Radiol* 2008; 18: 493-9.
- Mortelé KJ, Ros PR. Cystic focal liver lesions in the adult: differential CT and MR imaging features. *Radiographics* 2001; 21: 895-910.
- Quentin M, Scherer A. The "von Meyenburg Complex". *Hepatology* 2010; 52: 1167-8.
- Davidoff S, Kim S, Friedman B. Von Meyenburg Complexes (Bile duct hamartomas). *Clin Gastroenterol Hepatol* 2006; 4: xxvi.
- Spiller R. Multiple cystic liver lesions on CT. *Gut* 2008; 57: 144.
- Hain D, Ahrens W, Finkelstein S. Molecular evidence for the neoplastic potential of Hepatic Von-Meyenburg Complexes. *Appl Immunohistochem Mol Morphol* 2010; 18: 166-71.
- Parekh V, Peker D. Malignant transformation in Von-Meyenburg complexes: Histologic and immunohistochemical clues with illustrative cases. *Appl Immunohistochem Mol Morphol* 2015; 23: 607-14.
- Xu AM, Xian ZH, Zhang SH, Chen XF. Intrahepatic cholangiocarcinoma arising in multiple bile duct hamartomas: report of two cases and review of the literature. *Eur J Gastroenterol Hepatol* 2009; 21: 580-4.
- Souza-Gallardo LM, de la Fuente-Lira M, Galaso-Trujillo R, Martínez-Ordaz JL. Elevación persistente de Ca 19-9 y un hallazgo inesperado. Reporte de un caso. *Cirugía y Cirujanos* 2016; Epub.
- Morinaga T, Katsunoria I, Yamashitaa YI, Yamaoa T, Kaidaa T, Nakagawaa S, Hashimoto D, et al. Multicystic biliary hamartoma with extremely elevated CA 19-9: a case report. *Scand J Gastroenterol* 2017; 52: 916-9.

### Correspondence and reprint request:

Francisco J. Bosques-Padilla, M.D.  
Gastroenterology Division, "Dr. Jose E. Gonzalez" University Hospital, Universidad Autónoma de Nuevo León.  
Av. Madero y Gonzalitos, s/n, Col. Mitras Centro, Monterrey, Nuevo León, 64460, Mexico.  
Tel.: +52 (81) 8333-3664. Fax: +52 (81) 8348-6068  
E-mail: fbosques58@hotmail.com