



## CASE REPORT

### Tuberculous aortitis, a case report



Viviana Manuel\*, José Tiago, Pedro Martins, Carlos Martins, José Silva Nunes, José Fernandes e Fernandes

*Clínica Universitária de Cirurgia Vascular, Centro Hospitalar Lisboa Norte, Lisboa, Portugal*

Received 26 January 2015; accepted 18 May 2015

Available online 22 November 2015

#### KEYWORDS

Tuberculosis;  
Conventional repair;  
Mycotic aneurysm

#### PALAVRAS-CHAVE

Tuberculose;  
Cirurgia convencional;  
Aneurisma micótico

#### Abstract

*Introduction:* Tuberculous aortitis is a rare entity first described by Weigert in 1882.

*Report:* A 73-year-old male under regular imagiologic surveillance due to a 4 cm abdominal aortic aneurysm, was referred to our department for suspected contained rupture. He was asymptomatic and his CT scan showed an inflammatory mass surrounding the aneurysm. During elective conventional surgery, aneurysm wall infiltration and adenopathies were identified. The histological analysis was compatible with tuberculosis. Eight months after surgery the patient is well, under tuberculostatic therapy.

*Conclusion:* The combination of surgical treatment and long duration tuberculostatic therapy is the best treatment option for tuberculous aortitis.

© 2015 Sociedade Portuguesa de Angiologia e Cirurgia Vascular. Published by Elsevier España, S.L.U. This is an open access article under the CC BY-NC-ND license (<http://creativecommons.org/licenses/by-nc-nd/4.0/>).

#### Aortite tuberculosa, um caso clínico

#### Resumo

*Introdução:* A aortite tuberculosa é uma entidade rara inicialmente descrita por Weigert em 1882.

*Report:* Um homem de 73 anos, sob controlo imagiológico regular por aneurisma da aorta abdominal de 4 cm de diâmetro, foi referenciado ao Departamento por suspeita de ruptura contida. O doente estava assintomático e a Angio-TC evidenciava uma massa inflamatória envolvendo o aneurisma. Durante a cirurgia electiva convencional, infiltração da parede do aneurisma e adenopatias foram identificadas. A análise histológica era compatível com tuberculose. Oito meses após a cirurgia, o doente encontra-se estável e sob terapêutica tuberculostática.

\* Corresponding author.

E-mail address: [viv\\_manuel@hotmail.com](mailto:viv_manuel@hotmail.com) (V. Manuel).

<http://dx.doi.org/10.1016/j.ancv.2015.05.006>

1646-706X/© 2015 Sociedade Portuguesa de Angiologia e Cirurgia Vascular. Published by Elsevier España, S.L.U. This is an open access article under the CC BY-NC-ND license (<http://creativecommons.org/licenses/by-nc-nd/4.0/>).

**Conclusão:** A associação entre tratamento cirúrgico e terapêutica tuberculostática de longa duração é a melhor opção terapêutica para os casos de aortite tuberculosa.

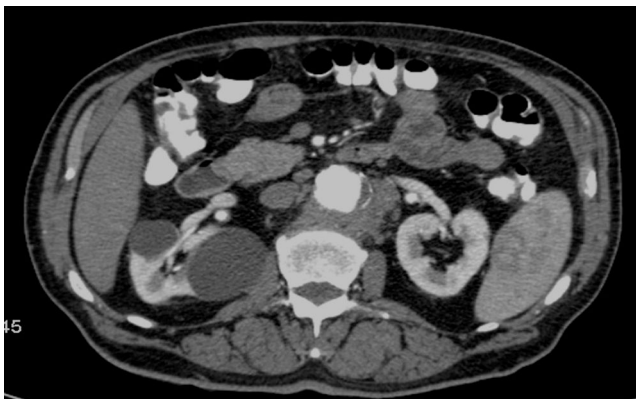© 2015 Sociedade Portuguesa de Angiologia e Cirurgia Vascular. Publicado por Elsevier España, S.L.U. Este é um artigo Open Access sob uma licença CC BY-NC-ND (<http://creativecommons.org/licenses/by-nc-nd/4.0/>).

## Introduction

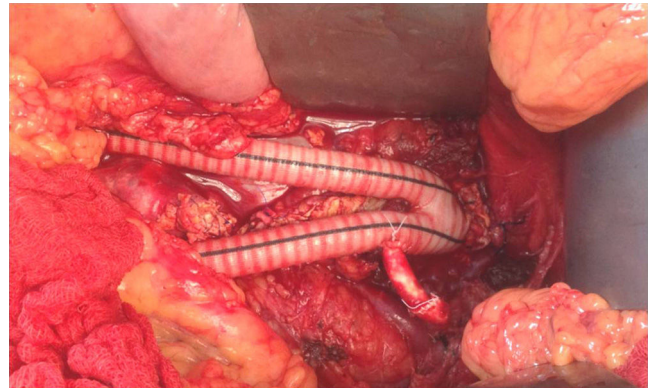
Tuberculous aortitis was first described by Weigert in 1882<sup>1</sup> and constitutes an extremely rare entity, with less than 100 reported cases, but fatal if undiagnosed.

## Case report

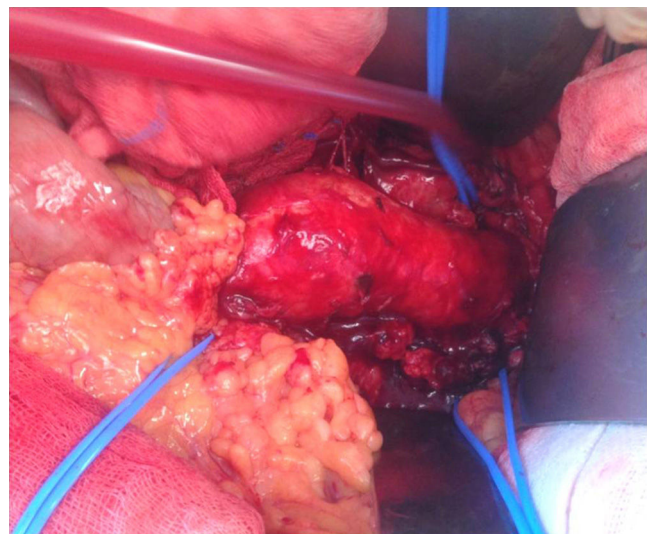
A 73 year old male, with smoking habits, ischemic cardiopathy and hypertension, was the subject of regular imagiologic surveillance due to a 4cm pararenal abdominal aortic aneurysm. He was taken to the emergency department after routine CT examination for suspected contained aneurysm rupture. The Angio-CT was repeated and an inflammatory mass surrounding the aneurysm was identified, which enclosed the left renal artery ostium, without any signs of rupture (Fig. 1). This inflammatory mass was not described in the previous CT scans the patient had been submitted to. The patient denied previous Tuberculosis infection as well as having had fever, shivers or abdominal pain prior to admittance, referring a 10 kg weight loss during the previous year. The laboratory analysis did not present any relevant changes or increased inflammatory parameters and the blood cultures and serologies were negative. He was submitted to elective surgery. Under supra-renal clamping the aneurysm was partially resected and, using a bifurcated Dacron graft, an aorto-bifemoral interposition and a bypass to the left renal artery done (Fig. 2). The aneurysm's intraoperative appearance was that of an inflammatory aneurysm (Fig. 3), no abscess or fluid collection was



**Figure 1** Pre-operative CT scan showing an inflammatory mass surrounding the aneurysm and enclosing the left renal artery's ostium.

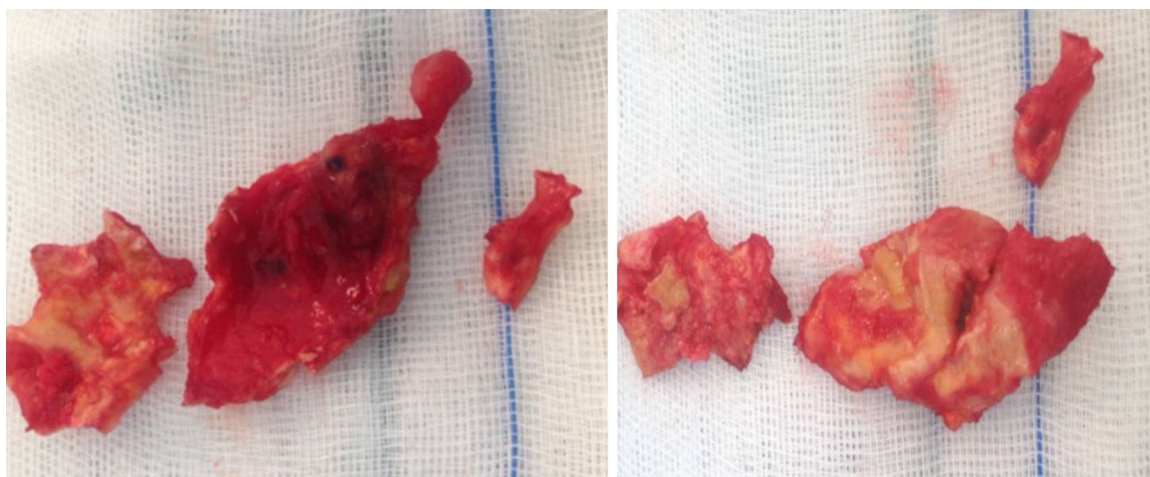

**Figure 2** After partial aneurysm resection, using a bifurcated Dacron graft, an aorto-bifemoral interposition and a bypass to the left renal artery were accomplished.



**Figure 3** Intra-operative appearance, compatible with an inflammatory aneurysm. The inflammatory mass involved the left renal artery and grayish adenopathies were evident. The left renal artery, the right renal artery and the inferior mesenteric artery were isolated and identified by a blue Silastic® band.

identified. Several tissue samples were sent to histopathological analysis (Fig. 4), including aneurysm wall fragments which had been infiltrated by the inflammatory mass and grayish adenopathies. The patient was discharged 8 days after the surgery, without any complications having taken



**Figure 4** Gross appearance of some of the aneurysm wall fragments sent to histopathological analysis, infiltration of the aneurysm wall by the inflammatory mass is visible.

place. The histological analysis of the samples revealed aspects compatible with tuberculosis (acid and alcohol-fast bacilli were not identified), the patient was referred to the Pneumologic Diagnostic Center and is at the moment under tuberculostatic therapy, doing well at eight months follow-up.

## Discussion

The majority of tuberculous mycotic aneurysms are saccular (98%) and false (88%), and the aorta is the most frequently affected vessel, being the abdominal and the descending thoracic locations preferential.<sup>1</sup> The size of the aneurysm does not dictate the need for surgery as the rate of the destruction of the aortic wall is unpredictable.<sup>1,2</sup>

Most tuberculous aortitis occurs due to direct extension of the infection from a contiguous focus, either lymph node, paraspinal abscess or adjacent organ tissue; direct implantation of circulating bacilli on the vessel's wall is another possible mechanism. Identifying the precursor event, either the aortitis or the adjoining infected tissue, especially when tuberculosis lymphadenitis is present, is challenging.<sup>1</sup> What distinguishes our patient from the previous case studies is the fact that it is the first report, to our knowledge, of tuberculosis infection of a preexisting aortic aneurysm.

In the long series, over one third of patients did not have a tuberculosis diagnosis before surgery. A high suspicion rate is therefore mandatory, especially in an era of increasing immunocompromised conditions which might lead to an increase of this life-threatening condition.<sup>3</sup> As it is a rare entity, the recognition of tuberculous mycotic aneurysm is problematic. The possibility of a tuberculosis infection may not have been anticipated, the intra-operative appearance of the aneurysm could be uncharacteristic and the surgical decision process is in many instances that of an inflammatory aneurysm or a mycotic aneurysm caused by a more common pathogen,<sup>1</sup> as in our case.

The treatment for tuberculous aortitis must be an association of medical and surgical therapy, as no patients survived with either of them on its own.<sup>1</sup> Surgical therapy allows for

debridement and excision of the infected tissues, improving antimycobacterial action, and should be the first choice if allowed by the patient's condition. A few reports of endovascular therapy have emerged, in patients with high surgical risk, with mixed results.<sup>4</sup> Controversy exists, however, on the duration of medical treatment, some authors defend long duration, or even lifelong tuberculostatic treatment, to prevent prosthetic infection and the development of false anastomotic aneurysms.<sup>5</sup> In fact, leaving a vascular prosthesis on a potentially infected field does not seem to adversely outcome as long as medical treatment is maintained; the cases of aortic rupture after treatment reported happened after tuberculostatic drugs had been suspended.<sup>3-5</sup> The initial antituberculous therapy regimen should last for no less than 9–12 months. The decision of performing a long term antimicrobial treatment, as well as the drug combination and its duration, should be taken bearing in mind the presence of in situ prosthetic aortic graft, as well as the pattern of tuberculostatic resistance identified on the cultures.<sup>2,3</sup>

## Conclusion

Tuberculous mycotic aneurysms are very rare and the combination of surgical treatment and long duration tuberculostatic therapy is the best treatment option, with the best long term results.<sup>1,3</sup>

## Ethical disclosures

**Protection of human and animal subjects.** The authors declare that no experiments were performed on humans or animals for this study.

**Confidentiality of data.** The authors declare that no patient data appear in this article.

**Right to privacy and informed consent.** The authors declare that no patient data appear in this article.

## Conflicts of interest

The authors have no conflicts of interest to declare.

## References

1. Long R, Guzman R, Greenberg H, et al. Tuberculous mycotic aneurysm of the aorta: review of published medical and surgical experience. *Chest*. 1999;115(2):522–31.
2. Pierret C, Tourtier JP, Grand B, et al. Multiple tuberculous aneurysms of the aorta. *J Vasc Surg*. 2011;53:1720–2.
3. Canaud L, Marzelle J, Bassinet L, et al. Tuberculous aneurysms of the abdominal aorta. *J Vasc Surg*. 2008;48:1012–6.
4. Clough RE, Topple JA, Zayed HA, et al. Endovascular repair of a tuberculous mycotic thoracic aortic aneurysm with a custom-made device. *J Vasc Surg*. 2010;51:1272–5.
5. Lambrouse L, Montaudon M, Le Guyader A, et al. Endovascular treatment of a tuberculous infected aneurysm of the descending thoracic aorta: a word of caution. *J Vasc Surg*. 2007;46:786–8.