

Case report

Ruptured mycotic aneurysm of the common femoral artery complicating a mitral valve infective endocarditis

Assia Elouardi^{a,b,*}, Samir Elyoubi^{b,c}, Emmanuel Kibassim^{a,b}, Anas Elhafidi^{a,b}, Salah Eddine Boulmakoul^{a,b}, Amine Majdoub^{a,b}, Mohammed Messouak^{a,b}^a Cardiovascular Surgery Department, Hassan II University Hospital, Fez, Morocco^b Faculty of Medicine and Pharmacy, Sidi Mohamed Ben Abdellah University, Fez, Morocco^c Vascular Surgery Department, Hassan II University Hospital, Fez, Morocco

ARTICLE INFO

Article history:

Received 27 September 2021

Accepted 1 December 2021

Keywords:

Mycotic aneurysm

Infective endocarditis

Mitral valve replacement

Femoral artery

Palabras clave:

Aneurisma micótico

Endocarditis infecciosa

Reemplazo de válvula mitral

Arteria femoral

ABSTRACT

Ruptured mycotic aneurysm following infective endocarditis is rare, but remains a life-threatening condition. We report a case of surgical management of a ruptured mycotic aneurysm of the common femoral artery, complicating mitral valve endocarditis with heart failure in a twenty-nine-year-old female who underwent a prosthetic mitral valve replacement and an in situ successful reconstruction using reversed saphenous vein graft. The patient recovered uneventfully and was found in good condition as a three-year follow-up.

© 2022 Published by Elsevier España, S.L.U. on behalf of Sociedad Española de Cirugía Cardiovascular y Endovascular. This is an open access article under the CC BY-NC-ND license (<http://creativecommons.org/licenses/by-nc-nd/4.0/>).

Endocarditis infecciosa de la válvula mitral complicada por la rotura de un aneurisma micótico de la arteria femoral común

RESUMEN

El aneurisma micótico roto después de una endocarditis infecciosa es raro, pero sigue siendo una afección potencialmente mortal. Presentamos el caso de manejo quirúrgico de un aneurisma micótico roto de la arteria femoral común, que complica la endocarditis de la válvula mitral con insuficiencia cardíaca en una mujer de 29 años, a la que se le realizó un reemplazo valvular mitral y una reconstrucción exitosa *in situ*, utilizando injerto de vena safena. El paciente se recuperó sin incidentes y se encontró en buenas condiciones a los tres años de seguimiento.

© 2022 Publicado por Elsevier España, S.L.U. en nombre de Sociedad Española de Cirugía Cardiovascular y Endovascular. Este es un artículo Open Access bajo la licencia CC BY-NC-ND (<http://creativecommons.org/licenses/by-nc-nd/4.0/>).

Introduction

The development of peripheral mycotic aneurysms and subsequent rupture was a common occurrence in the preantibiotic era. The first complete description of mycotic aneurysm was presented in 1885 by Sir William Osler, in a 30-year-old man with four aneurysms of the aortic arch, arising as a complication of endocarditis. It is a serious, clinical condition with significant morbidity and mortality rates. Mycotic aneurysms of the femoral artery are a rarity, accounting for merely 0.8% of all aneurysms. We report a case of surgical management of a ruptured mycotic aneurysm complicating mitral valve endocarditis.

Case report

A 29 years old lady, with known rheumatic disease, previously diagnosed to have mitral valve prolapse, was admitted to the emergency department with a two-months history of fever,

night sweats, increasing breathlessness, and weight loss over three months. The patient also reported a pulsatile, painful swelling in the right thigh. On examination her temperature was 39 °C, heart rate 110 beats/min and blood pressure 102/60 mmHg. Auscultation of her chest revealed bibasilar crepitations and a 4/6 pan-systolic murmur was heard best at the apex radiating to the axilla. There was also a large pulsating mass in the anteromedial right thigh. Blood tests showed anemia (hemoglobin 10 g/dl), mild neutrophil leukocytosis (white cell count 12.5 10⁹/L), and raised C-reactive protein (178 mg/L) with normal electrolytes, blood cultures were found positive for *Staphylococcus Hominis*. Transthoracic echocardiography revealed a bright echogenic mobile mass on the mitral valve measuring 21 mm on the atrial side of the anterior mitral valve, several other small vegetations were evident on the posterior mitral valve with severe mitral regurgitation and elevated pulmonary artery systolic pressure. Color doppler ultrasound was performed and showed a thrombosed aneurysm of the common femoral artery. Appropriate intravenous antibiotic therapy was initiated and given the severity of endocarditis and cardiac failure, the patient underwent first an emergency prosthetic mitral valve replacement with a 31-mm SJM valve under standard car-

* Corresponding author.

E-mail address: Dr.elouardi.assia@gmail.com (A. Elouardi).

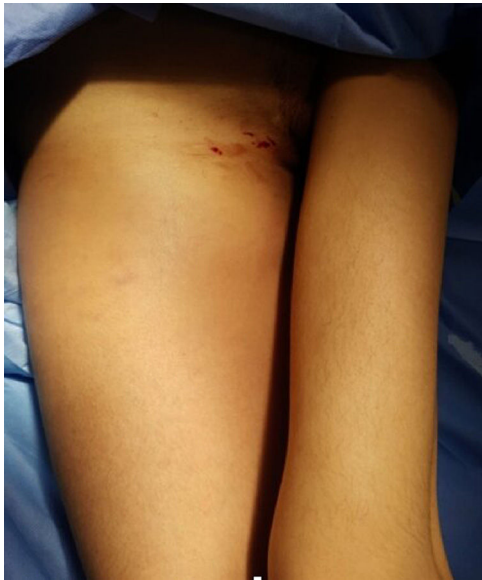

Fig. 1. Clinical photograph of the patient showing visible swelling in the anterior and medial aspect of her right thigh up to the groin.

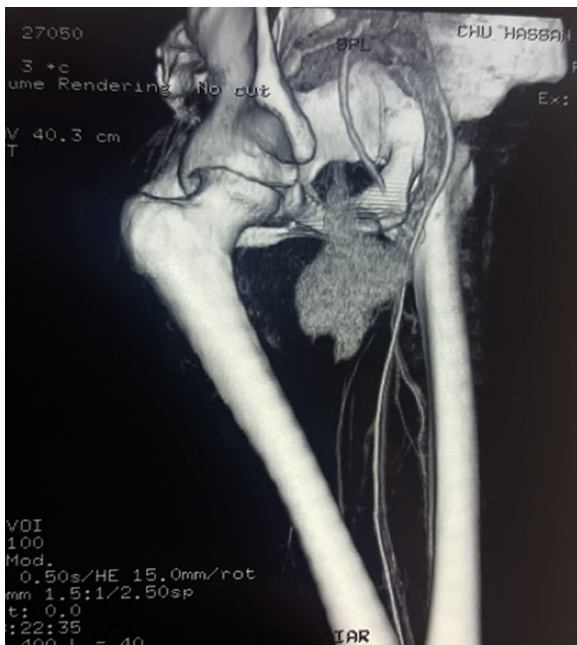


Fig. 2. CT scan with tridimensional reconstruction showing an aneurysmatic sacular formation in the dependence of the right common femoral artery.

diopulmonary bypass. The postoperative course was uneventful, the fevers remitted, but the white blood cell/C-reactive protein (WBC/CRP) count elevated, with a continuous complaint of right thigh pain and numbness. On the 4th day after MVR, the patient experienced acute pain and a marked increase in the thigh swelling (Fig. 1), contrast-enhanced CT scan showed acute expansion of the common femoral aneurysm with evidence for contained rupture (Fig. 2). Under general anesthesia, the patient underwent an emergency exploratory surgery of the right lower limb. There was a large-volume hematoma related to the ruptured aneurysm of the common femoral artery (Fig. 3). The aneurysm was resected and the vascular segment reconstructed by reversed interposition of a segment of the ipsilateral saphenous vein (Fig. 4). The postoperative course was uneventful and other laboratory data

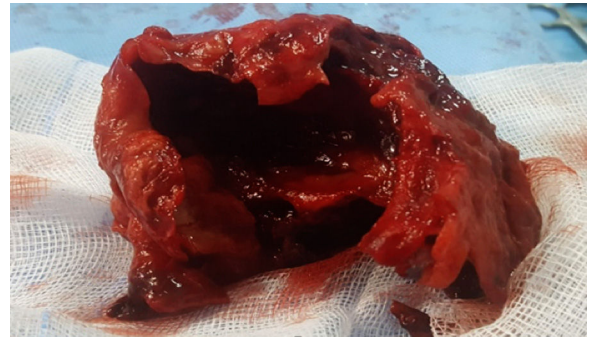


Fig. 3. Perioperative view of a large thrombus removed at surgery.

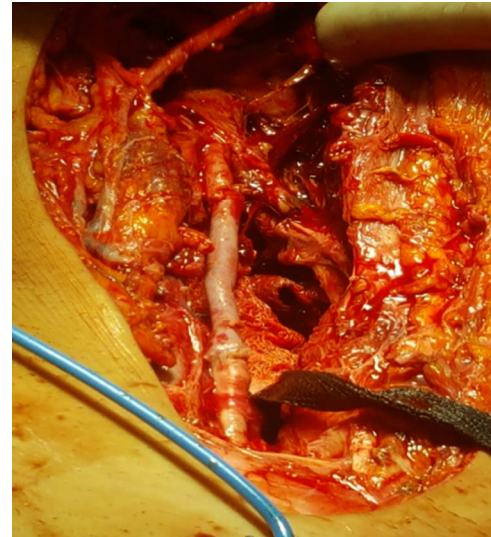


Fig. 4. Perioperative view showing the reversed saphenous vein bypass graft of the femoral artery.

immediately normalized. Microbiology tests on the aneurysm sac were negative with no germ growth on culture. On histopathology, the artery wall was disrupted and replaced by fibrin and thrombus. The patient progressed well and was discharged on the fifth postoperative day. There was no recurrence of infection, and the graft remains patent.

Discussion

Despite improvement in treatment of infective endocarditis (IE), the complications are frequently seen. The complications of IE consist of neurological vascular complications (45.5%) and peripheral vascular complications (myocardial infarction, pulmonary embolism, splenic infarction, acute limb ischemia, gangrene) that are mainly the consequence of emboli from valve vegetations, which are life threatening and debilitating. However, 20% of embolisms are asymptomatic.¹ Mycotic aneurysms (MA) are rarely seen and defined as localized, irreversible vascular dilatations caused by weakening and destruction of the vessel wall by an invasive organism establishing an infective arteritis. In 1885, Sir William Osler described the first infected aneurysm of the aorta complicating bacterial endocarditis.² The term 'mycotic' derives from the mushroom-like appearance of the aneurysms originally described, and not their underlying microbiological etiology.² Endarterial infection may arise through hematogenous seeding from distant septic foci either direct to the arterial intima or to deeper mural layers via the vasa vasorum. Currently, the inci-

dence of these aneurysms following an episode of endocarditis is quite rare, and their location is dependent upon the peripheral lodgment site of mycotic emboli. Peripheral embolic events usually involve the lower extremities with most emboli lodging at the common femoral artery bifurcation followed by the abdominal and thoracic aorta. MA of intracranial vessels are uncommon and visceral arteries are extremely rare.³ Fever, painful pulsatile mass with palpable thrill and local inflammatory changes are the most clinical findings of physical examination.^{4,5} The most frequently involved bacteria are *Staphylococcus*, *Streptococcus*, *Pneumococcus* and *Pseudomonas aeruginosa* however negative hemocultures are seen relatively high (25%). Transthoracic and transesophageal echocardiography are used for the prediction of embolisms. The size and mobility of vegetations are predictive factors of embolisms.¹ In the literature, the most often reported MA diagnostic tool is angiography.⁶ Computed tomographic angiography is an accurate and effective diagnostic method for tracking size, configuration, and extravasation of blood into the soft tissue of the thigh. Ultrasound is considered a better test to precisely determine aneurysm diameter.⁷ MRI can be of diagnostic utility or of discriminatory value when other tests are inconclusive.⁸ The natural history of untreated mycotic aneurysms is of fatality from either massive hemorrhage or fulminant sepsis.⁹ Manifestations of aneurysm expansion correlate with anatomical location. Although occurring as late as complications in terms of the natural history, up to 45% rupture, with fistula formation in 18%.⁹ Management of MA is less clear because of paucity of cases reported in the literature, in general, the standard therapy includes early antibiotic use, which should be based on appropriate guidelines, valve surgery and/or complete excision of infective tissues. Surgical treatment of MA is directed to control hemorrhage. Debridement of all infected tissue and restoration of circulation is the subsequent aim. Hemorrhage can be controlled by clamping the vessel proximally and distally. Debridement should include evacuation of infected hematoma and excision of all necrotic tissues, which usually includes the arterial wall itself. Restoration of circulation in such cases is typically achieved with bypass grafting using autogenous vein. Endovascular options such as coil embolization/thrombin glue injection, stenting appear attractive alternatives to surgery.¹⁰ We did not consider them in our case, as the patient had signs of compartmental compression due to the large thigh hematoma. Additionally, the evidence of such interventions in mycotic aneurysms is limited.

Conclusion

Mycotic aneurysms are a serious clinical condition that are associated with significant morbidity and mortality. They may be prevented with an early and appropriate management of IE but once diagnosed they should be treated surgically. Even if Antibiotics may control sepsis, they do not reduce risk of rupture of the weakened vessel wall.

Informed consent

Verbal and written informed consent were obtained from the patient for the publication of this case report.

Conflicts of interests

The authors declare that there is no conflict of interest regarding the publication of this paper.

References

1. Serkan BD, Mustafa KD. Infective endocarditis and incidental popliteal artery mycotic aneurysm. *Cor Vasa*. 2017;59:291–3.
2. Osler WITH. The Gulstonian Lectures, on malignant endocarditis. *Br Med J*. 1885;7:467–70.
3. Lee WK, Mossop PJ, Little AF, Fitt GJ, Vrazas JJ, Hoang JK, et al. Infected (mycotic) aneurysms: spectrum of imaging appearances and management. *Radiographics*. 2008;28:1853–68.
4. Tsao JW, Marder SR, Goldstone J, Bloom AI. Presentation, diagnosis, and management of arterial mycotic pseudoaneurysms in injection drug users. *Ann Vasc Surg*. 2002;16:652–62.
5. Patra P, Ricco JB, Costargent A, Goueffic Y, Pillet JC, Chaillou P. Infected aneurysms of neck and limb arteries: a retrospective multicenter study. *Ann Vasc Surg*. 2001;15:197–205.
6. Leon L Jr, Taylor Z, Psalms SB, Mills J Sr. Degenerative aneurysms of the superficial femoral artery. *Eur J Vasc Endovasc Surg*. 2008;35:332–40.
7. Piffaretti G, Mariscalco G, Tozzi M, Rivolta N, Annoni M, Castelli P. Twenty-year experience of femoral artery aneurysms. *J Vasc Surg*. 2011;53:1230–6.
8. Dobritz M, Lang W, Fellner FA. MR diagnosis of superficial femoral artery aneurysm, primarily misdiagnosed as soft tissue tumor. A case report. *Magn Reson Imaging*. 2003;21:687–90.
9. Muller BT, Wegener OR, Grabitz K, Pillny M, Thomas L, Sandmann W. Mycotic aneurysms of the thoracic and abdominal aorta and iliac arteries: experience with anatomic and extra-anatomic repair in 33 cases. *J Vasc Surg*. 2001;33:106–13.
10. Gandhi V, Shyam V, Unnikrishnan G, Balakrishnan D, Sudhindran S. Ruptured mycotic aneurysm of peroneal artery. *EJVES Extra*. 2005;10:21–3.



BIOMED



unidix

Especialistas en cirugía cardiovascular

desde 1977 al cuidado de tu salud



91 803 28 02



info@biomed.es