



## Note

# Cutaneous fusariosis by a species of the *Fusarium dimerum* species complex in a patient with acute myeloblastic leukemia

Carmen Collado<sup>a</sup>, Laura Medina<sup>a</sup>, Alfredo Zorraquino<sup>a</sup>, Teresa Baeza<sup>a</sup>, Consuelo Ferrer<sup>b</sup>, Joaquín Plazas<sup>a</sup>, María Francisca Colom<sup>c,\*</sup>

<sup>a</sup> Servicio de Microbiología, Hospital General Universitario de Alicante, Alicante, Spain

<sup>b</sup> Vissum Corporation, I+D+i Department, Spain

<sup>c</sup> Universidad Miguel Hernández, Medical Mycology Laboratory, Alicante, Spain

## ARTICLE INFO

### Article history:

Received 11 August 2012

Accepted 5 November 2012

Available online 20 November 2012

### Keywords:

Opportunistic mycosis

Fusariosis

*Fusarium dimerum*

## ABSTRACT

**Background:** Fusariosis is an emergent opportunistic hyalohyphomycosis produced by fungi belonging to the genus *Fusarium*. These molds are capable of producing life-threatening diseases in immunocompromised hosts, especially in those suffering from leukemia. It has also been described in immunocompetent patients, where it usually causes non-invasive localized lesions. Fusariosis in immunocompromised individuals has a high morbidity and mortality mainly because of the low sensitivity of these fungi to the antifungal drugs available.

**Case report:** We describe here the case of a patient with acute myeloblastic leukemia who developed fusariosis by a species of the *Fusarium dimerum* species complex. The early diagnosis was made on the basis of microscopic observation of samples from cutaneous lesions, and voriconazole treatment was prescribed. A subsequent complete study of the fungal isolate by culture and molecular methods allowed the identification of *F. dimerum*, a species rarely described as a human pathogen. The sensitivity of the strain was tested using the Sensititre YeastOne® commercial system, which showed sensitivity to voriconazole and posaconazole, as well as to amphotericin B. The patient died after 7 days at hospital due to an hemodynamic failure.

**Conclusions:** Complete identification of new isolates of *Fusarium* and their antifungal susceptibility patterns is of high interest to improve our knowledge about the epidemiology of the disease and how to best manage patients.

© 2012 Revista Iberoamericana de Micología. Published by Elsevier España, S.L. All rights reserved.

## Fusariosis cutánea por una especie del complejo *Fusarium dimerum* en una paciente con leucemia mieloblástica aguda

## RESUMEN

**Antecedentes:** La fusariosis es una hialohifomicosis oportunista, emergente, producida por hongos pertenecientes al género *Fusarium*. Estos hongos pueden provocar enfermedades que amenazan la vida en pacientes inmunodeficientes, en especial en portadores de leucemia. También se ha descrito en individuos inmunocompetentes, en los que induce lesiones localizadas, no invasivas. En pacientes inmunodeficientes, la fusariosis se asocia a una elevada morbilidad y mortalidad, sobre todo debido a la falta de sensibilidad de estos hongos a los antimicóticos disponibles.

**Caso clínico:** Describimos el caso de una paciente con leucemia mieloblástica aguda que experimentó una fusariosis por una especie del complejo *Fusarium dimerum*. El diagnóstico precoz se estableció en función de la observación microscópica de muestras de las lesiones cutáneas y se prescribió tratamiento con voriconazol. Más tarde, un estudio completo del aislamiento fúngico por cultivo y métodos moleculares permitió la identificación de *F. dimerum*, una especie apenas descrita como patógeno en el ser humano. La sensibilidad de la cepa se examinó con el método comercializado Sensititre YeastOne®, que reveló su sensibilidad a voriconazol y posaconazol, al igual que a anfotericina B. La paciente falleció a los 7 días del ingreso debido a una insuficiencia hemodinámica.

### Palabras clave:

Micosis oportunista

Fusariosis

*Fusarium dimerum*

\* Corresponding author.

E-mail address: [colom@goumh.umh.es](mailto:colom@goumh.umh.es) (M.F. Colom).

**Conclusiones:** La identificación completa de nuevos aislamientos de *Fusarium* y su patrón de sensibilidad a los antimicóticos suscita un gran interés para incrementar nuestros conocimientos sobre la epidemiología de la enfermedad y el tratamiento óptimo de los pacientes.

© 2012 Revista Iberoamericana de Micología. Publicado por Elsevier España, S.L. Todos los derechos reservados.

*Fusarium* spp. are important plant pathogens and may occasionally cause infections in humans. These fungi cause a broad spectrum of infections ranging from superficial to locally invasive and disseminated processes. The clinical form depends largely on the immune status of the host and the portal of entry of the fungus.<sup>7</sup> In this document we describe the case of a patient with Acute Myeloblastic Leukemia (AML) who developed fusariosis by a species of the *Fusarium dimerum* species complex.

### Case report

A 74-year-old woman with a medical history of high blood pressure and dyslipidemia, was admitted to hospital with bilateral edema and pain in both legs and feet. The anterior surface of the feet presented blisters and painful ulcerous lesions with pus discharge and perilesional erythema (Fig. 1). These symptoms had developed over the previous week. At that moment she was being treated with hidroclorotiazida–valsartan 25/160 mg/day. The patient had been previously admitted to primary care services and received levofloxacin 500 mg/12 h and ibuprofen 600 mg/8 h, but the situation did not improve. She also showed symptoms of cardiac failure: dyspnea, orthopnea and increased abdominal perimeter. The patient did not currently present or remember to have had fever.

Physical examination revealed a bad general status and hemodynamic compromise with BP 65/38 mmHg. The cardio-pulmonary examination showed low rhythmic tones and bilateral basal crackles. Laboratory investigations revealed signals of renal failure (creatinine: 8.73 mg/dl; glomerular filtration rate: 5 ml/min), metabolic acidosis (pH: 7.26, HCO<sub>3</sub>: 16.2 mequiv./L), light thrombocytopenia ( $122 \times 10^3/\mu\text{L}$ ), leukocytosis ( $37 \times 10^3/\mu\text{L}$ ) and anemia (Hb: 7.6 mg/dl; VCM: 115.6 fl). Transaminase enzymes and coagulation were normal. After these findings, a subsequent study of bone marrow and peripheral blood resulted in the diagnosis of acute myeloblastic leukemia (AML). Hemodynamic support measures and intravenous treatment with antibiotic were established considering the renal function. Piperaziline–tazobactam 2 g/8 h and levofloxacin 250 mg/48 h were prescribed. Two samples of the curettage of the ulcer lesions were taken and sent to the microbiology laboratory. Both samples were studied under optical microscopy and cultured on sheep blood agar, blood-CNA agar, Polivitex agar, McConkey agar and Sabouraud–Cloramfenicol–Gentamicin agar. After Gram staining,

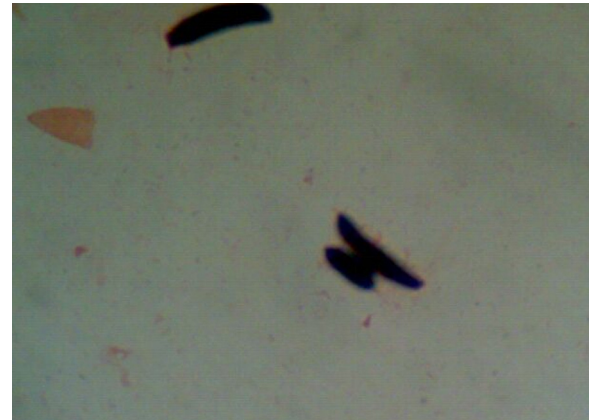

Fig. 2. Direct microscopic observation of the right foot sample. Gram stain (1000 $\times$ ).

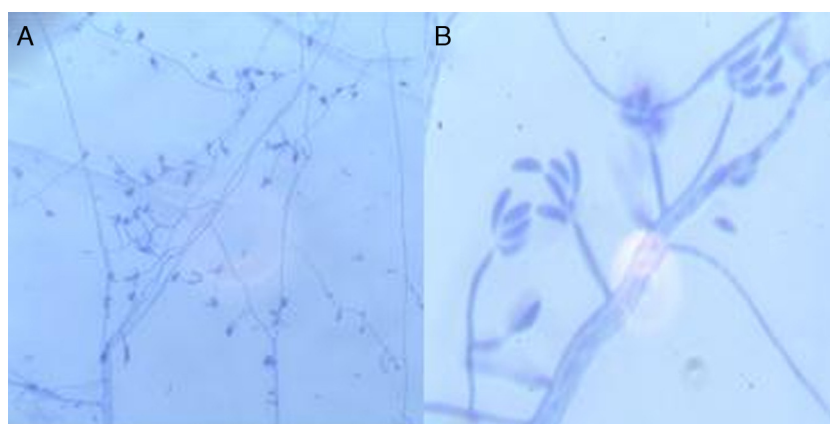
microscopic observation of the sample from the right foot showed a filamentous fungus as the only detectable microorganism. The morphology of the abundant conidia suggested *Fusarium* sp. as the causative agent (Fig. 2). Based on this finding, a first dose of voriconazole 400 mg was administered followed by a regimen of 200 mg/12 h. The direct observation of the left foot sample was not informative.

After two days of incubation at 37 °C, the sample from the right foot yielded a pure culture of a filamentous fungus, which was consistent with the previous Gram stain observation. An *Enterococcus faecalis* was isolated on sheep blood agar from the sample of the left foot and i.v. ampicillin (1 g/8 h) was prescribed. Additionally, two samples of peripheral blood were cultured and came out negative after 5-day incubation. Seven days after admittance to the hospital and after 5 days of treatment with voriconazole, no favorable response was obtained and the patient died.

Based on the difficulty to identify *Fusarium* at a species level, the isolate was sent to the Medical Mycology laboratory (Faculty of Medicine) where it was subcultured on Potato Dextrose Agar, Corn Meal Agar and Malt Extract Agar. Macroscopic and microscopic features were exhaustively studied and concluded in the identification of the strain as *F. dimerum* (Fig. 3). For molecular identification, ITS1-ITS4 and the 5.8S region of the rDNA were amplified with specific primers in a semi-nested PCR.<sup>4</sup> The sequence of a

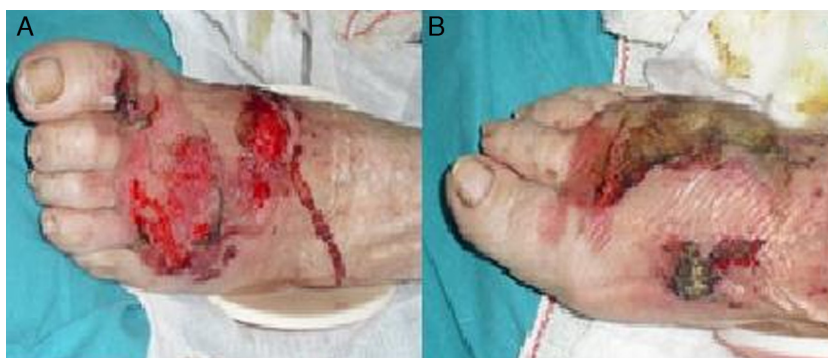

Fig. 1. Photograph of the anterior surface of the left (A) and right (B) feet showing ulcerous lesions.



**Fig. 3.** Morphology of conidiophores and conidia of *Fusarium dimerum*. Microscopic observation of a microculture on Sabouraud dextrose agar. Lactophenol blue stain (A: 200 $\times$ ; B: 1000 $\times$ ).

fragment of 561 nucleotides was obtained and analyzed by comparison in GenBank and EMBL database. A similarity of 100% with the sequence of *Fusarium delphinoides* was found. *F. delphinoides* is one of the species described within the *F. dimerum* morphotype group.<sup>2</sup> Nevertheless, this finding was not enough to assess the identification within the *F. dimerum* species complex, where other species (e.g. *F. necrioides*) could yield the same similarity of the ITS region.<sup>9</sup> The sensitivity of this isolate against conventional antifungal drugs was determined by the Sensititre YeastOne<sup>®</sup> system.<sup>6</sup> The isolate showed resistance to all echinocandins (MICs > 8  $\mu\text{g/ml}$ ), 5-fluorocytosine (MIC > 64  $\mu\text{g/ml}$ ), itraconazole (MIC > 16  $\mu\text{g/ml}$ ) and fluconazole (MIC > 256  $\mu\text{g/ml}$ ), and sensitivity to amphotericin B (MIC: 1  $\mu\text{g/ml}$ ), voriconazole (MIC: 0.5  $\mu\text{g/ml}$ ) and posaconazole (MIC: 0.5  $\mu\text{g/ml}$ ).

## Discussion

Fusariosis in patients with hematological malignancies usually occurs in the shape of disseminated infections where the original site of infection of the fungus is difficult to establish.<sup>3</sup> Skin lesions lead to the diagnosis in more than 50% of patients and usually precede the fungaemia in approximately 5 days. In contrast with aspergillosis, where blood cultures are nearly always negative, fusariosis is accompanied by positive blood cultures in 40–50% of the patients.<sup>5,8</sup> In our case, *F. dimerum* was rapidly detected in the lesions of the right foot. The absence of fever and the negative hemocultures first suggested a possible localized infection. Nevertheless, the diagnosis of AML and the deadly progress of the infection were more in accordance with the existence of fungaemia. Even though a rapid detection of the fungus and a subsequent prescription of appropriate treatment were done, the hemodynamic complications were severe and the patient died.

*Fusarium* has emerged as an important cause of infection in immunocompromised patients and is now considered the second most frequent mold involved in fungal infections.<sup>5</sup> Especially, the disease not only is frequent in patients with hematological malignancies but can also occur as localized infections in healthy patients.<sup>10</sup> The infection in this case was due to one of the 12 phylogenetic species belonging to the morphototype *F. dimerum*.<sup>2</sup> This fungus had been scarcely described as a causative agent of human fusariosis.<sup>2</sup> Its susceptibility to antifungals showed a short spectrum of effective drugs, which is a common feature for *Fusarium* species.<sup>1</sup>

The rapid detection of *Fusarium* spp. by direct microscopy is a very useful tool and allows a rapid prescription of antifungal

treatment. However, it is not enough for a correct management of the infection. The diversity of species involved in fusariosis is underestimated because of the frequent lack of identification at a species level. The species distribution varies per geographic region and different species have different drug susceptibility patterns.<sup>11</sup> Therefore, complete identification of the fungi and their antifungal susceptibility patterns is of high interest to improve our knowledge about the epidemiology of the disease and how to best manage patients.

## Conflicts of interest

The authors report no conflicts of interest. The authors alone are responsible for the content and writing of the paper.

## Acknowledgment

The authors acknowledge María Abad for the professional review of the English writing of the manuscript.

## References

- Bose P, Parekh DH, Holter JL, Greenfield RA. Disseminated fusariosis occurring in two patients despite Posaconazole prophylaxis. *J Clin Microbiol.* 2011;49:1674–5.
- De Hoog GS, Guarro J, Gené J, Figueras MJ, editors. Atlas of clinical fungi. 2nd ed. Reus, Spain: Centraalbureau voor Schimmelcultures/Universitat Rovira I Virgili; 2000. p. 681–705.
- Dignami MC, Anaissie E. Human fusariosis. *Clin Microbiol Infect.* 2004;1: 67–75.
- Ferrer C, Colom F, Frases S, Mulet E, Abad JL, Alio JL. Detection and identification of fungal pathogens by PCR and 5.8S rDNA typing in ocular infections. *J Clin Microbiol.* 2001;39:287–79.
- Maged M, Coleman JJ, Carneiro HA, Mylonakis E. The challenge of managing fusariosis. *Virulence.* 2011;2:91–6.
- Martín-Mazuelos E, Cantón Lacasa E, Espinel-Ingroff A. Otros métodos para el estudio de la sensibilidad a los antifúngicos. In: Pemán J, Martín Mazuelos E, Rubio MC, editors. Guía Práctica de identificación y Diagnóstico en Micología Clínica. Bilbao: Rev Iberoam Micol; 2006.
- Nucci M, Anaissie E. *Fusarium* infections in immunocompromised patients. *Clin Microbiol Rev.* 2007;695–704.
- Pereira Nunes MC, Lima Barbosa FB, Moreira Gomes GH, Bráulio R, Ferreira Nicolliello M, Abreu Ferrari C. Fatal right-sided endocarditis caused by *Fusarium* in an immunocompromised patient: a case report. *Mycoses.* 2011;54:460–2.
- Schroers HJ, O'Donnell K, Lamprecht SC, Kammeyer PL, Johnson S, Sutton DA, Rinaldi MG, Geiser DM, Summerbell RC. Taxonomy and phylogeny of the *Fusarium dimerum* species group. *Mycologia.* 2009;101:44–70.
- Vennwald I, Wollina U. Cutaneous infections due to opportunistic molds: uncommon presentations. *Clin Dermatol.* 2005;23:565–71.
- Wang H, Xiao M, Kong F, Chen S, Dou HT, Sorrell T, Li RY, Xu YC. Accurate and practical identification of 20 *Fusarium* species by seven-locus sequence analysis and reverse line blot hybridization, and an in vitro antifungal susceptibility study. *J Clin Microbiol.* 2011;49:1890–8.