



BRIEF REPORT

## *Scedosporium aurantiacum*: First isolation in Argentina from a previously healthy patient after traumatic inoculation

Susana Carnovale<sup>a,\*</sup>, Carolina Epelbaum<sup>b</sup>, Ruben Abrantes<sup>c</sup>,  
Susana Córdoba<sup>c</sup>, Carla Cabrera<sup>a</sup>, Beatriz Caracciolo<sup>a,1</sup>

<sup>a</sup> Servicio de Microbiología, Hospital de Pediatría S.A.M.I.C. "Prof. Dr. Juan P. Garrahan" Ciudad Autónoma de Buenos Aires, Argentina

<sup>b</sup> Servicio de Infectología, Hospital de Pediatría S.A.M.I.C. "Prof. Dr. Juan P. Garrahan" Ciudad Autónoma de Buenos Aires, Argentina

<sup>c</sup> Departamento de Micología, INEI-ANLIS Dr. C.G. Malbrán, Ciudad Autónoma de Buenos Aires, Argentina

Received 25 May 2021; accepted 23 February 2022

Available online 25 May 2022

### KEYWORDS

*Scedosporium aurantiacum*;  
Argentina;  
Endophthalmitis

**Abstract** *Scedosporium/Lomentospora* species are widely distributed in nature. They are generally saprophytes, but can cause opportunistic infections in immunocompromised patients and occasionally in immunocompetent patients that are difficult to treat due to high levels of antifungal resistance. The distribution of *Scedosporium/Lomentospora* species shows regional differences. *Scedosporium boydii* and *Scedosporium apiospermum* are the most frequently isolated species in our region, whereas *Scedosporium aurantiacum* is more common in other regions. We describe the first isolation in Argentina of *S. aurantiacum* in a vitreous humor infection from a previously healthy patient after traumatic injury in her left eye. Due to the suspicion of fungal endophthalmitis, a mycological study of the vitreous humor was performed. The culture allowed the isolation of *S. aurantiacum*. The patient was treated with voriconazole with favorable clinic evolution.

© 2022 Asociación Argentina de Microbiología. Published by Elsevier España, S.L.U. This is an open access article under the CC BY-NC-ND license (<http://creativecommons.org/licenses/by-nc-nd/4.0/>).

### PALABRAS CLAVE

*Scedosporium aurantiacum*;  
Argentina;  
Endoftalmitis

***Scedosporium aurantiacum*: primer aislamiento en Argentina de un paciente previamente sano después de una inoculación por un traumatismo**

**Resumen** Las especies de *Scedosporium/Lamentospora* se encuentran ampliamente distribuidas en la naturaleza. En general son saprófitas, pero pueden causar infecciones

\* Corresponding author.

E-mail address: [susacarnov@hotmail.com](mailto:susacarnov@hotmail.com) (S. Carnovale).

<sup>1</sup> Co-author.

oportunistas de difícil tratamiento debido a sus altos niveles de resistencia a los antifúngicos en individuos inmunocomprometidos y, ocasionalmente, en personas inmunocompetentes. La distribución de las especies de *Scedosporium/Lomentospora* muestra diferencias regionales. *Scedosporium boydii* y *S. apiospermum* son las especies más frecuentemente aisladas en nuestra región, mientras que en otras *S. aurantiacum* es más común. Presentamos el primer aislamiento en Argentina de *S. aurantiacum* de una infección de humor vítreo de un paciente previamente sano que sufrió una lesión traumática. El paciente fue tratado con voriconazol y tuvo una evolución clínica favorable.

© 2022 Asociación Argentina de Microbiología. Publicado por Elsevier España, S.L.U. Este es un artículo Open Access bajo la licencia CC BY-NC-ND (<http://creativecommons.org/licenses/by-nc-nd/4.0/>).

Species of *Scedosporium/Lomentospora* (*Lomentospora prolificans* formerly *Scedosporium prolificans*) are widely distributed in nature. They can be found in soils, sewers, standing waters, streams, especially in areas where human activity takes place.

In general they are saprophytes but they can cause opportunistic infections in immunocompromised and occasionally in immunocompetent patients, which are difficult to treat due to high levels of resistance to antifungals<sup>11</sup>.

It is known that they cause trauma-associated infections in healthy individuals. In immunocompromised patients, the clinical manifestations range from local infection to lung colonization and severe invasive disease with mortality rates that may exceed 80%<sup>14</sup>.

Currently 11 species are acknowledged within the genus *Scedosporium*: *Scedosporium aurantiacum*, *Scedosporium americanum*, *Scedosporium minutisporum*, *Scedosporium desertorum*, *Scedosporium cereisporum*, and *Scedosporium dehoogii*, besides the *S. apiospermum* complex which comprises *Scedosporium angustum*, *Scedosporium apiospermum*, *Scedosporium boydii*, *Scedosporium ellipsoideum* and *Scedosporium fusoidium*<sup>1,10,14</sup>.

*Scedosporium boydii* and *S. apiospermum* are the most frequently isolated species in our environment. They are among the most commonly recovered fungi from the respiratory secretions of patients with chronic lung diseases such as cystic fibrosis (CF). Lung colonization of patients with cystic fibrosis by *Scedosporium* spp. is well established and the rate ranges between 0 and 21%, being the most frequent genus after *Aspergillus* spp.<sup>7,8</sup>.

It has been reported that the lungs, ears, and sinuses are the main sites of *S. aurantiacum* infection<sup>7</sup>. In Argentina, South America, two *S. aurantiacum* isolates recovered from the sputum of patients with CF have been reported. One isolate belonged to a patient from the city of Buenos Aires who had traveled to Egypt and Europe and the other one belonged to a patient from the province of Santa Fe, Argentina<sup>1</sup>. Moreover, in the United States of America, a single clinical case of *S. aurantiacum* infection in a patient with lung cancer, which was recovered from bronchoalveolar lavage fluid and lung biopsy has been reported<sup>12</sup>.

Below we present the isolation and identification of *Scedosporium aurantiacum* from a 4-year-old previously healthy female patient from San Antonio de Areco (Province

of Buenos Aires, Argentina), who exhibited a penetrating trauma in her left eye caused by a kitchen utensil while she was playing with a friend. After being assessed by an ophthalmologist, the patient was referred to our institution. A surgery procedure was performed on the left eye for corneal trauma. The postoperative treatment included antibacterial eyedrops, intravenous treatment and prednisolone.

Ten days after the procedure, an ultrasound study was performed, confirming the presence of images compatible with inflammatory membranes and probable retinal detachment. Infectious endophthalmitis was taken into consideration.

As a result of the poor evolution of the clinical picture with a marked lack of improvement in the local and systemic treatments applied, endophthalmitis of probable mycotic origin was suspected. Vitrectomy of the left eye and intravitreal injections of amphotericin and vancomycin were the treatments performed.

The vitreous humor was sent to our laboratory for mycological analysis. The fresh microscopic examination with potassium hydroxide (KOH) 40% was negative. The material was cultured in Sabouraud glucose agar (Britania S.A.) and incubated at 28 °C. The development of a filamentous fungus that was subcultivated was obtained 48 h later. After 15 days of incubation a cotton-like colony with a brown center developed. It was whitish towards the edges on the obverse and greyish brown on the reverse with a striking diffusible light yellow pigment (Figs. 1A and B).

With regard to micromorphology, conidiogenic cells (annelids) emerge from undifferentiated hyphae, cylindrical to slightly flask-shaped, with single-celled conidia heads, smooth-walled, sub-hyaline, ovoids or sub-cylinders compatible in shape and size with the genus *Scedosporium*<sup>3</sup> (Fig. 2), although these characteristics were not sufficient for identification at species level.

The isolates were sent to the Department of Mycology of INEI-ANLIS "Carlos G. Malbrán" to perform susceptibility tests and a molecular study. It was based on the sequence of the partial portion of the  $\beta$ -tubulin gene (*BT2*)<sup>4,5</sup>. The similarity of the sequence obtained was searched in the NCBI GenBank database using the BLAST algorithm [National Center for Biotechnology Information (NCBI) Internet homepage, [<http://blast.ncbi.nlm.nih.gov/Blast.cgi>] with automatically adjusted parameters.

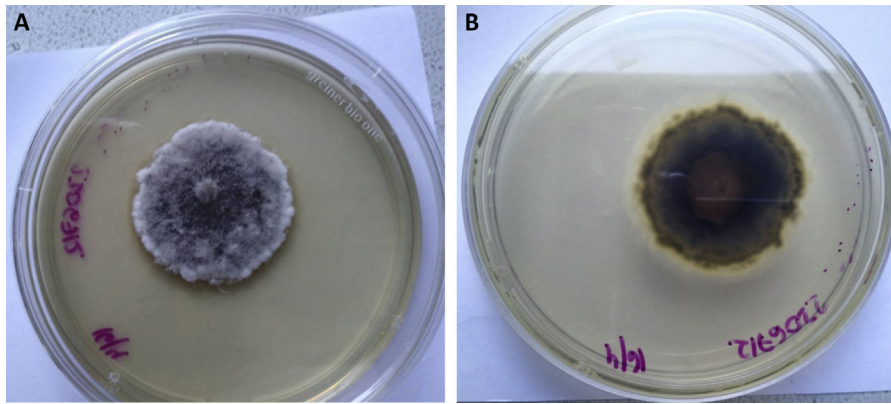


Figure 1 *Scedosporium aurantiacum*. Sabouraud glucose agar. A. Front view. B. Reverse view.

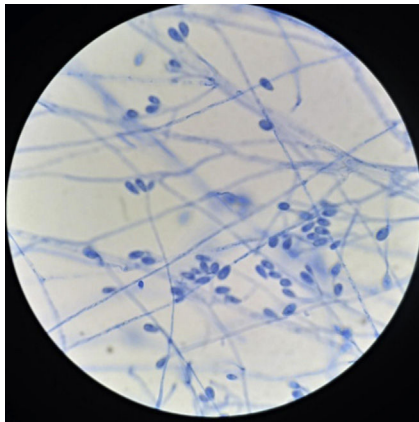


Figure 2 Lactophenol cotton blue stain of *Scedosporium aurantiacum*. Conidiogenous cells, producing ovoid-shaped conidia, either individually or in small groups.

A BLAST search using the *BT2* sequence (584bp) identified our strain DMic 216397 (GenBank Accession Number OK258096) as *Scedosporium aurantiacum*, showing 100% similarity, 97% coverage and an E-value of 0.0 with the *Scedosporium aurantiacum* strain CBS 101725 (GenBank Accession Number GU126389<sup>1</sup>).

Susceptibility tests were performed using the Reference Method M38-3er Ed. of the Clinical and Laboratory Standards Institute (CLSI)<sup>2</sup>. The results of the minimum inhibitory concentrations (CIM) were the following: 8 mg/l for amphotericin B, 0.5 mg/l for itraconazole, 0.25 mg/l for voriconazole, 0.5 mg/l for posaconazole, and 2 mg/l for isavuconazole.

To date, the CLSI has not yet established clinical or epidemiological cut-off points for the genus. The results obtained coincide with the data published by Heath et al.<sup>6</sup>, who studied 27 isolates of *S. aurantiacum* and obtained a MIC range of 2–16 mg/l for amphotericin, 0.25–2 mg/l for itraconazole, 0.03–0.5 for voriconazole and 0.125–1 for posaconazole.

Systemic antibiotic therapy with amphotericin B was initiated and after the confirmation of the etiological agent, it was decided to change to voriconazole, which led to a favorable clinical outcome<sup>9</sup>.

The geographical distribution of the species of the *Scedosporium apiospermum* complex is universal. *S. aurantiacum* was only reported in Australia and some European regions<sup>13</sup>. It has been reported that it colonizes the airways of patients mainly in these countries where there is a large number of patients with CF<sup>4</sup>. Another report describes the isolation of *S. aurantiacum* from a brain abscess in a 2011 tsunami survivor in Japan<sup>13</sup>.

In Australia, *S. aurantiacum* was recovered from more than 50% of the environmental isolates studied, while *S. apiospermum* and *S. dehoogii* are predominant in Austria and France, respectively.

In addition, *S. aurantiacum* is characteristic of agricultural areas in western France. *S. boydii* is the most frequent species (62%) in a French cohort, followed by *S. apiospermum* (24%), *S. aurantiacum* (10%), and *S. minutisporum* (4%).

In a study carried out in Germany in patients with CF, *S. apiospermum* was the most frequent species (49%) followed by *S. boydii* (29%), *L. prolificans* (12%), *S. aurantiacum* (5%) and *S. minutisporum* (5%).

Conversely, *L. prolificans* was the most frequent species isolated in patients with CF in northern Spain. In Australia, the most frequent species appears to be *S. aurantiacum* followed by *L. prolificans* and *S. apiospermum*.

*Scedosporium* species can cause keratitis in immunocompetent hosts usually after corneal trauma with a clinical presentation similar to other types of keratitis.

Endophthalmitis has also been described in immunocompetent individuals secondary to surgery, traumatic inoculation, intravenous drug addiction and contiguous extension from an adjacent site<sup>14</sup>.

Mycological diagnosis in these cases is classically based on direct microscopic examination with KOH from clinical samples and culture in appropriate media. On microscopic examination, however, the hyaline and branched hyphae are similar to those of the genera *Aspergillus* or *Fusarium*.

The identification of species of the genus *Scedosporium* is often difficult to carry out due to the similarity of their morphological characteristics. Currently, molecular or matrix-assisted laser identification by desorption/ionization time of flight mass spectrometry (MALDI-TOF/MS) is mandatory for reliable identification.

Nucleotide sequence-based analysis is the gold standard for the identification of these fungi. Sequencing of rDNA ITS regions allows the proper identification of the main species of *Scedosporium/Lomentospora* while the  $\beta$ -tubulin partial gene (*BT2*) is necessary to differentiate closely related species<sup>1</sup>.

Isolates of *Scedosporium/Lomentospora* present limited susceptibility to all current antifungal drugs. Species of *Scedosporium* are resistant to 5-flucytosine and amphotericin B, as well as to first-generation triazoles, fluconazole and itraconazole.

In addition, they have reduced susceptibility to equinocandins, in particular to caspofungin and anidulafungin. Voriconazole proved to be the most effective antifungal in the treatment against *Scedosporium* spp.<sup>9,11</sup> and the European guidelines recommend it as a first-line drug for treatment along with surgery, when it is possible to perform it<sup>15</sup>.

Although several cases of traumatic *Scedosporium* spp. infections have been documented in our region, no cases of *S. aurantiacum* have been reported so far<sup>1</sup>.

This is the first report in Argentina and the Americas of an isolation of *S. aurantiacum* from a previously healthy patient with a traumatic infection without a history of previous trips abroad.

## Conflict of interest

The authors declare that they have no conflicts of interest.

## References

1. Abrantes R, Refojo N, Hevia A, Fernandez J, Isla G, Cordoba S, Davalos MF, Lubovich S, Maldonado I, Davel G, Stchigel A. *Scedosporium* spp. from clinical setting in Argentina with proposal of the new pathogenic species *Scedosporium americanum*. *J Fungi*. 2021;7:160.
2. CLSI Standards M38 Reference method for broth dilution antifungal susceptibility testing of filamentous fungi. 3rd ed. Wayne, PA, USA: Clinical and Laboratory Standards Institute, CLSI; 2017.
3. De Hoog GS, Guarro J, Gené J, Ahmed S, Al-Hatmi AMS, Figueras MJ, Vitale R. Atlas of clinical fungi. 3rd ed. Utrecht, The Netherlands: Reus; 2019.
4. Delhaes L, Harun A, Chen SC, Nguyen Q, Slavin M, Heath CH, Maszewska K, Halliday C, Robert V, Sorrell TC. Molecular typing of Australian *Scedosporium* isolates showing genetic variability and numerous *S. aurantiacum*. *Emerg Infect Dis*. 2008;14:282–90.
5. Gilgado F, Cano J, Gené J, Guarro J. Molecular phylogeny of the *Pseudallescheria boydii* species complex: proposal of two new species. *J Clin Microbiol*. 2005;43:4930–42.
6. Heath CH, Slavin MA, Sorrell TC, Handke R, Harun A, Phillips M, Nguyen Q, Delhaes L, Ellis D, Meyer W, Chen SCA. Population-based surveillance for scedosporiosis in Australia: epidemiology, disease manifestations and emergence of *Scedosporium aurantiacum* infection. *Clin Microbiol Infect*. 2009;15:689–93.
7. Kaur J, Duan SY, Vaas LA, Penesyan A, Meyer W, Paulsen IT, Nevalainen H. Phenotypic profiling of *Scedosporium aurantiacum*, an opportunistic pathogen colonizing human lungs. *PLoS One*. 2015;10:1–14.
8. Kaur J, Kautto L, Meyer W, Elbourne LDH, Paulsen L, Nevalainen HKM. Interactions of an emerging fungal pathogen *Scedosporium aurantiacum* with human lung epithelial cells. *Sci Rep*. 2019;9:5035.
9. Lackner M, de Hoog GS, Verweij PE, Najafzadeh MJ, Curfs-Breuker I, Klaassen CH, Meis JF. Species-specific antifungal susceptibility patterns of *Scedosporium* and *Pseudallescheria* species. *Antimicrob Agents Chemother*. 2012;56:2635–42.
10. Lackner M, de Hoog GS, Yang L, Ferreira L, Ahmed S, Andreas F, Kalseis J, Nagl M, Lass C, Risslegger B. Proposed nomenclature for *Pseudallescheria*, *Scedosporium* and related genera. *Fungal Divers*. 2014;67:1–10.
11. Lackner M, Hagen F, Meis JF, Gerrits van den Ende AHG, Vu D, Robert V, Fritz J, Moussa TAA, de Hoog GS. Susceptibility and diversity in the therapy-refractory genus *Scedosporium*. *Antimicrob Agents Chemother*. 2014;58:5877–85.
12. Mizusawa M, Totten M, Zhang S. A case of *Scedosporium aurantiacum* infection in the United States. *Mycopathologia*. 2021;186:127–30.
13. Nakamura Y, Suzuki N, Nakajima Y, Utsumi Y, Murata O, Nagashima H, Utsumi Y, Murata o Kagashima H, Saito H, Ssaki M, Fujimura I, Ogino Y. *Scedosporium aurantiacum* brain abscess after near-drowning in a survivor of a tsunami in Japan. *Respir Investig*. 2013;51:207–11.
14. Ramirez-Garcia A, Pellon A, Rementeria, Buldain I, Barreto-Bergter E, Rollin-Pinheiro R, Vieira de Meirelles J. *Scedosporium* and *Lomentospora*: an updated overview of underrated opportunists. *Med Mycol*. 2018;56:102–25.
15. Tortorano AM, Richardson M, Roilides E, van Diepeningen A, Caira M, Munoz P, et al. ESCMID and ECMM joint guidelines on diagnosis and management of hyalohyphomycosis: *Fusarium* spp., *Scedosporium* spp. and others. *Clin Microbiol Infect*. 2014;20:27–46.