




# Enfermedades Infecciosas y Microbiología Clínica

www.elsevier.es/eimc



Diagnosis at first sight

## Dyspnea and pleuritic chest pain during the COVID-19 pandemic

## Disnea y dolor torácico pleurítico durante la pandemia de la COVID-19

Lucía Guillén, Guillermo Telenti\*, Ángela Botella, Mar Masiá

Infectious Diseases Unit, General University Hospital of Elche, University Miguel Hernández, Alicante, Spain

### Case description

A 45-year-old man, active smoker and intranasal cocaine user, presented to the emergency department with a 5-day history of general discomfort, dyspnea and pleuritic chest pain. He reported hemoptysis in the last 24 h. On physical examination, the patient was afebrile, his blood pressure was 110/60 mmHg, the heart rate 60 beats per minute, and the oxygen saturation 94% while breathing room air. Laboratory tests showed a C-reactive protein of 18.7 mg per liter, a D-dimer of 3.58  $\mu$ g per milliliter, 12,480 leukocytes per microliter and 1200 lymphocytes per microliter. The arterial blood gas test showed hypoxemia with an arterial oxygen pressure of 67.8 mmHg while breathing room air. A chest radiography was performed showing a pleural-dependent cuneiform opacity at the right lower lobe (Fig. 1A).

A polymerase chain reaction test for SARS-CoV-2 in nasopharyngeal and oropharyngeal swabs was positive. Computerized tomography (CT) angiography (Fig. 1B) confirmed the presence of pulmonary thromboembolism at the right pulmonary artery, and a pulmonary infiltrate on the right lower lobe indicative of Hampton's hump. The opacity on the chest X-ray was suggestive of Hampton's hump. The patient had been diagnosed 8 days before at the emergency department of deep vein thrombosis in the femoral, popliteal, posterior tibial and external saphenous veins. He had no symptoms suggesting infection with SARS-CoV-2, and the chest X-ray and electrocardiogram had been normal, so he was discharged with oral anticoagulation.

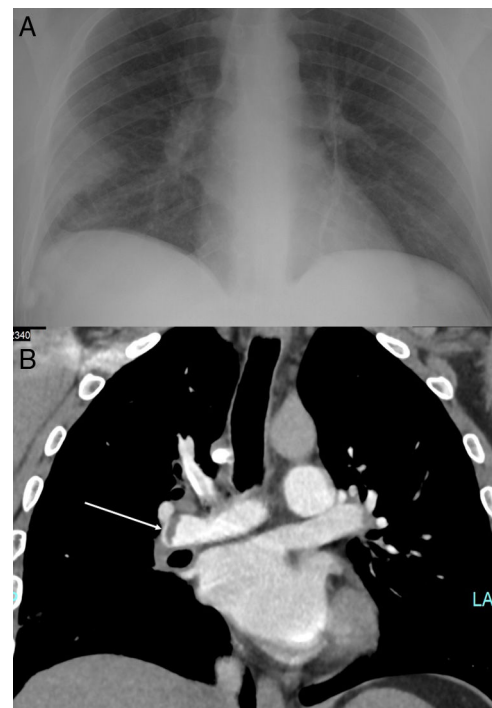


Fig. 1. (A) Hampton's hump. (B) Computerized tomography angiography. Arrow shows the thromboembolism at the right pulmonary artery.

### Evolution

Treatment was initiated with low molecular weight heparin at a dose of 1 mg per kilogram every 12 h, hydroxychloroquine, azithromycin and lopinavir/ritonavir. The patient had a satisfactory clinical outcome, and on day 7 he reported complete resolution of the pulmonary symptoms, and his blood oxygen saturation while breathing room air was 98%.

### Comments

This patient had deep venous thrombosis as the first manifestation of COVID-19. The incidence of thrombosis might be increased in patients with severe acute respiratory syndrome-coronavirus (SARS-CoV)-2 disease (COVID-19).<sup>1</sup> In SARS outbreak occurred in 2003, an incidence of deep vein thrombosis up to 20.5% and of pulmonary thromboembolism (PTE) of 11.3% were reported.<sup>2</sup> COVID-19 has been associated with elevated levels of D-dimer, which have been linked with severe disease, clinical progression, and poor prognosis.<sup>3,4</sup> In a case series of 107 patients with COVID-19 pneumonia admitted to the intensive care unit (ICU), the cumulative incidence of PTE was 20%, twice higher than the

\* Corresponding author.  
E-mail address: guillermotelenti@gmail.com (G. Telenti).

frequency of historical ICU controls.<sup>1</sup> PTE has also been reported after initial improvement, during the recovery phase after the cytokine storm<sup>5</sup> but, to the best of our knowledge, it had not been described as the initial manifestation leading to the diagnosis of COVID-19. Most of previous cases of venous thromboembolism have been reported in severe patients, when the cytochemical storm syndrome has developed.<sup>6,7</sup> Some of the mechanisms potentially contributing to explain the higher risk of thromboembolic complications observed in severe forms of COVID-19 are local inflammation, hemodynamic changes, and the induction of procoagulant factors driven by the enhanced systemic pro-inflammatory response.<sup>3</sup> Vascular endothelial injury leading to disseminated intravascular coagulation has also been proposed as a potential subjacent mechanism involved in the state of hypercoagulability, based on autopsy findings showing microthrombi in the lungs.<sup>8</sup>

This case in a patient without apparent predisposing factors highlights the importance of maintaining the suspicion of COVID-19 disease during the pandemic in the presence of non-typical initial clinical manifestations, especially in those with underlying thrombotic phenomena, and encourages to deepen into the underlying pathophysiological mechanism involved in COVID-19-related coagulopathy.

#### Conflict of interest

No conflict of interest.

#### References

1. Poissy J, Goutay J, Caplan M, Parmentier E, Duburcq T, Lassalle F, et al. Pulmonary embolism in COVID-19 patients: awareness of an increased prevalence [published online ahead of print, 24.04.20]. *Circulation*. 2020. Available from: <https://www.ahajournals.org/doi/10.1161/CIRCULATIONAHA.120.047430>
2. Chong PY, Chui P, Ling AE, Franks TJ, Tai DY, Leo YS, et al. Analysis of deaths during the severe acute respiratory syndrome (SARS) epidemic in Singapore: challenges in determining SARS diagnosis. *Arch Pathol Lab Med*. 2004;128:195–204.
3. Zhou F, Yu T, Du R, Fan G, Liu Y, Liu Z, et al. Clinical course and risk factors for mortality of adult inpatients with COVID-19 in Wuhan, China: a retrospective cohort study. *Lancet*. 2020;395:1054–62.
4. Lippi G, Favaloro EJ. D-dimer is associated with severity of coronavirus disease 2019: a pooled analysis [published online ahead of print, 3.04.20]. *Thromb Haemost*. 2020;10. Available from: <https://www.thieme-connect.de/products/ejournals/abstract/10.1055/s-0040-1709650>
5. Griffin DO, Jensen A, Khan M, Chin J, Chin K, Saad J, et al. Pulmonary embolism and increased levels of D-dimer in patients with coronavirus disease. *Emerg Infect Dis*. 2020 [Epub ahead of print, 29.04.20]. Available from: [https://wwwnc.cdc.gov/eid/article/26/8/20-1477\\_article](https://wwwnc.cdc.gov/eid/article/26/8/20-1477_article)
6. Tang N, Li D, Wang X, Sun Z. Abnormal coagulation parameters are associated with poor prognosis in patients with novel coronavirus pneumonia. *J Thromb Haemost*. 2020;18:844–7. Available from: <https://doi.org/10.1111/jth.14768>
7. Tang N, Bai H, Chen X, Gong J, Li D, Sun Z. Anticoagulant treatment is associated with decreased mortality in severe coronavirus disease 2019 patients with coagulopathy. *J Thromb Haemost*. 2020;18:1094–9. Available from: <https://doi.org/10.1111/jth.14817>
8. Fox SE, Akmatbekov A, Harbert JL, Li G, Brown JQ, Vander Heide RS, et al. Pulmonary and cardiac pathology in covid-19: the first autopsy series from New Orleans. Preprint from medRxiv and bioRxiv. Available from: <https://doi.org/10.1101/2020.04.06.20050575>.