Gastroenterología y Hepatología 47 (2024) 504–505

Gastroenterología y Hepatología

www.elsevier.es/gastroenterologia

IMAGE OF THE MONTH

Black esophagus: Massive bleeding in cirrhosis does not always mean variceal rupture

Esófago negro: el sangrado masivo en cirrosis no siempre significa rotura de várices

Vítor Macedo Silva[a,b,c,*], **Ana Isabel Ferreira**[a,b,c], **Pedro Boal Carvalho**[a,b,c], **Joana Magalhães**[a,b,c], **José Cotter**[a,b,c]

[a] *Gastroenterology Department, Hospital da Senhora da Oliveira, Guimarães, Portugal*
[b] *Life and Health Sciences Research Institute (ICVS), School of Medicine, University of Minho, Braga, Portugal*
[c] *ICVS/3B's – PT Government Associate Laboratory, Braga/Guimarães, Portugal*

Case description

A 65-years old male with known liver cirrhosis presented with massive melena, associated with hemodynamic instability, respiratory failure and alteration of the state of consciousness. Relevant analytical findings included anemia (hemoglobin 11.4 g/dL), thrombocytopenia (114.000 U/L) and hyperlactacidemia (6.2 mmol/L).

The patient underwent endotracheal intubation, being admitted in ICU, and emergent esophagogastroduodenoscopy was performed, revealing a diffuse circumferential black mucosal discoloration of the whole esophagus, with numerous necrotic areas, and an abrupt transition to normal mucosa at the gastroesophageal junction, compatible with acute esophageal necrosis syndrome (AENS) (*black esophagus*) (Fig. 1A and B).[1] Subsequent CT with angiography showed signs of extensive mesenteric ischemia, with gaseous bubbles in several mesenteric branches (Fig. 1C), interpreted in the context of poorly controlled cardiovascular risk factors. The clinical situation deteriorated significantly, with the patient perishing the following day.

AENS is typically caused by ischemic events, with decreased esophageal blood flow leading to fast development of extensive necrosis. The distal third of the esophagus is usually more susceptible to injury, as it is less vascularized compared with other segments.[1]

With this case, we aim to share a rare entity, and highlight the wide range of causes of massive upper gastrointestinal bleeding, even in patients with known cirrhosis.

* Corresponding author.
E-mail address: vitorbmacedo@gmail.com (V. Macedo Silva).

https://doi.org/10.1016/j.gastrohep.2023.10.004
0210-5705/© 2023 The Author(s). Published by Elsevier España, S.L.U. This is an open access article under the CC BY-NC-ND license (http://creativecommons.org/licenses/by-nc-nd/4.0/).

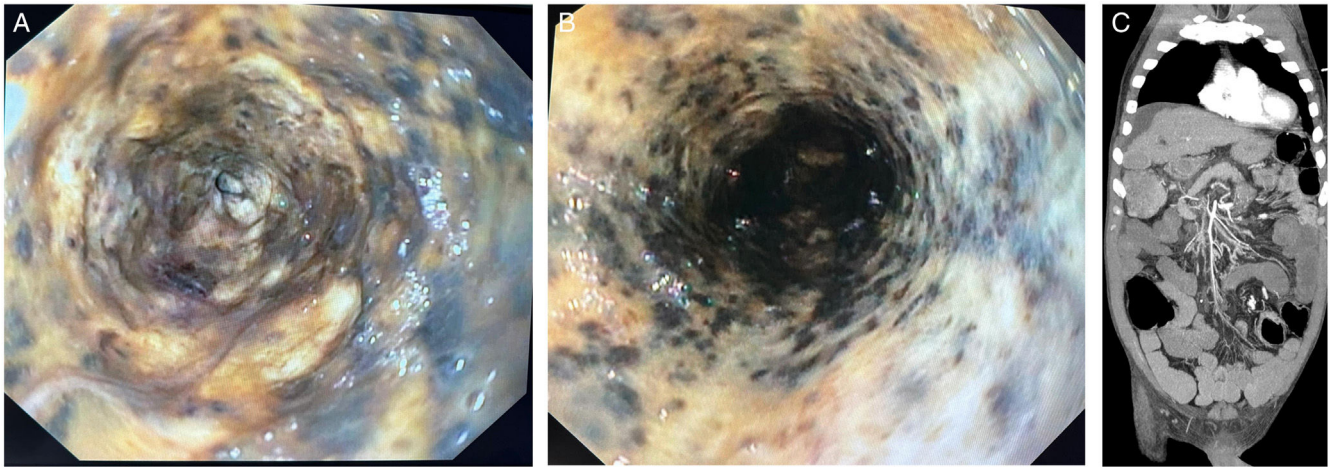

Figure 1 (A and B) Endoscopic snapshots with diffuse circumferential black mucosal discoloration of the whole esophagus, with numerous necrotic areas. (C) Computed tomography with angiography showing signs of extensive mesenteric ischemia.

Ethical considerations

Informed consent acquisition was not possible due to patient's death.

Funding

Nothing to declare.

Conflict of interest

Nothing to declare.

Reference

1. Lamers CR, Mares WGN, Bac DJ. Black esophagus: a case series and literature review of acute esophageal necrosis. Scand J Gastroenterol. 2018;53:1421–4.