

loss, perforation, obstruction, fever, and high levels of LDH.¹ Central nervous system involvement was described in 13% of adult patients with BL.⁹ Although infrequent, the presence of cranial neuropathy is associated with this malignancy.¹⁰

In conclusion, we report an unusual association of intestinal BL in an adult patient with a long history of CD well controlled. The presence of B-symptoms, diarrhea, weight loss and neurological manifestation were the manifestations of BL in this patient.

Author contributions

Saad EJ, Laborie MV and Balderramo D designed the report; Saad EJ, Seculini Patiño CE and Guanchiale L collected the patient's clinical data; Saad EJ and Balderramo D analyzed the data and wrote the paper.

Institutional review board statement: The study was reviewed and approved by the Research Department of the Hospital Privado Universitario de Córdoba, Argentina.

Bibliografía

- Ahluwalia M, Gottlieb V, Damerla V, Saif MW. Aggressive Burkitt-like lymphoma of colon in a patient with prior celiac disease. *Yale J Biol Med.* 2006;79:173–5.
- Catassi C, Bearzi I, Holmes GK. Association of celiac disease and intestinal lymphomas and other cancers. *Gastroenterology.* 2005;128:579–86.
- Mearin ML, Catassi C, Brousse N, Brand R, Collin P, Fabiani E, et al. European multi-centre study on coeliac disease and non-Hodgkin lymphoma. *Eur J Gastroenterol Hepatol.* 2006;18:187–94.
- Leslie LA, Leibold B, Neugut AI, Gregory Mears J, Bhagat G, et al. Incidence of lymphoproliferative disorders in patients with celiac disease. *Am J Hematol.* 2012;87:754–9.
- Ilus T, Kaukinen K, Virta LJ, Pukkala E, Collin P. Incidence of malignancies in diagnosed celiac patients: a population-based estimate. *Am J Gastroenterol.* 2014;109:1471–7.
- Smedby KE, Akerman M, Hildebrand H, Glimelius B, Ekblom A, Askling J. Malignant lymphomas in coeliac disease: evidence of increased risks for lymphoma types other than enteropathy-type T cell lymphoma. *Gut.* 2005;54:54–9.
- Schmitz J, Brousse N. Burkitt-type lymphoma. *J Pediatr Gastroenterol Nutr.* 1996;23:204–5.
- Wong MT, Eu KW. Primary colorectal lymphomas. *Colorectal Dis.* 2005;8:586–91.
- Chehab BM, Schulz TK, Nassif II. Adult Burkitt-like lymphoma of the colon: a case report and a review of the literature. *Gastrointest Endosc.* 2008;67:1204–6.
- Sasaki M, Yamazaki H, Aoki T, Ota Y, Sekiya R, Kaneko A. Bilateral numb chin syndrome leading to a diagnosis of Burkitt's cell acute lymphocytic leukemia: a case report and literature review. *Oral Surg Oral Med Oral Pathol Oral Radiol Endod.* 2011;111:e11–6.

Emanuel José Saad^a, Carina Elizabeth Seculini Patiño^a, María Victoria Laborie^b, Luciana Guanchiale^c, Domingo Balderramo^{d,*}

^a Internal Medicine Department, Hospital Privado Universitario de Córdoba, Instituto Universitario de Ciencias Biomédicas de Córdoba, Argentina

^b Pathology Department, Hospital Privado Universitario de Córdoba, Instituto Universitario de Ciencias Biomédicas de Córdoba, Argentina

^c Hematology and Oncology Department, Hospital Privado Universitario de Córdoba, Instituto Universitario de Ciencias Biomédicas de Córdoba, Argentina

^d Gastroenterology Department, Hospital Privado Universitario de Córdoba, Instituto Universitario de Ciencias Biomédicas de Córdoba, Argentina

* Corresponding author.

E-mail address: dbalderramo@hospitalprivadosa.com.ar (D. Balderramo).

<https://doi.org/10.1016/j.gastrohep.2017.02.008>
0210-5705/

© 2017 Elsevier España, S.L.U., AEEH y AEG. All rights reserved.

Subvesical duct injury resolved by percutaneous drainage



Lesión del conducto subvesical resuelta por drenaje percutáneo

A 61-year-old woman underwent laparoscopic cholecystectomy due to cholelithiasis without any other medical history. The patient was discharged during the same day with no immediate complications.

The 8th day after the surgery she presented to the emergency department referring shoulder pain, without abdominal pain or any other symptoms. The physical examination was unremarkable and the blood test showed only leukocytosis (14 600/ μ L) with neutrophilia (79.30%). The CT scan showed a collection at the gallbladder bed (Fig. 1).

An external drainage catheter was placed, extracting serous fluid.

The 9th day after catheter placement an abdominal radiography with contrast was obtained (Fig. 2) showing a subvesical duct (duct of Luschka). The catheter produced bile after that, but remained afebrile and hemodynamically stable, without abdominal pain. The patient was discharged and required outpatient control until the debit stopped and the drainage was removed out of complications.

Laparoscopic cholecystectomy is the treatment of choice for cholelithiasis and one of the most common surgical procedures performed.¹ Postoperative biliary leaks remain a significant cause of morbidity in patients undergoing this procedure, occurring in 0.4–1.2% of cases.² The cystic duct stump is the most common origin of bile leak (78%), followed by subvesicular duct (Luschka duct) in 13%.³

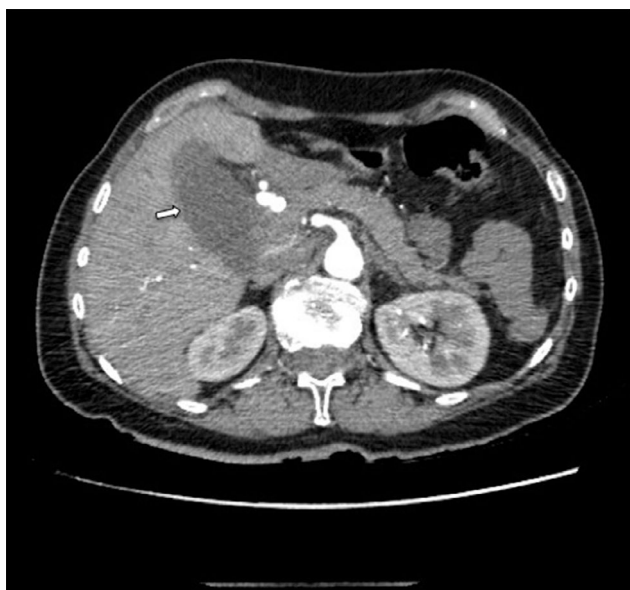

Figure 1 Abdominal CT scan showing a collection at the gallbladder bed (arrow).

Most of the subvesicular bile ducts belong to biliary system of the right hepatic lobe, and are small (1–2 cm in diameter). According to the Strasberg classification, it corresponds to a type A injury.

The clinical presentation may vary. Factors associated with this variability include the volume and distribution of bile in the peritoneal cavity, presence of sterile or infected bile, and presence or absence of a drain. Symptomatic patients after cholecystectomy should undergo investigations with ultrasound or CT scan. If a fluid collection is found, it should be drained under radiological guidance.⁴

There is no current consensus regarding gold standard treatment of post-operative biliary duct injuries. Some studies have indicated that bile leaks can be successfully

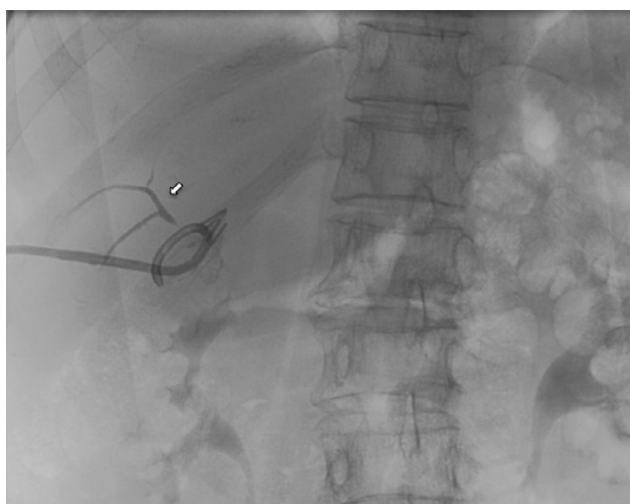


Figure 2 Control image after catheter placement showing the subvesicular duct (arrow).

treated in 78–100% of patients using endoscopic or radiological interventions.⁵ The treatment of leaking Luschka ducts depends on the clinical condition of the patients as well as on availability of imaging and interventional modalities.

In asymptomatic patients with low-output bile leaks, percutaneous external drainage might be enough. Avoiding ERCP will avoid the morbidity (ranges from 5 to 10%)⁶ as post-ERCP pancreatitis, bleeding or duodenal perforation which may occur. Spontaneous resolutions of the leak may arise when subvesicular ducts do not drain significant portions of the parenchyma.

If the leak originates from the end of a Luschka duct that communicates with the central biliary tree, output might be higher and resolution more difficult. In these cases, ERCP with sphincterotomy or percutaneous transhepatic biliary drainage will be required in order to decrease the intrabiliary pressure to allow its closure.

In patients where the bile leak persists despite the endoscopic or percutaneous management, or symptomatic patients with SIRS criteria, surgical reintervention will be necessary.^{7,8}

Precise knowledge of the local anatomy as well as of anatomic variations decreases the risks as shown by the impact of surgeon experience on the frequency of biliary duct injuries. Staying close to the gallbladder wall during its removal from the fossa is the only known prophylactic measure.⁹ The final management of this condition will be decided based on the clinical status and the bile outputs.

Bibliografía

1. Lau WY, Lai ECH. Classification of iatrogenic bile duct injury. *Hepatobiliary Pancreat Dis Int.* 2007;6:459–63.
2. Schnelldorfer T, Sarr MG, Adams DB. What is the duct of Luschka?—a systematic review. *J Gastrointest Surg.* 2012;16:656–62.
3. Navarrete C, Gobelet JM. Treatment of common bile duct injuries after surgery. *Gastrointest Endosc Clin N Am.* 2012;22:539–53.
4. Spanos CP, Syrakos T. Bile leaks from the duct of Luschka (subvesical duct): a review. *Langenbeck's Arch Surg.* 2006;391:441–7.
5. Eum YO, Park JK, Chun J, Lee S-H, Ryu JK, Kim Y-T, et al. Non-surgical treatment of post-surgical bile duct injury: clinical implications and outcomes. *World J Gastroenterol.* 2014;20:6924–31.
6. Jin Y-J, Jeong S, Kim JH, Hwang JC, Yoo BM, Moon JH, et al. Clinical course and proposed treatment strategy for ERCP-related duodenal perforation: a multicenter analysis. *Endoscopy.* 2013;45:806–12.
7. Ruiz Gómez F, Ramia Ángel JM, García-Parreño Jofré J, Figueras J. Lesiones iatrogénicas de la vía biliar. *Cirugía Española.* 2010;88:211–21.
8. Segura-Sampedro JJ, Cañete-Gómez J, Reguera-Rosal J, Padillo-Ruiz FJ, Ramírez-Plaza CP. Unnoticed biloma due to liver puncture after Veress needle insertion. *Ann Med Surg.* 2015;4:238–9.
9. Morales-Conde S, Cañete-Gómez J, Gómez V, Socas Macías M, Moreno AB, Del Agua IA, et al. Laparoendoscopic single-site cholecystectomy: first experiences with a new standardized technique replicating the four-port technique. *J Laparoendosc Adv Surg Tech A.* 2016;26:812–5.

Cristina Pineño-Flores, Juan José Segura-Sampedro*,
José María García-Pérez, Carla Soldevila-Verdeguer,
Elías Palma-Zamora, Francesc Xavier González-Argenté

*Department of General and Digestive Surgery,
Hospital Universitario Son Espases, Palma de Mallorca,
Spain*

* Corresponding author.

E-mail address: segusamjj@gmail.com
(J.J. Segura-Sampedro).

<https://doi.org/10.1016/j.gastrohep.2017.03.005>
0210-5705/

© 2017 Elsevier España, S.L.U., AEEH y AEG. All rights reserved.