

# Gastroenterología y Hepatología

www.elsevier.es/gastroenterologia



## CARTAS AL DIRECTOR

### Porphyria cutanea tarda with multiple nodular foci in the liver

### Porfiria cutanea tarda con focos nodulares múltiples en el hígado

Sir,

Porphyrias are caused by several defects in the biosynthesis of haem. Porphyria cutanea tarda (PCT) is the most common and it is usually latent. The sporadic form (type I) accounts for the 80% of the patients and the other cases are attributed to the familial form (type II).<sup>1</sup> Exposure to alcohol or different drugs can precipitate the clinical expression of this disease and hepatitis C virus can also play a role,<sup>2</sup> furthermore, iron overload and hepatic siderosis seem necessary for PCT to become clinically manifest.<sup>3</sup> In ultrasonography (US) exam, the liver can be normal, hyperechogenic or exhibit signs of chronic liver disease or cirrhosis. Several cases of patients with chronic hepatic porphyria with multiple hepatic nodules firstly assessed by liver US and confirmed by magnetic resonance (MR) or computed tomography (CT) have been described.<sup>4–6</sup> We report two cases of such unusual finding in patients not previously diagnosed with PCT, one with excessive alcohol consumption and the other with previously treated chronic hepatitis C.

#### CASE 1

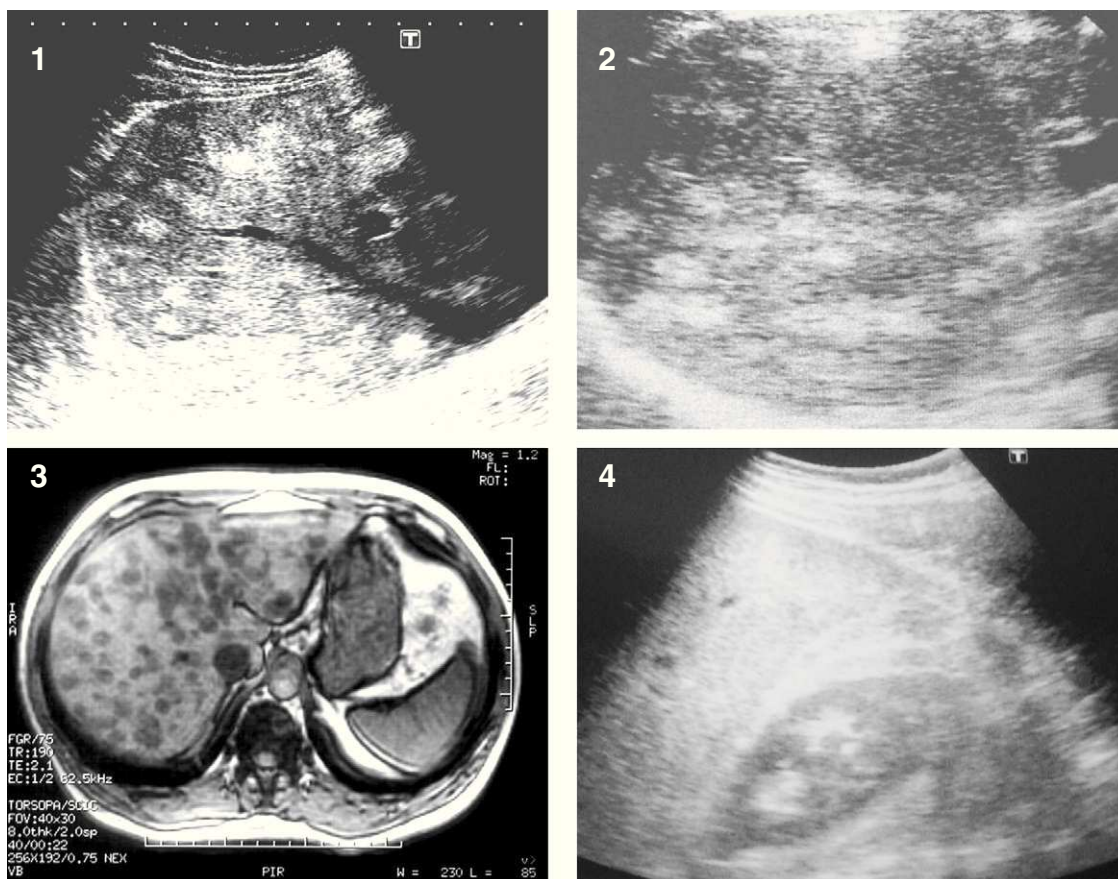
A 49 year old man was referred in 2006 because of abnormal liver tests. He had a history of alcohol abuse for two years. The liver US showed the presence of multiple nodular lesions throughout the parenchyma. These nodules were hyperechoic, homogeneous and well-defined, the vessels were not displaced and portal and hepatic veins went right through the nodules, as confirmed by colour Doppler. A percutaneous liver biopsy showed minimal hemosiderosis, inflammatory infiltrate, and occasional steatosis without porphyrin crystals. Ultraviolet light autofluorescence was positive. Urine analysis showed total porphyrins of 3112 mcg/24 hours (ULN 150 mcg/24 hours). Serology for hepatitis B and C viruses and the C282Y HFE gene mutation were negative. The MRI confirmed multiple nodules with decrease of the signal intensity

in T2 sequences. The fat suppression images showed a loss of signal. He was diagnosed as multifocal fatty liver (Fig. 1). The patient was advised to abstain from alcohol and was treated with phlebotomies. After 12 months, the clinical manifestations had resolved and repeat US showed diffuse steatosis. The clinical disease did not recur after five years of follow-up.

#### CASE 2

A 41 year old man with chronic hepatitis C, genotype 1b, was treated with pegylated interferon alpha-2b plus ribavirin in 2005. Treatment was stopped due to lack of virological response. In May 2007 a routine liver US, showed multiple hyperechoic regular nodules with a maximum diameter of 1.5 cm each, scattered throughout the liver. The initial diagnosis was multinodular focal fatty liver. A MRI scan with gadolinium was performed. The lesions did not show any significant enhancement with the contrast medium in T1 and T2, and in the delayed phase they were isointense compared with the liver parenchyma. The lesions showed an intense loss of signal in opposed phase, confirming deposition of fat. The final MRI diagnosis was multifocal nodular fatty infiltration (Fig. 1). In August 2008 he presented a bullous rash on the fingers and hands and malar hypertrichosis. An elevation in total urine porphyrins of nearly 50 fold, 7068 mcg/24 hours was found. He refused a liver biopsy. The C282Y mutation was negative. Phlebotomies were indicated as treatment and the US performed 18 months later, demonstrated diffuse steatosis without nodules. No recurrence of the disease or the US alterations were seen after four years of follow up.

Porphyria cutanea tarda is the most common form of porphyria in western countries. The deficiency of uroporphyrinogen decarboxylase is present in all tissues in the congenital form and is limited to the liver in the acquired form. Alcohol ingestion, hepatitis C, or abnormal iron metabolism, act as precipitating or aggravating factors. In a meta-analysis including 2167 patients the mean HCV prevalence was 50%.<sup>2</sup> One study in Spain found anti-HCV (+) in 79% of 100 consecutive patients, the frequency increasing with the severity of the liver disease.<sup>7</sup> In contrast, in one report from Germany the prevalence of HCV infection was 8% only.<sup>8</sup> In our second patient, a previous chronic hepatitis C had been previously diagnosed and treated. Clinical



**Figure 1** 1 and 2: Axial US images of patients 1 and 2. Multiple hyperechoic nodular lesions. 3: Hypointense nodules in "opposed phase" (fat suppression) MRI, patient 2. 4: US 18 months after treatment. Diffuse steatosis without nodules, patient 1.

PCT appeared 28 months after stopping the treatment, but liver nodules were found 15 months earlier. There are some reports of development of clinical PCT during treatment with interferon and ribavirin. It has been suggested that the iron overload due to the ribavirin associated hemolysis, could act as a trigger.<sup>9</sup> Liver steatosis usually appears as diffuse hyperechogenic parenchyma in US, but sometimes focal, geographic or nodular infiltration can be seen.<sup>10</sup> In PCT, a hyperechoic liver can also be found, suggesting diffuse steatosis. It is believed that increase of fat, rather than accumulation of porphyrins or iron, most likely causes this appearance.<sup>5</sup> We have found only fourteen cases of multinodular liver foci reported in patients with PCT.

MRI and TC have been considered good techniques for the detection of steatotic nodules of the liver. In MRI diffuse hyperintense areas seen on T2-weighted sequences are related with inflammatory reaction or fat deposition in over half the cases with PCT.<sup>5</sup> In our experience, MRI gadolinium scan is an excellent tool for the diagnosis of hepatic multinodular focal fatty liver, when previously found in a US exam. Chemical shift in MRI imaging is a very effective method to identify and characterize these nodules. CT scan has also demonstrated to be useful. In summary, the finding of multiple hyperechoic nodules in the liver in patients without clinical or biochemical signs of malignancy, must lead to have in mind the possibility of other entities. PCT must always be considered and it has to be included in

the differential diagnosis. In such a case, a MRI or CT is required.

### Conflicts of interest

Nothing to disclose.

### Acknowledgements

We are indebted to Dr. Rafael Menéndez de Llano and to Dr. Faustino G. Arias, from de Department of Radiology for advisement in the selection and interpretation of the images. We also thank Prof. Javier F. Gago for technical assistance.

### References

1. Elder GH. Porphyrin cutanea tarda. *Semin Liver Dis.* 1998;18:67-75.
2. Gisbert JP, García-Buey L, Pajares JM, Moreno-Otero R. Prevalence of hepatitis C virus infection in porphyria cutanea tarda: systematic review and meta-analysis. *J Hepatol.* 2003;39:620-7.
3. Bonkovsky HL, Poh-Fitzpatrick M, Pimstone N, Obando J, Di Bisceglie A, Tattrie C, et al. Porphyrin cutanea tarda, hep-

- atitis C, and HFE gene mutations in North America. *Hepatology*. 1998;27:1661-9.
4. Eubanks SW, Patterson JW, May D, Aeling JL. The porphyrias. *Int J Dermatol*. 1988;63:282-9.
  5. Chevallier P, Bahadoran P, Buckley MJ, Hebuterne X, Diaine B, Chevallier A, et al. Hepatic multi-nodular focal fatty metamorphosis in acquired porphyria cutanea tarda. Sonographic, CT, and MRI features. *Clin Imaging*. 1998;22:418-21.
  6. Dirks K, Lutz H. Multiple circular liver foci in chronic hepatic porphyria: two sonographic case reports. *Ultraschall Med*. 2000;21:86-9.
  7. Herrero C, Vicente A, Bruguera M, Ercilla MG, Barrera JM, Vidal J, et al. Is hepatitis C virus infection a trigger of porphyria cutanea tarda? *Lancet*. 1993;341:788-9.
  8. Stölzel U, Köstler E, Koszka C, Stöffler-Meilicke M, Schuppan D, Somasundaram R, et al. Low prevalence of hepatitis C virus infection in porphyria cutanea tarda in Germany. *Hepatology*. 1995;21:1500-3.
  9. Thevenot T, Bachmeyer C, Hammi R, Dumouchel P, Ducamp-Posak I, Cadranet JF. Occurrence of porphyria cutanea tarda during peginterferon/ribavirin therapy for chronic viral hepatitis C. *J Hepatol*. 2005;42:607-8.
  10. Sabaté JM, Bourrier P, Vital JL, Cordoliani F, Lémann M, Zagdanski AM. Images in hepatology: multinodular focal fatty infiltration of the liver in acquired porphyria cutanea tarda. *J Hepatol*. 2000;6:1022.

Ramón Pérez Álvarez\*, Rosa Pérez López,  
Nieves González Sotorrió, Luis Rodrigo Sáez

*Servicio de Digestivo, Hospital Central de Asturias,  
Facultad de Medicina, Oviedo, Asturias, España*

\* Corresponding author.

E-mail address: [peralbar@telefonica.net](mailto:peralbar@telefonica.net) (R. Pérez Álvarez).

doi:10.1016/j.gastrohep.2011.08.005

## Quiste hepático en paciente con carcinoma cloacogénico anorrectal: ¿metástasis o enfermedad benigna hepática?

### Hepatic cyst in a patient with anorectal cloacogenic carcinoma: Metastasis or benign liver disease?

*Sr. Director:*

Las metástasis hepáticas quísticas han sido previamente descritas en pacientes con antecedentes de carcinoma escamoso de cuello uterino y de amígdalas<sup>1-4</sup>, sin embargo hasta donde conocemos, no existen comunicaciones previas de metástasis quísticas en hígado con un origen primario anorrectal. Teniendo en cuenta lo infrecuente de estas lesiones y las dificultades clínicas y/o radiológicas que conllevan presentamos un caso reciente de carcinoma cloacogénico anorrectal con quiste hepático. Se trata de un varón de 55 años de edad que acude a consulta por antecedentes de rectorragia de un mes de evolución. La colonoscopia detecta una masa tumoral en la región anorrectal que se biopsia y se informa un diagnóstico en anatomía patológica de carcinoma basaloide cloacogénico anorrectal. Los estudios de extensión radiológicos (tomografía computarizada [TC] y resonancia magnética [RM] abdominopélvica) no detectaron lesiones metastásicas a distancia (fig. 1A). El paciente fue tratado inicialmente con un régimen de quimiorradioterapia (5-fluorouracilo y mitomicina), observándose una marcada reducción de la masa tumoral que se confirmó en la RM pélvica. En el estudio de seguimiento realizado a los 8 meses se detectó en la TC abdominal una masa quística de grandes dimensiones en el lóbulo hepático derecho, con el aspecto clínico y radiológico de quiste simple hepático benigno (fig. 1B). Considerando los datos clínicos y el resultado de la TC se realizó un drenaje del quiste mediante punción percutánea guiada por ecografía. El estudio citológico del líquido extraído fue negativo para células

malignas. La aspiración percutánea del quiste y la aplicación de 6 sesiones de escleroterapia redujeron considerablemente el tamaño de la lesión. Sin embargo, en los estudios de seguimiento realizados 4 meses después se detectó en la exploración por TC abdominal que la lesión quística hepática había empeorado y que en ese momento no solo se observaba una lesión quística, sino numerosas lesiones sólido-quísticas en el lóbulo derecho con bordes irregulares y de carácter infiltrativo muy indicativo de lesión maligna (fig. 1C). Considerando los hallazgos radiológicos y la ausencia de lesiones malignas en otra localización se decide realizar una laparotomía exploratoria donde se detecta en el lóbulo hepático derecho una masa tumoral sólido-quística. Se realiza biopsia transoperatoria que informa metástasis hepática por carcinoma cloacogénico (fig. 1D-F). Se prescribe tratamiento quimioterápico con cisplatino y 5-fluorouracilo y actualmente el paciente se encuentra en seguimiento oncológico.

El presente caso nos demuestra que las metástasis deben ser consideradas en el diagnóstico diferencial de lesiones quísticas hepáticas solitarias, sobre todo cuando exista una historia previa de un tumor maligno primario en otra localización<sup>1</sup>. Particularmente los carcinomas escamosos, incluida la variante basaloide pueden presentar extensa necrosis dando la apariencia radiológica de una lesión quística. Adicionalmente, uno o incluso varios estudios citológicos negativos no excluyen la posibilidad de una metástasis quística teniendo en cuenta que existe un porcentaje no insignificante de resultados falsos negativos cuando se estudian los quistes solamente con métodos citológicos.

En el caso actual se consideró la posibilidad de una metástasis hepática quística pero los estudios citológicos negativos y el aspecto benigno de las imágenes radiológicas en los estudios iniciales proporcionaron una falsa apariencia de la lesión. No obstante, la historia previa de un carcinoma cloacogénico anorrectal y la presencia de un estudio radiológico normal antes de aparecer la lesión quística inicial apoyaban la posibilidad de una metástasis hepática. El estudio histopatológico de la pared del quiste es fundamental