



Prosthodontic treatment of patients afflicted with hypohidrotic ectodermal dysplasia: Report of two cases

Tratamiento prostodóntico de pacientes con displasia ectodérmica hipohidráulica: reporte de dos casos

Ernesto Urbina Vázquez,* Alejandro Santos Espinoza,§ Enrique Navarro Bori§

ABSTRACT

Ectodermal dysplasia is a hereditary disorder characterized by the abnormal development of certain ectodermal-origin tissues and structures. Hypohidrotic type is the most commonly observed form of ectodermal dysplasia. Diagnosis is based on the absence or decrease of sweat glands. Dental treatment of oral deficiencies characteristic of this syndrome is commonly quite complex. Physiological and psychosocial reasons dictate the importance for these patients to receive dental treatment at early ages. The present clinical report describes characteristics and prosthodontics treatment of two siblings afflicted with hypohidrotic ectodermal dysplasia.

Key words: Ectodermal dysplasia, hypohidrotic, full dentures, lingualized occlusion.

Palabras clave: Displasia ectodérmica, hipohidráulica, dentaduras totales, oclusión lingualizada.

RESUMEN

La displasia ectodérmica es un desorden hereditario caracterizado por un desarrollo anormal de ciertos tejidos y estructuras de origen ectodérmico. La forma más comúnmente observada de displasia ectodérmica es del tipo hipohidráulica. El diagnóstico se basa en la ausencia o disminución de glándulas sudoríparas. Comúnmente es una condición complicada en cuanto al tratamiento odontológico de las deficiencias orales características de este síndrome. Es importante que estas personas reciban atención dental a temprana edad por razones fisiológicas y psicosociales. Este reporte clínico describe las características y el tratamiento prostodóntico de dos hermanos con displasia ectodérmica hipohidráulica.

INTRODUCTION

Ectodermal dysplasia is a hereditary disorder characterized by the abnormal development of certain ectodermal-origin structures.¹⁻⁷ Among the structures at risk we can count hair, sweat and sebaceous glands, nails, teeth, the eye's conjunctive, the crystalline, anterior pituitary glands and ears. Central nervous system defects can also be found.¹⁻³ Hypohidrotic ectodermal dysplasia can exhibit either a recessive autosomal pattern or a pattern linked to chromosome X. Nevertheless, the most common type is the one linked to chromosome X, exhibited in males.² Moreover, due to mutation of gene Xq12q13,^{3,4} anhidrotic or hypohidrotic ectodermal dysplasia can appear in a family lacking any history of this condition.

Female carriers of this disease might be afflicted with a variable degree of clinical implications, which might vary from undetectable signs to the manifestation of considerable signs of hypodontia, hypotrichosis and unilateral chest hypoplasia.⁵ This is only one of the 192 types of described

dysplasia cases. Ectodermal dysplasia is present in all ethnicities, it is estimated that 7 out of every 10,000 births present some type of ectodermal dysplasia, and one out of 100,000 male births presents the anhidrotic variance.¹⁻⁹ Affected males exhibit extensive dental absence, among other characteristics such as prominent forehead, depressed nasal bridge, protuberant lips and undefined vermillion border.^{1-3,5-9}

* Graduate, Implantology and Oral Prosthesis Specialty.

§ Professor at the Implantology and Oral Prosthesis Specialty.

Graduate and Research School, National School of Dentistry, National University of Mexico (UNAM).

Received: July 2016.

Accepted: September 2016.

© 2016 Universidad Nacional Autónoma de México, [Facultad de Odontología]. This is an open access article under the CC BY-NC-ND license (<http://creativecommons.org/licenses/by-nc-nd/4.0/>).

This article can be read in its full version in the following page: <http://www.medigraphic.com/facultadodontologiaunam>

During childhood, hypohidrosis can be found in variable degrees. Frequently with severe cases of hyperthermia.¹⁰

Hypodontia or anodontia are the most common oral manifestation; they reflect complete suppression of the dental ectoderm. Some teeth can be present with delayed eruption; they are usually malformed or conical teeth. It is common to find dry oral mucosa due to the decrease or absence of salivary glands. Likewise, due to absence of teeth in the residual ridge, it fails to develop suitably, in some cases it even appears missing; in consequence, there might be decrease in facial vertical dimension.

In these patients, the appearance of their teeth is extremely important since it can affect their self-esteem. Psychosocial and physiological reasons mandate providing dental care for patients at an early age. Periodic revisions are also needed in order to preserve and follow up the patients' oral health status.

Most frequent prosthetic treatment is the manufacture of full prostheses, although fixed prostheses or prostheses over implants can also be used. Prosthesis manufacturing enhances sagittal and vertical skeletal relationship during growth and development, since they provide improvement in esthetics, phonetics and masticatory efficiency.

The present clinical report describes characteristics and treatment of two siblings afflicted with hypohidrotic ectodermal dysplasia.

CLINICAL REPORT

A 19 year old male and his 12 year old sister attended the Implantology and Oral Prosthesis Department of the Graduate and Research School, National School of Dentistry, National University of Mexico (UNAM), for examination, assessment and prosthetic treatment.

Both patients exhibited characteristic traits of hypohidrotic ectodermal dysplasia, which included the following: protuberant lips, depressed nasal bridge, mild alopecia well as sparse eyebrows and eyelashes (*Figures 1A and 1B*). The male exhibited syndactyly in both hands (*Figure 1C*).

Both patients wore full dentures and exhibited decrease in vertical dimension. Intra-oral exploration revealed dry mucosa as well as small, thin and undeveloped residual ridges (*Figures 1D and 1E*). Patients had been wearing full dentures for two years. In the boy's denture, a fissure was found at the level of the midline. The girl's denture was maladjusted due to the growth of both upper and lower jaws.

During interview they mentioned that their father had been diagnosed with anhidrotic ectodermal dysplasia, and was wearing a full denture.

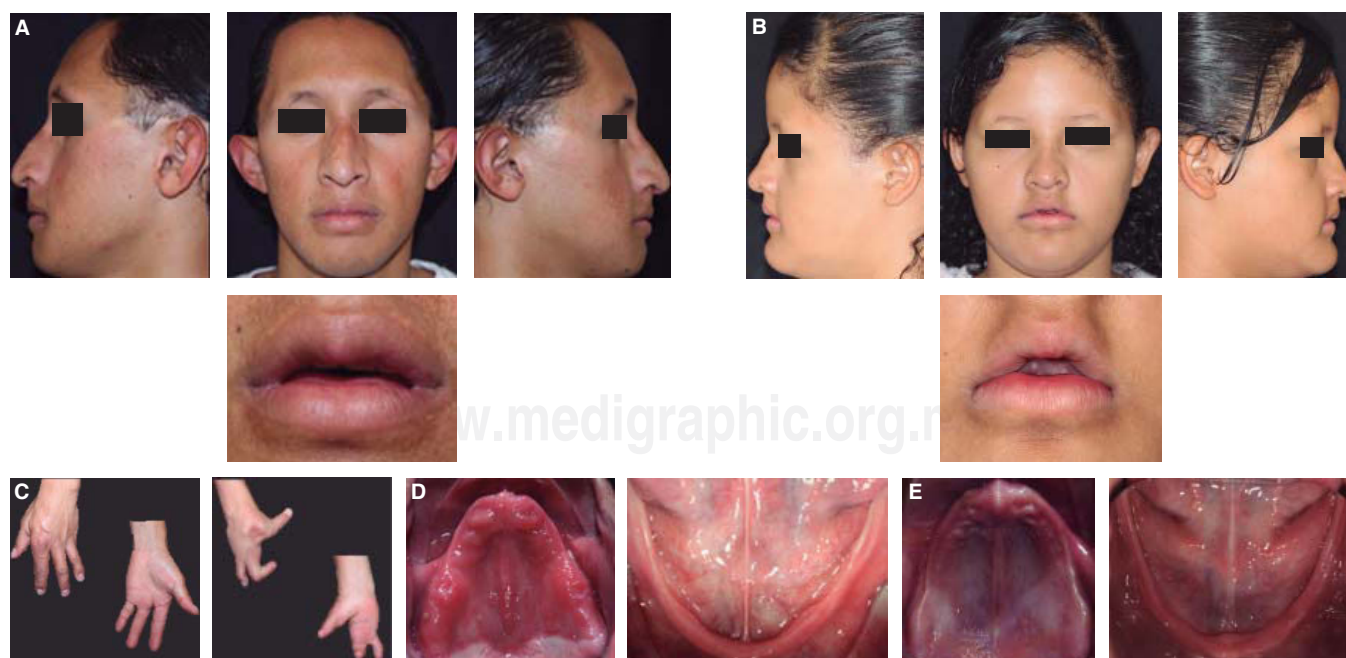

Figure 1. Patients' clinical characteristics. **(A and B)** Characteristic facial traits of dysplasia patients. **(C)** Syndactyly exhibited by the male patient. **(D and E)** Intraoral photographs showing total de-centration state.

CLINICAL PROCEDURES

Anatomical impressions were taken to achieve study models and manufacture acrylic individualized trays. With these trays, myofunctional recording was achieved using heavy consistency polyvinylsiloxane silicone (Elite HD+ Monophase Heavy Body/ Zhermack®), to later achieve physiological impression with polysulfide rubber.

In order to achieve craniomandibular relationships, positives of impressions were obtained, recording bases were manufactured and wax rollers were fabricated. Models were mounted by means of facial arch in a Modular Hanau articulator (*Figure 2*). It was decided to place teeth in a lingualized occlusion scheme, using a curved template similar to the type used by Dr. French (*Figures 3 and 4*).

Gyst, described lingualized occlusion for full prosthesis in 1927, this was also described by Howard Payne, DDS, more recently in 1941. In this scheme upper palatal cusps are articulated with lower occlusal surfaces in positions of work and balance, a term attributed to Earl Pound. The occlusal scheme is based on using palatal cusp of upper molars as stamping cusp to occlude with a shallow lower central fossa, ensuring at the same time lack of contact with upper buccal cusps or lower lingual cusps, creating thus a mortar and pestle effect.¹¹

Due to the characteristic of vertically directing mastication forces towards the residual process, oblique forces applied to the retentive structures are decreased. The objective of achieving bilateral balanced occlusion along with lingualized occlusion is to obtain soft bilateral contacts in eccentric movements. Therefore, this occlusal philosophy is

indicated in cases where there is severe alveolar resorption, class 2 maxillary-mandibular relationship, hypermobile soft tissue, thin and poorly adhered mucosa, low salivary flow, low muscle tonicity, and poor neuromuscular coordination.

Once pertinent tests had been conducted and counting with patient and parental approval, prostheses were characterized and processed (*Figure 5*). Prostheses were re-mounted and polished, occlusal balance was checked before delivery to patients (*Figures 6 and 7*).

Patients were instructed to follow a soft diet during the initial days so as to facilitate new dentures' adaptation (*Figure 8*). Patients were instructed in the use of artificial saliva. To decrease oral dryness, presently there is an available saliva substitute. This substance was developed at the Faculty of Chemistry, National University of Mexico (UNAM). It is composed

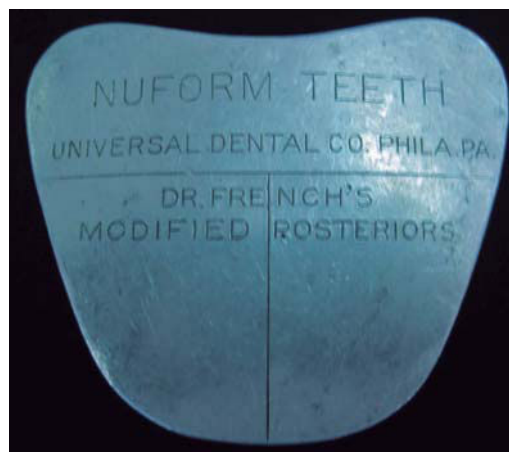


Figure 3. Dr. French's curved template.

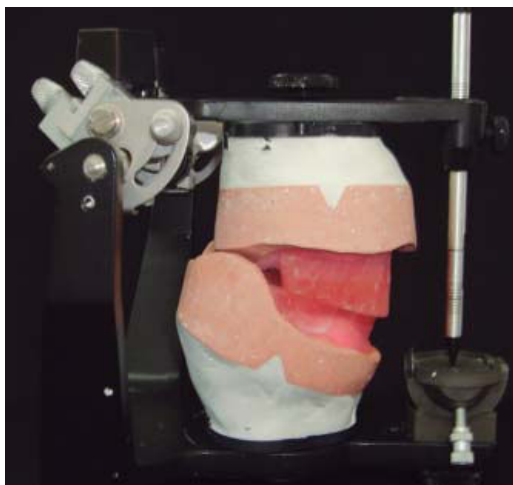


Figure 2. Mounting of working models.

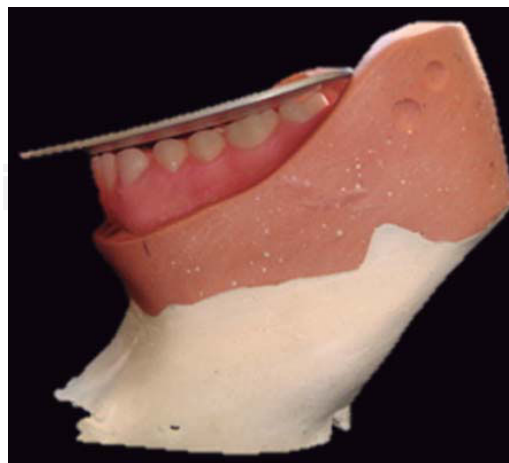

Figure 4. Placement of lower teeth using curved template.

of pear cactus mucilage (*Opuntia ficus indica*) and in addition to lower cost, possesses the advantages of exhibiting better viscosity characteristics than synthetic artificial saliva.¹²

DISCUSSION

Dental treatment of hypohidrotic ectodermal dysplasia is complex. It entails special treatment,

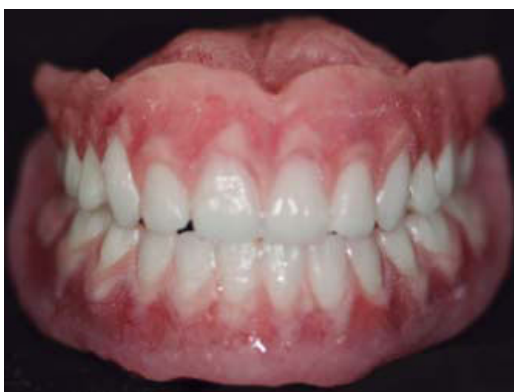

Figure 5. One of the processed dentures where characterization can be observed.

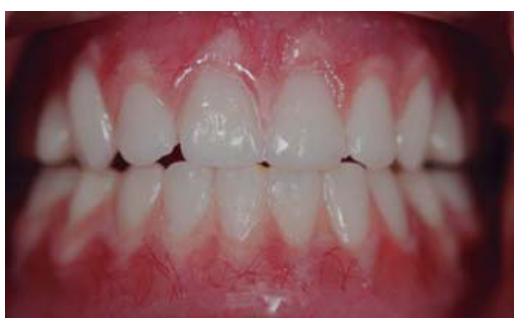

Figure 6. Intraoral view of the male's denture.

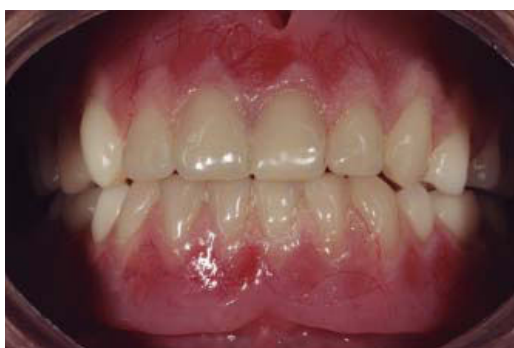

Figure 7. Front view of the female's prosthesis.

since patients begin their prosthetic treatment at very early ages, thus requiring a multi-disciplinary approach. Restoration of natural appearance is of the utmost importance in the psychosocial development of the patient as well as his future insertion in society. With respect to prosthetic treatment, full prosthetics is the most commonly used, notwithstanding the disadvantages encountered with the growth and development of the jaws, which causes maladjustment, and therefore, the need to undertake continuous changes in the dentures. Another disadvantage is patient cooperation; in these instances, parental help is of the utmost importance for the patient to accept treatment and constant use of dentures.

Prosthetic stability and retention is difficult to achieve due to the jaws' poor development. Another

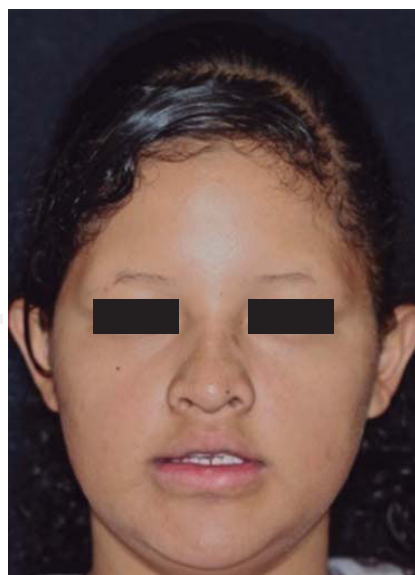
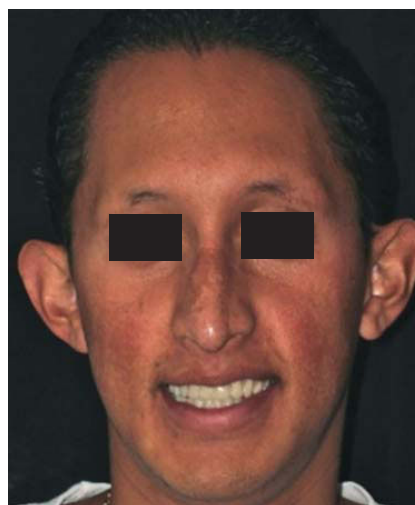
Figure 8. Patients' clinical aspect with dentures in place.

encountered complication is oral mucosa dryness, since this hinders feeding, adjustment and bucco-pharyngeal health, therefore it is recommended to use artificial saliva which mimics the viscosity and pH of a healthy individual's saliva.

CONCLUSIONS

Patients afflicted with ectodermal dysplasia require treatment embodying multi-disciplinary approach. It is very important for the patient to begin treatment at an early age in order to avoid impingement of self-esteem and foster integration in society. Due to the oral characteristics of hypohidrotic ectodermal dysplasia, the most frequent treatment is manufacture of full prostheses; nevertheless, the clinician can face several difficulties such as poor development of alveolar processes and dryness of the mouth, as consequence of poor or nil salivary secretion.

Use of artificial saliva is an auxiliary in the use of full prostheses as well as to preserve suitable feeding and maintenance of oropharyngeal health. The use of artificial saliva made from pear cactus mucilage is a viable alternative; due to the similar viscosity and pH it exhibits when comparing it to saliva of a healthy individual. Moreover, manufacture of this saliva is reasonably cheaper than substitutes found in the market, which are commonly made of glycerin, carboxymethyl, sodium cellulose and sorbitol.

REFERENCES

1. Açıkgoz A, Kademoglu O, Elekdag-Türk S, Karagöz F. Hypohidrotic ectodermal dysplasia with true anodontia of the primary dentition. *Quintessence Int.* 2007; 38: 853-858.
2. Vieira KA, Teixeira MS, Guirado CG, Gaviao MB. Prosthodontic treatment of hypohidrotic ectodermal dysplasia with complete anodontia: case report. *Quintessence Int.* 2007; 38: 75-80.
3. Hekmatfar S, Jafari K, Meshki R, Badakhsh S. Dental management of ectodermal dysplasia: two clinical case reports. *J Dent Res Dent Clin Dent Prospects.* 2012; 6 (3): 108-112.
4. Itthagarun A, King N. Ectodermal dysplasia: a review and case report. *Quintessence Int.* 1997; 28: 595-602.
5. Pae A, Kim K, Kim HS, Kwon KR. Overdenture restoration in a growing patient with hypohidrotic ectodermal dysplasia: a clinical report. *Quintessence Int.* 2011; 42: 235-238.

6. Yap A, Klineberg I. Dental implants in patients with ectodermal dysplasia and tooth agenesis: a critical review of the literature. *Int J Prosthodont.* 2009; 22: 268-276.
7. Pipa A, López E, González M, Martínez M, Blanco F. Treatment with removable prosthesis in hypohidrotic ectodermal dysplasia. A clinical case. *Med Oral Patol Oral Cir Bucal.* 2008; 13 (2): 119-123.
8. Kaul S, Reddy R. Prosthetic rehabilitation of an adolescent with hypohidrotic ectodermal dysplasia with partial anodontia: case report. *J Indian Soc Pedod Prevent Dent.* 2008; 26 (4): 177-181.
9. Bergendal B. The role of prosthodontists in habilitation and rehabilitation in rare disorders: the ectodermal dysplasia experience. *Int J Prosthodont.* 2001; 14: 466-470.
10. Bonilla ED, Guerra L, Luna O. Overdenture prosthesis for oral rehabilitation of hypohidrotic ectodermal dysplasia: a case report. *Quintessence Int.* 1997; 28: 657-665.
11. Yavuz I, Kiralp S, Baskan Z. Hypohidrotic ectodermal dysplasia: a case report. *Quintessence Int.* 2008; 39: 81-86.
12. Toledano-Magaña Y. *Elaboración de una saliva sustituta para el tratamiento de xerostomía resultado de tratamientos contra cáncer de cuello y cabeza* [Tesis]. México: Universidad Nacional Autónoma de México. Facultad de Química; 2010.

RECOMMENDED READINGS

- Reitz JV. Lingualized occlusion in implant dentistry. *Quintessence Int.* 1994; 25: 177-180.
- Ohguri T, Kawano F, Ichikawa T, Matsumoto N. Influence of occlusal scheme on the pressure distribution under a complete denture. *Int J Prosthodont.* 1999; 12: 353-358.
- Stanford CM, Guckes A, Fete M, Srun S, Richter MK. Perceptions of outcomes of implant therapy in patients with ectodermal dysplasia syndromes. *Int J Prosthodont.* 2008; 21: 195-200.
- King NM, Tong MC, Ling JY. The ectrodactyly-ectodermal dysplasia-clefting syndrome: a literature review and case report. *Quintessence Int.* 1994; 25: 731-736.
- Itthagarun A, King NM. Oral rehabilitation of a hypohidrotic ectodermal dysplasia patient: a 6-year follow-up. *Quintessence Int.* 2000; 31: 642-648.
- Ellis RK, Donly KJ, Wild TW. Indirect composite resin crowns as an esthetic approach to treating ectodermal dysplasia: a case report. *Quintessence Int.* 1992; 23: 727-729.

Mailing address:

Ernesto Urbina Vázquez

E-mail: neliotness@gmail.com