



Class III malocclusion correction through surgical-orthodontic treatment

Corrección de maloclusión clase III mediante tratamiento orto-quirúrgico

Alejandra Vázquez Valencia,* David Meza Lora,§ Juan Eduardo Flores Salas,§ Daniel Abitia Hawley,§
María Isabel Hernández Rivas,§ Jacqueline Adelina Rodríguez Chávez§

ABSTRACT

Patient treated in the clinic of Orthodontics of the Universidad Autónoma de Guadalajara, referring as reason for consultation «I can not eat comfortably and I feel ashamed of my facial appearance». A full dentofacial study was conducted. The patient was diagnosed with a skeletal class III malocclusion caused by maxillary hypoplasia and mandibular prognathism. Surgical-orthodontic treatment was determined. The patient and his parents were informed about the treatment, risks, benefits, advantages and disadvantages, duration of treatment, costs and post-operative care. Once the treatment plan was accepted, the objectives were to achieve skeletal class I as well as bilateral canine class I and molar class II. 0.022 Roth appliance placement was indicated with upper 1st premolars extractions, going through the stages of alignment, leveling and space closure. We worked as a team with the Department of Surgery. A successful treatment of pre-surgical orthodontics and maxillofacial surgery (maxillary advancement and mandibular reposition) was achieved thus obtaining as a result skeletal class I, canine class I and bilateral molar class II. The patient recovered his chewing function and self-esteem by being aesthetically accepted by society.

RESUMEN

Paciente tratado en la Clínica de Ortodoncia de la Universidad Autónoma de Guadalajara, refiriendo como motivo de consulta «no puedo comer a gusto y siento pena por mi apariencia facial» se realizó estudio dentofacial completo. Se diagnosticó clase III esquelética ocasionada por hipoplasia maxilar y prognatismo mandibular, se determinó tratamiento orto-quirúrgico. El paciente y sus padres fueron informados sobre el tratamiento, riesgos, beneficios, ventajas y desventajas, duración de tratamiento, costos y cuidados a seguir. Una vez aceptado el plan de tratamiento, los objetivos fueron lograr clase I esquelética así como clase I canina y clase II molar bilateral, se indicó colocar Aparatología Roth 0.022", se le realizaron extracciones de las primeras premolares superiores, así como las etapas de alineación, nivelación y cierre de espacios, se trabajó en equipo con el Departamento de Cirugía, se obtuvo un exitoso tratamiento de ortodoncia prequirúrgica y cirugía maxilofacial (avance maxilar y retroposición mandibular), obteniendo como resultados clase I esquelética y clase I canina y clase II molar bilateral, devolviendo al paciente la función masticatoria y la seguridad en su persona por sentirse estéticamente aceptado ante la sociedad.

Key words: Class III, pre-surgical orthodontics, mandibular prognathism, maxillary hypoplasia, orthognathic surgery, bimaxillary surgery.

Palabras clave: Clase III, ortodoncia prequirúrgica, prognatismo mandibular, hipoplasia maxilar, cirugía ortognática, cirugía-bimaxilar.

INTRODUCTION

Angle's publication of the classification of malocclusions in the 1890's was a very important step in the development of orthodontics, since it did not only sub-classify the main types of malocclusion, but also described the first clear definition of normal occlusion. Angle postulated that the first upper molars were fundamental in the occlusion and that the upper and lower molars should be linked together so that the mesio-buccal cusp of the upper molar occludes with the buccal groove of the lower first molar. If the teeth were aligned in an evenly curved line of occlusion and this relationship between the molars exists, there would be a normal occlusion. Subsequently Angle described three types of malocclusion, based on the occlusal relationships of the first molars:

Class I: normal relationship of the molars, while the line of occlusion is incorrect by dental malposition, rotations or other causes.

Class II: lower molar located distally in to the upper, without specifying occlusion line.

* Student.

§ Professor.

Orthodontics Specialty, Autonomous University of Guadalajara (UAG).

© 2016 Universidad Nacional Autónoma de México, [Facultad de Odontología]. This is an open access article under the CC BY-NC-ND license (<http://creativecommons.org/licenses/by-nc-nd/4.0/>).

This article can be read in its full version in the following page:
<http://www.medigraphic.com/ortodoncia>

Class III: lower molar located mesially in relation to the upper molar, without specifying the occlusion line.¹

Grabner describes class III as true dento-skeletal dysplasias, where an anteroposterior relationship of the jaws in relation to the cranial base is recognized, with or without teeth irregularities.²

In the decade of the 1930's radiographs clearly showed that many class II and class III malocclusions were due to anomalies in intermaxillary relations and not only to teeth malposition.³

Class III occlusal relationship seems to be particularly common in Asian population (12%) and comparatively less frequent in Europeans (1.5-5.3%) and Caucasians of North America (1-4%).^{4,5}

The etiology is linked to hereditary factors influenced by the environment and according to their origin they are classified in skeletal, dental and/or functional.⁶

Class III malocclusions can often be present with mandibular prognathism, but these occlusal relations constitute only a part of a much larger syndrome. In fact, in class III patients almost any combination of poor growth of the maxilla and excessive development of the mandible can be found being the two equally probable.^{1,7}

Ellis and McNamara found in his study that a combination of maxillary retrusion and mandibular protrusion was the most common skeletal relationship, with a prevalence of 30% in class III adult patients. Maxillary retrusion with normal mandible had 19.5% predominance and a normal maxilla with mandibular protrusion represented 19.1% of patients.⁷

Determinants of occlusion, such as interocclusal distance, mastication movement and tooth-to-tooth relations vary for the different kinds of occlusion. The class III patient is subjected to changes in occlusal patterns because occlusal morphology is determined by the length and size of the mandible. Therefore, prognathism may be a feature responsible for class III malocclusion.⁸

To perform a suitable cephalometric analysis is essential to confirm the presumptive diagnosis. Determining the actual origin of the anomaly allows us to formulate an appropriate treatment plan, surgical or non-surgical, that responds to the demands of the patient and the clinician.⁹

According to Proffit the orthodontist is usually the key person in deciding the appropriate time to begin treatment plans that are located within one of the following categories: orthodontic treatment only, orthopaedic and orthodontic treatment (growth modification) and orthodontic-surgical treatment.¹

Indications for surgery are a problem too broad for orthodontics. The boundaries of orthodontic treatment

vary in function of the required dental movement (teeth can move more in some directions than in others) and the patient's age (limits for dental movement vary little or nothing with age, but growth can be modified only during the phase of active growth). It should be borne in mind that the discrepancy sets the limits of the changes in the hard tissues toward an ideal occlusion; provided that other limits linked to the priority goals of treatment were not implemented. The limitations set by the soft tissues tend to be a very important factor in the choice between orthodontic treatment or an orthodontic-surgical one.^{1,9}

Jakobsone, Stenvik and Espeland concluded in their study that bi-maxillary surgery (LeFort I and bilateral sagittal osteotomy) to correct skeletal class III malocclusions gives as a result the following aspects: 1. Good occlusal Stability, 2. The stability of the maxillae varies depending on the number and direction of the surgical movements, 3. The risk factors for the horizontal relapse of the mandible were the amount of repositioning and for the vertical relapse it was the posterior repositioning of the maxilla, 4. Dentoalveolar compensations contribute to the occlusal stability, hence the importance of orthodontic treatment after surgery and stabilization.¹⁰

There are reports in the literature about the negative effect that any facial disfigurement has on the mental and social well being of the individuals and this is clearly the reason why the majority of the patients are seeking orthodontic treatment. If improving facial appearance is the main goal of treatment, it makes sense that in addition to the jaws and teeth, changes in the nose and contours of the facial soft tissues should also be considered. It is therefore very important to provide counseling and psychological support to patients.^{1,11}

Nimhurchadhaen, Bhamrah and Ahmad in their study show that surgical patients turn to the Internet for supplementing information on their proposed treatment. This may suggest a possible gap in the information provided by the clinician. However, it is evident that patients use Internet forums to seek additional information, support and comfort from persons who have undergone a similar treatment. So, it is necessary that the clinicians make sure that the patients have access to the adequate and pertinent Internet resources.

CASE REPORT

Diagnosis and treatment plan

Patient of 15 years of age, male gender, without relevant medical history attended the clinic of

The panoramic radiograph evidenced the presence of the upper and lower third molars germs,

- Skeletal:
 - Correct the class III by orthodontics and orthognathic surgery, and achieve skeletal class I.
- Dental:
 - Coordinate arches for surgery.

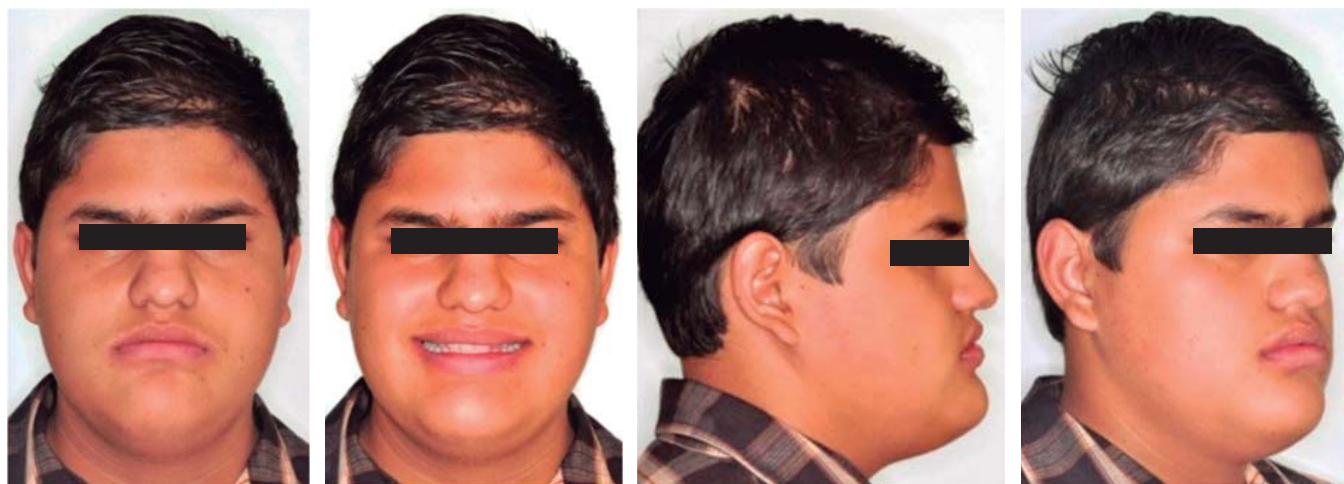

Figure 1. Initial facial photographs.

Table I. Discrepancy analysis for both arches.

[illegible]

- Achieve bilateral canine class I.
 - Procline lower incisors and retrocline upper incisors.
 - Correct upper and lower crowding.
 - Eliminate rotations.
 - Correct midlines.
- Soft tissues:
 - Improve profile.
 - Correct naso-labial and mento-lip angles.

Treatment Plan

It consisted of placement of conventional appliances, Roth technique 0.022" slot with bands in first and second upper and lower molars as well as upper premolar extractions. The stages of alignment, leveling and space closure (by retraction of the upper anterior segment) were carried out; the pre-surgical evaluation was performed together with the maxillofacial surgeon and the maxillofacial surgery was planned. Once the patient was operated he was received again in the clinic of orthodontics to perform the final stages of detailed, settlement and retention.

Treatment progress:

Treatment was initiated with Roth 0.022" slot conventional appliances placement with 0.014" NiTi arch wires in both arches, cinched only at the upper arch to avoid upper incisor proclination and left without cinching in the lower arch seeking proclination throughout the treatment (*Figure 3*).

After three months 0.016" NiTi arch wires were placed in both arches, with small loops (teeth #35-36 and 45-46) that worked as stops to leave the lower arch larger in the anterior zone and help proclination of the lower incisors. With these arches, the alignment stage was concluded. (*Figure 4*).

The patient was referred to perform the extractions of the first upper premolars on both sides (#14 and 24).

After two months, 0.016" × 0.016" stainless steel arch wires were placed in both arches, which performed the leveling and space closure stages. This last stage was carried out with the help of closed coils that were activated 2 mm per month (*Figure 5*).

Initially, only the upper canines were distalized in order to achieve canine class I, afterwards the lower arch was changed for a 0.018" NiTi with loops again to continue with the proclination.

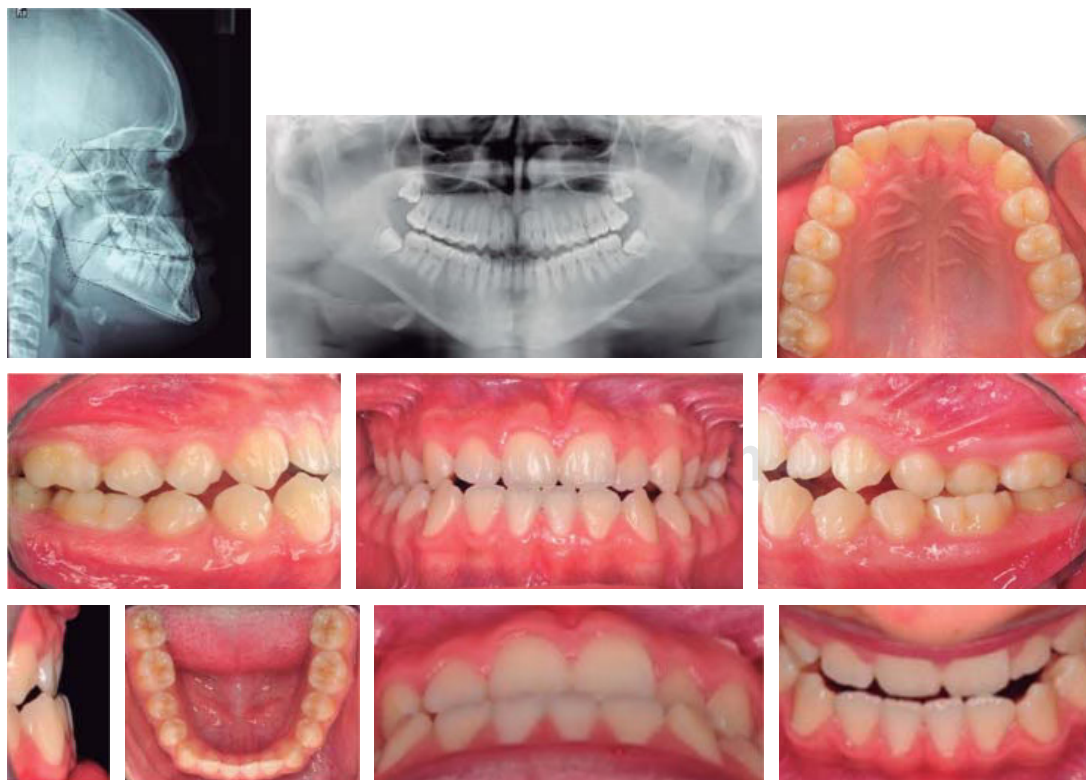
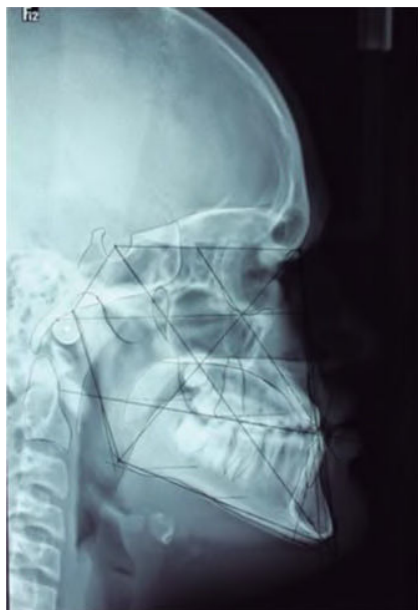
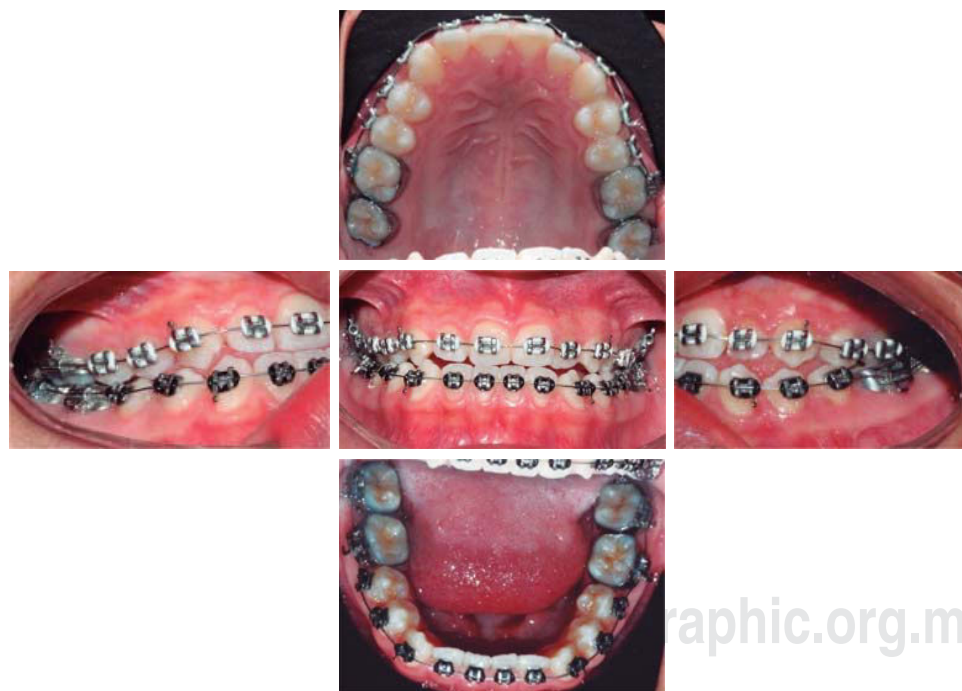Figure 2.

Initial radiographs and intraoral photographs.

**Table II.** Initial cephalometric values.

Steiner cephalometric analysis		
Angle	Normal value	Patient
SNA	82°	92
SNB	80°	96
ANB	2°	-4
GO-GN:S-N	32°	25
OCCL:S-N	14.1°	2
INTERINCISAL	131°	135
⊥ - N-A	4 mm	+4 mm
⊥ N-A	22°	28
T - N-B	4 mm	+3 mm
T N-B	25°	20
T GO-GN (IMPA)	93°	78
Others		
Witts	H -1 mm M 0 mm	-7 mm
⊥ - Maxillary plane	110°	123

**Figure 3.**

Fixed- appliance placement.

After three months, a lateral headfilm was obtained to assess the inclinations of the upper and lower incisors; the radiographs provided as a result that both the upper and lower incisor inclinations were within the normal values (*Figure 6*).

Retraction of the upper anterior segment was begun by placing hooks in the anterior zone so that aided by closed coils (14 oz/on each side), the upper extraction spaces were closed completely. In the lower arch, small diastemas created by the

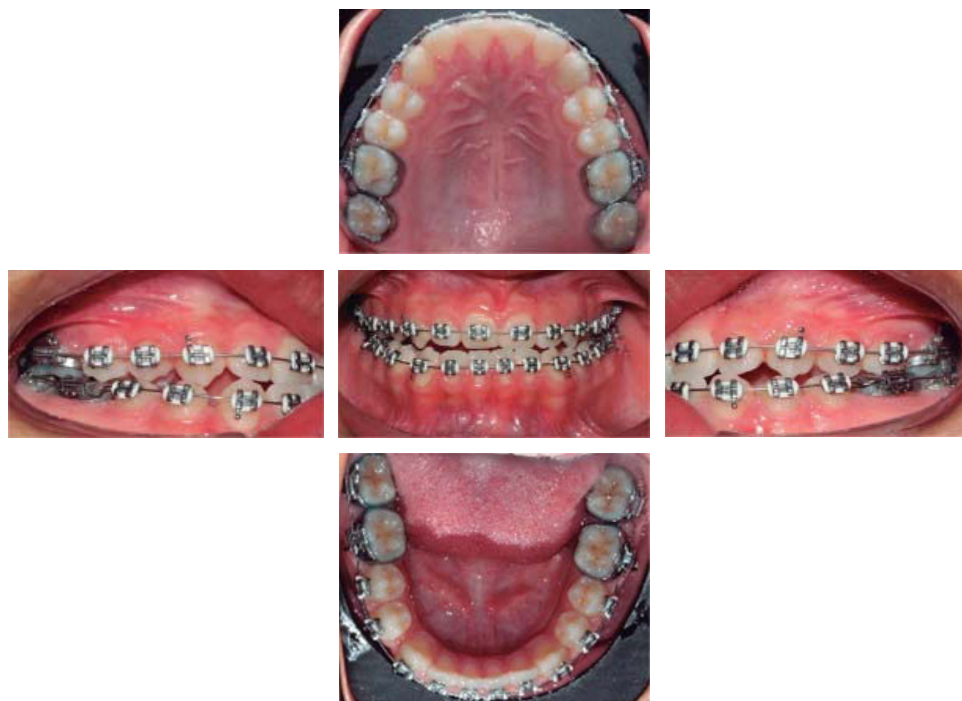


Figure 4.

Treatment progress photographs.
Alignment stage.

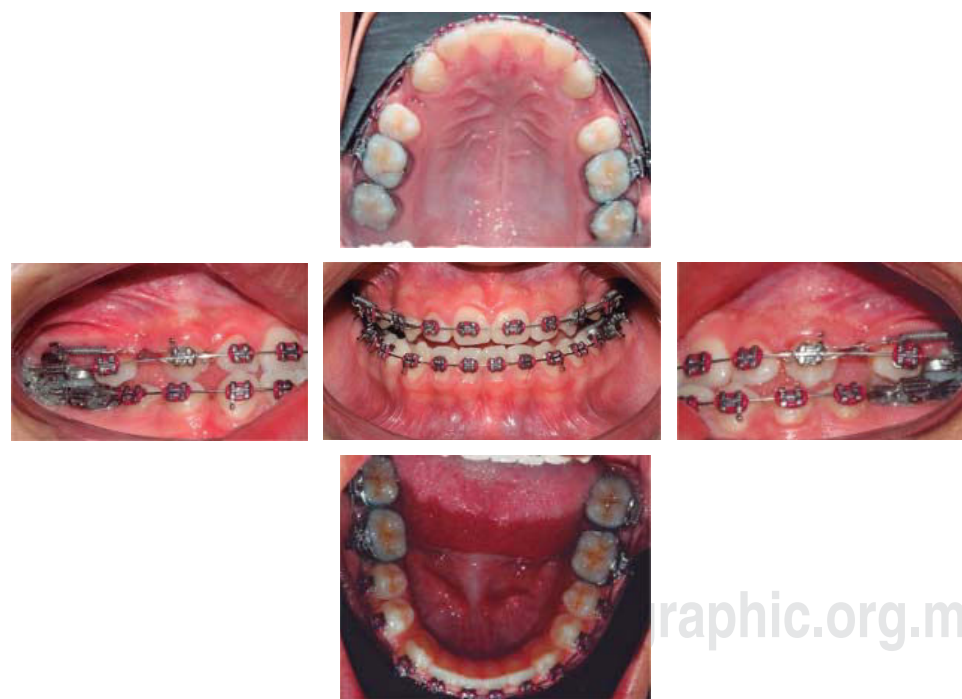

Figure 5.

Space closure stage.

proclination were closed using elastic string. The patient was instructed to extract the lower third molars.

After two months the spaces of both arches were closed completely 0.016" × 0.022" NiTi arch wires

were placed on both arches and impressions were taken to assess arch coordination which was very favorable (*Figure 7*).

0.017" × 0.025" stainless steel arch wires were placed and the patient was referred to the maxillofacial

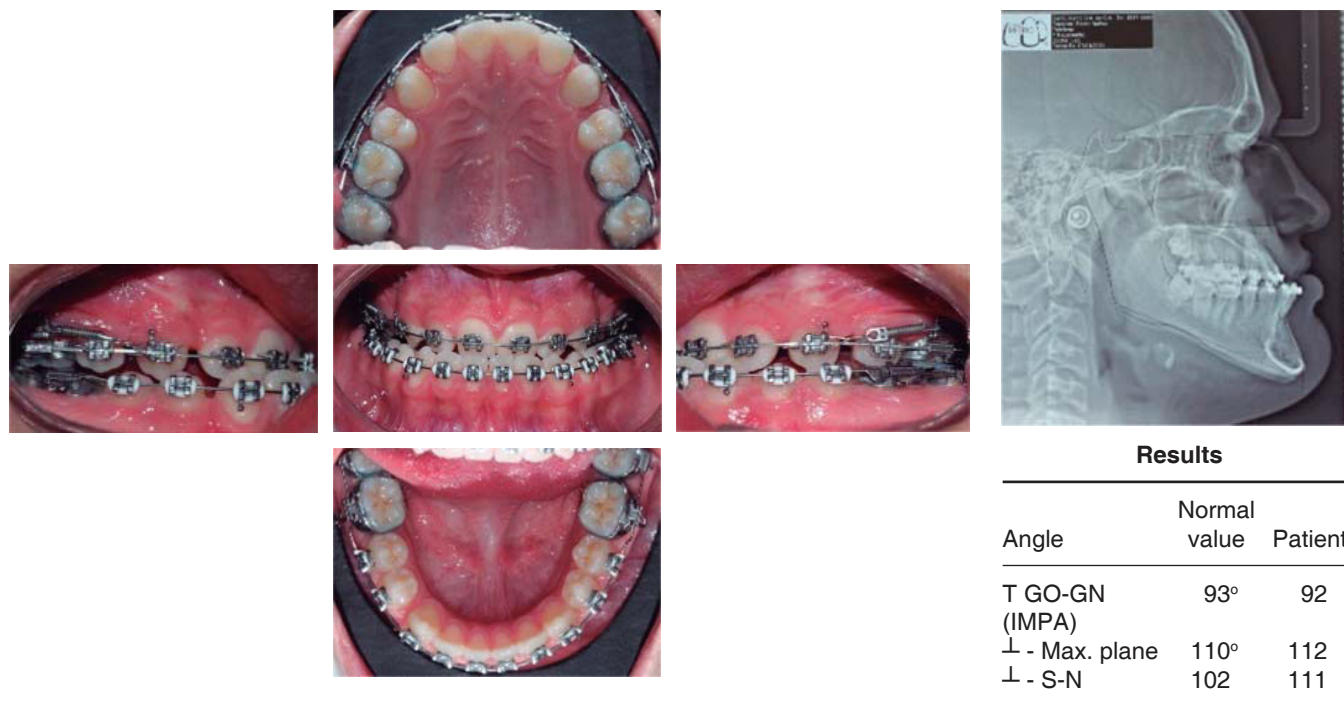


Figure 6. Class I canine relationship and control lateral headfilm to assess incisor inclination.

surgeon for an assessment. After three months surgical arch wires were placed.

The maxillofacial surgeon instructed the patient to obtain full digital records (panoramic X-Rays, lateral headfilm and intra and extra oral photographs) before the surgery (*Figure 8*).

Four days prior to the surgery, the soft tissue analysis (Bell), surgical prediction (5 mm maxillary advancement and 3 mm mandibular retrusion), models surgery and the elaboration of the two surgical splints (intermediate and final) were all performed in conjunction with the maxillofacial surgeon.

After 16 months the orthognathic surgery was performed in which a 5 mm maxillary advancement was made and a mandibular retrusion of 3 mm (*Figure 9*). The patient was told to use intermaxillary elastics (1/8", 3.5 oz squirrel), to overcome the muscular forces.

One month after the surgery, the patient attended the clinic of orthodontics, where the surgical arches were withdrawn and coaxial 0.019" × 0.025" stainless steel arch wires were placed, still with intermaxillary elastics in the posterior area to assist in the settlement of the occlusion. A panoramic X-Ray was indicated to evaluate root parallelism (*Figure 10*).

A 0.017" × 0.025" TMA arch wire was placed in the upper arch, the bracket of tooth #11 was repositioned

and in lower arch, a 0.017" × 0.025" stainless steel arch wire was placed with progressive positive torque on the left side (teeth #33-37).

After three months 0.017" × 0.025" stainless steel arch wires were placed in both arches, cinched, and crossed intermaxillary elastics (1/8", 3.5 oz) were indicated on the left side, to improve the posterior occlusion. Final panoramic radiograph and lateral headfilm were obtained (*Figure 11*).

After 22 months of treatment and once the objectives were achieved, it was decided to remove the appliances. The patient was referred to the periodontist for prophylaxis and the retention stage started with a 3-3 lower fixed retainer and a removable circumferential retainer in the upper arch to help close the remaining spaces of the bands (*Figure 12*).

RESULTS

A skeletal class I was obtained along with a canine class I and a molar class II, favorable inclinations of the upper and lower incisors, a normal overjet and overbite, midlines centered, straight profile, facial harmony, lips on the same plane, friendly smile, and an adequate masticatory function (*Figure 13*), as well as important changes in the cephalometric values (*Table III*).

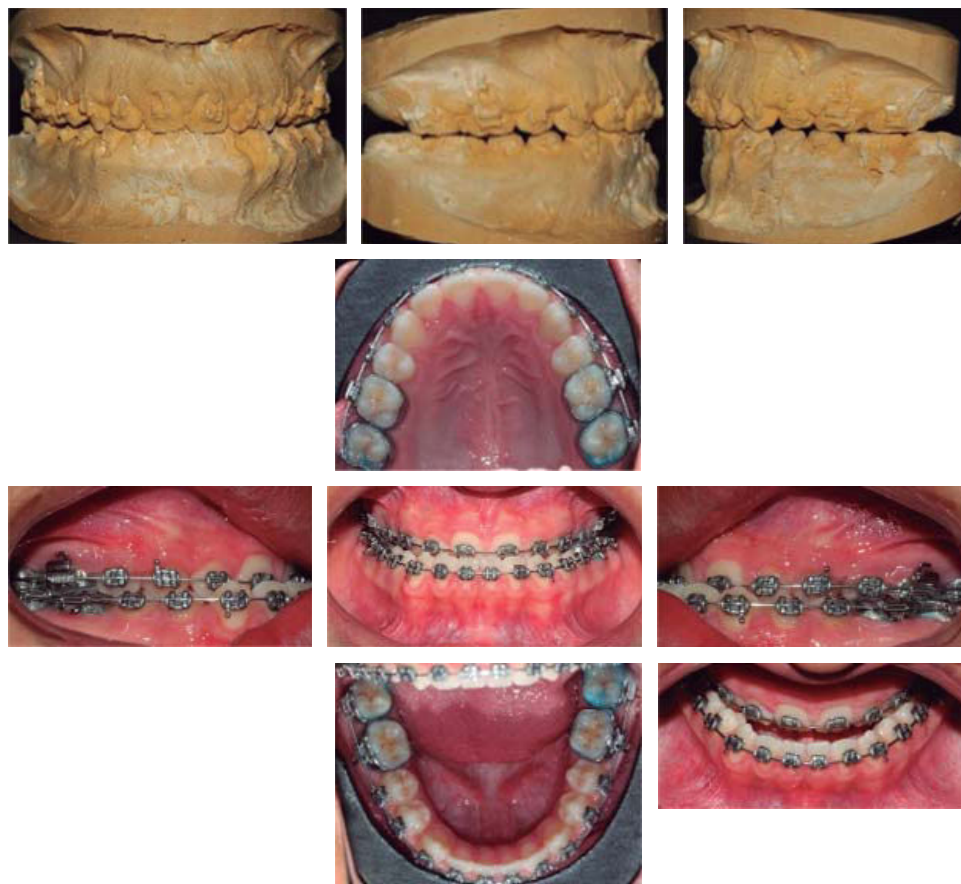

Figure 7.

Control models for assessing the occlusion and intraoral photographs with 0.016" x 0.022" NiTi arch wires.

DISCUSSION

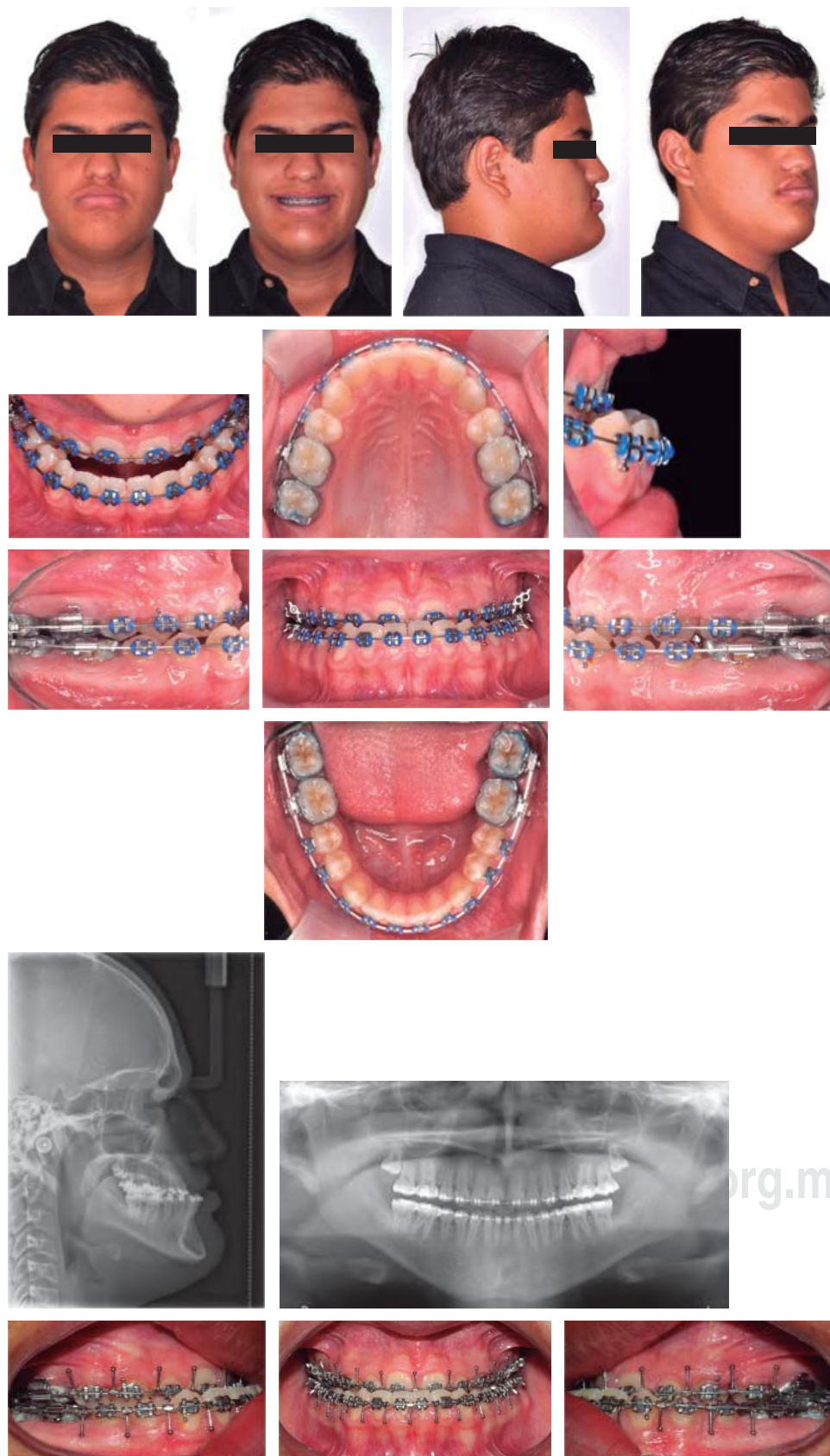
Jakobsone, Stenvik and Espeland concluded in their study that the risk factors for horizontal mandibular relapse were the amount of retrusion and vertical and posterior repositioning of the maxilla. Stability increased in patients with little or no posterior impaction of the maxilla.¹⁰ In the case of the patient hereby presented, a 5 mm maxillary advancement was conducted as well as a mandibular retroposition of 3 mm. Seven months after surgery no sign of relapse has been found, the case has remained stable. These results support the study in that stability is due in part to the fact that maxillary impaction was not performed, but we also believe that it was due to a good surgical and orthodontic management.

We agree with the research of Dr. Cho in that the postsurgical occlusal results depend on the precision and stability of the surgery. Dentoalveolar compensations contribute to occlusal stability, stressing the importance of finishing with a post-surgical and stabilization orthodontic phase.¹²

Proffit, Jackson and Turvey argue in their study that the characteristics of patients who seek and accept orthognathic surgery appear to be changing in the twenty-first century. The percentage of class III patients increased from 35% to 54% and the percentage of class II patients was reduced from 59% to 41%, whereas the percentages of long face and asymmetry showed little change. The decrease in class II patients was an accentuation of a long-term trend; the increase in class III patients occurred only after the turn of the century.¹³

Nicodemus, Pereira and Ferreira concluded that female patients presented increased self-esteem and decreased depressive symptoms due to the surgical intervention; while male patients showed no alteration in their self-esteem and depression with the surgical intervention. In our clinical case, the patient showed positive changes in his behavior after the surgery.¹⁴

Ertas and Kilinc believe that the level of quality of life related to the oral condition of surgically treated patients, may reach those of individuals without a dentofacial deformity, once the effects of the treatment

**Figure 8.**

Pre-surgical records and 0.017" x 0.025" SS surgical arch wires.

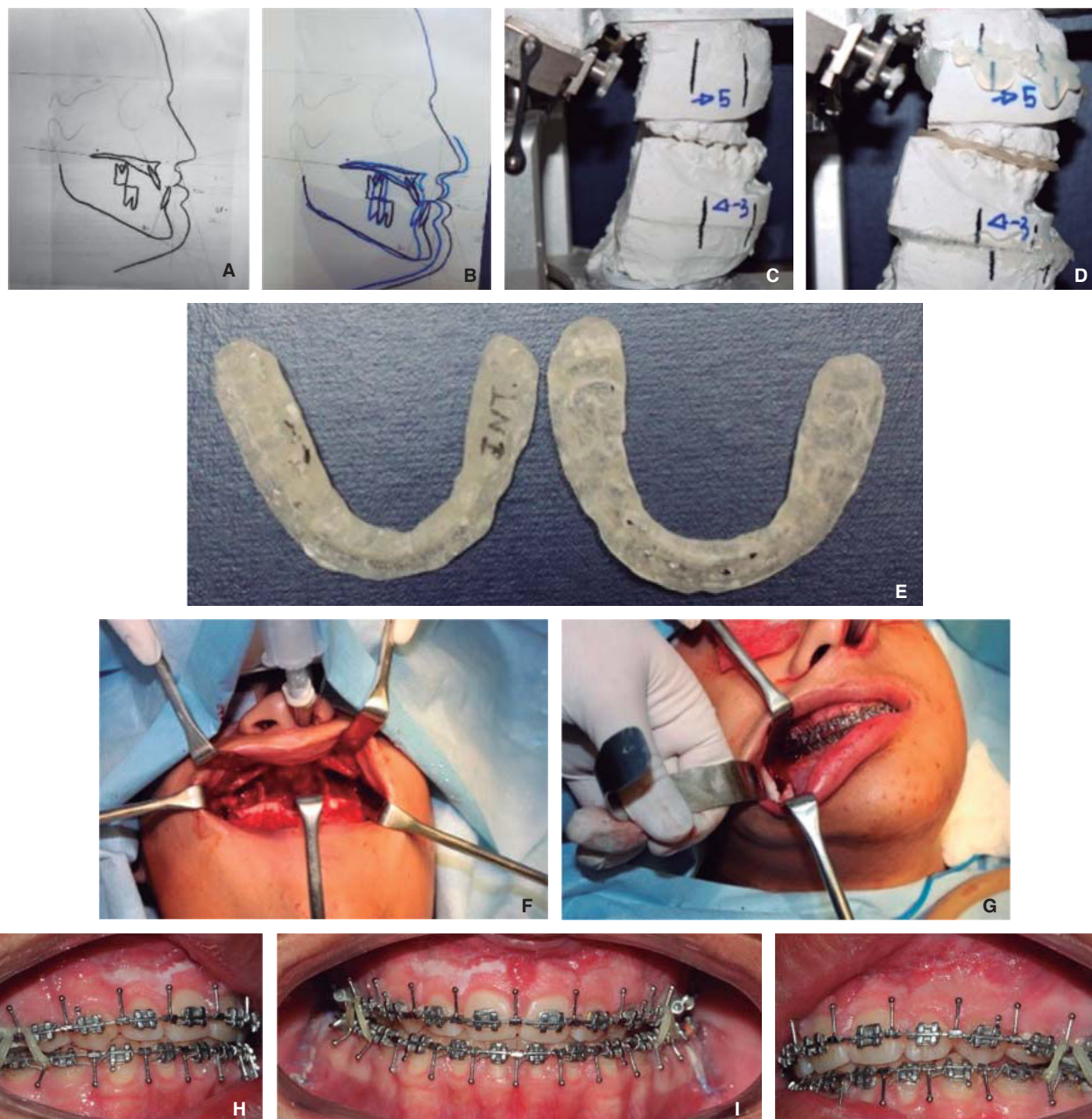


Figure 9. Bell's soft tissue analysis (A), surgical prediction (B), models surgery (C y D), surgical splints (E) and photographs during (F y G) and after (H, I, J) the surgery.

process have disappeared. The latter statement coincides with the changes that the patient hereby presented some time after surgery.¹⁵

At the start of treatment, it was suggested to perform surgery in both jaws, assess the results and if necessary, perform a second surgical intervention to retrude the chin and aesthetically achieve a more

straight profile, but when the patient saw the final results he did not think it was necessary.

CONCLUSIONS

When the orthodontic problems in adult patients are so serious that they were not modified during

the growth stage, when it is demonstrated that it is a skeletal problem and not a dental one and that not even camouflage is a good solution, the only possible treatment is surgical realignment of the jaws and the relocation of the dentoalveolar segments.

In this kind of patients, orthognathic surgery is not a substitute for orthodontics, but rather an

interdisciplinary complement where there must be coordination with other dental treatments in order to achieve overall acceptable results. Currently the spectacular advances in medical science have made it possible to combine these treatments to correct many serious problems with the best results.

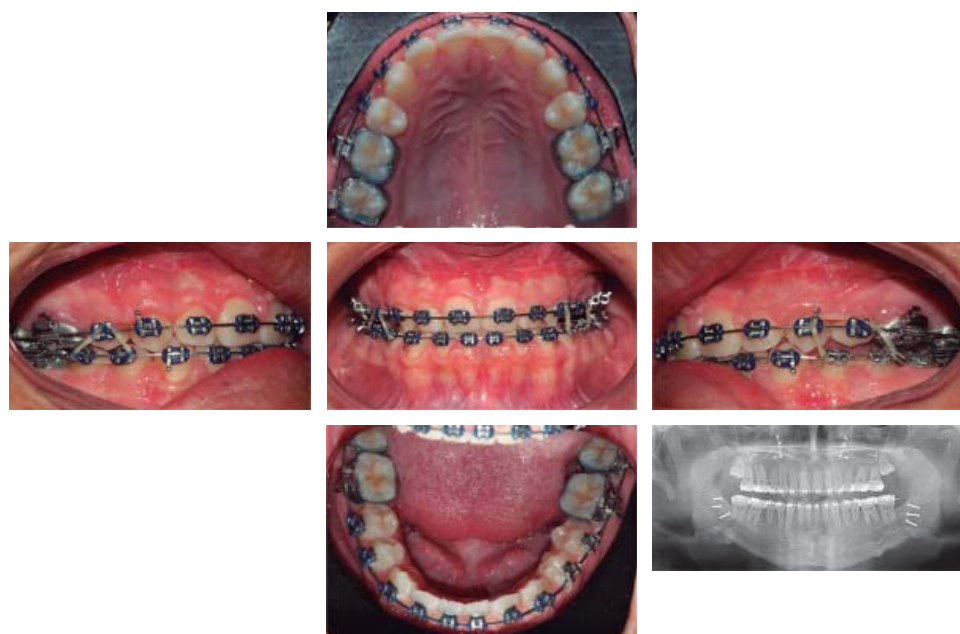


Figure 10.

Post-surgical photographs with 0.019 × 0.025" stainless steel coaxial archwires 3/16", 3.5 oz settling elastics and panoramic radiograph to assess root parallelism.

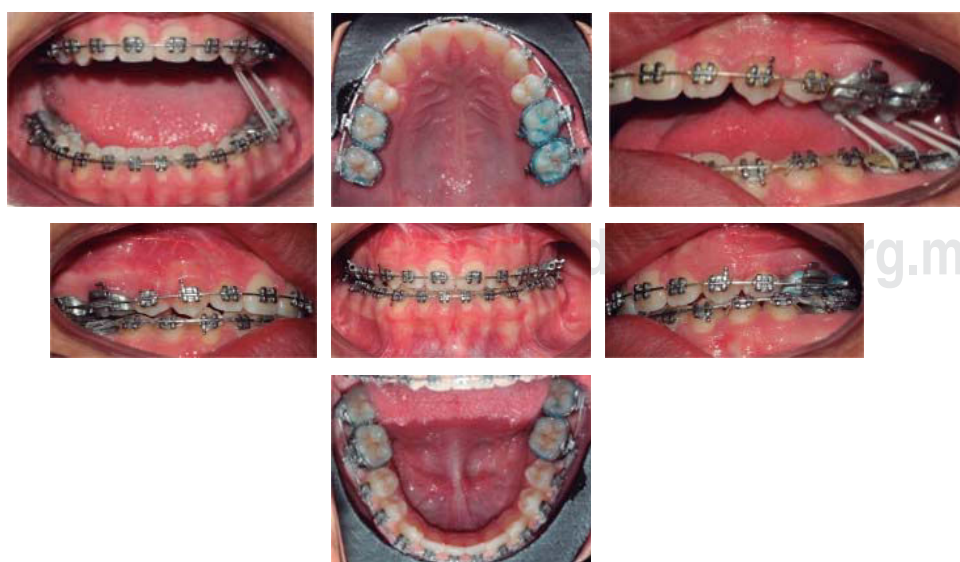

Figure 11.

Photographs with 0.017" × 0.025" SS arch wires and 1/8", 3.5 oz crossed elastics on the left side.

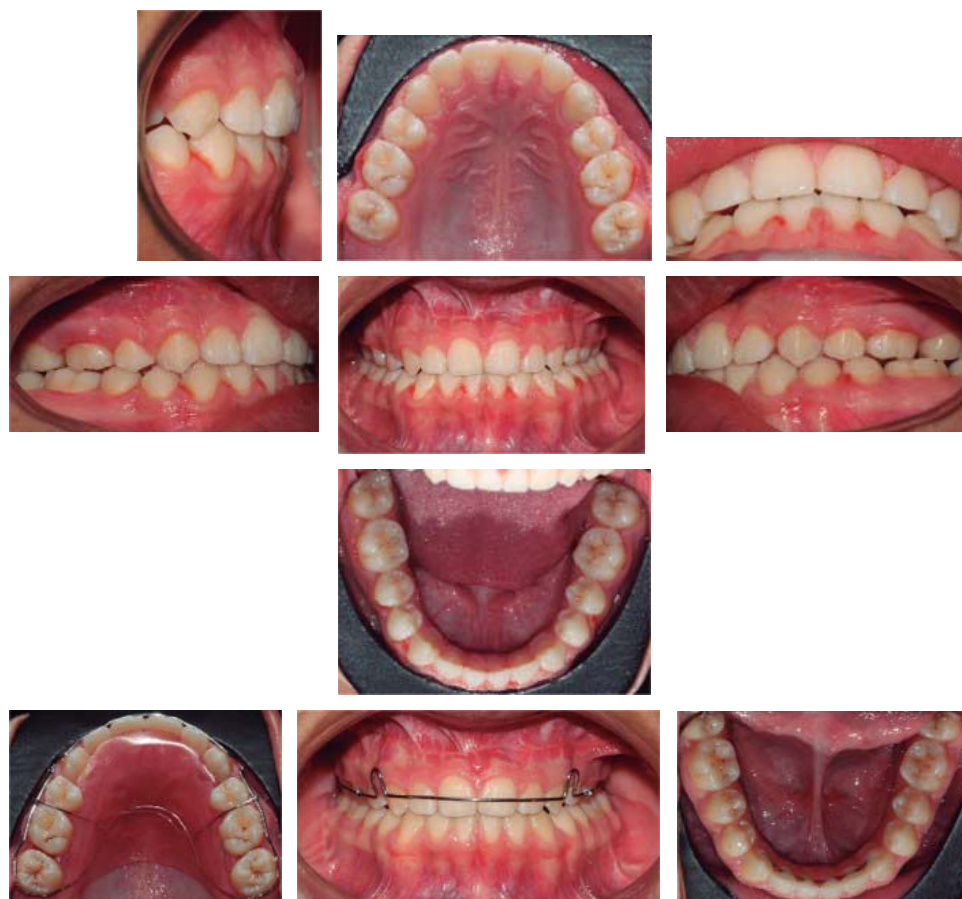
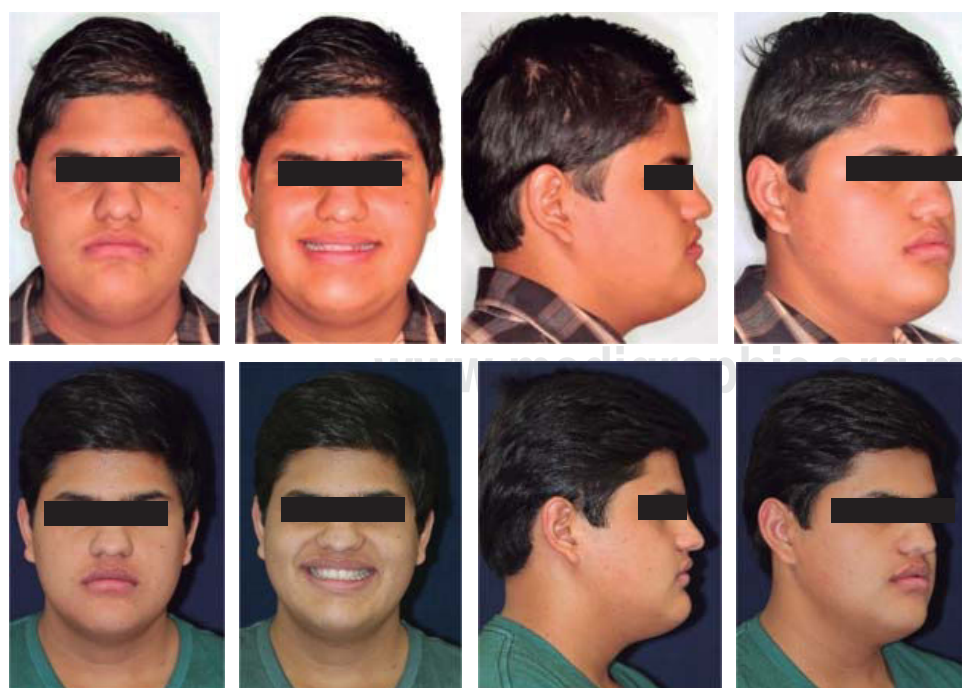
Figure 12.

Final photographs and retention: circumferential retainer on the upper arch and fixed on the lower.

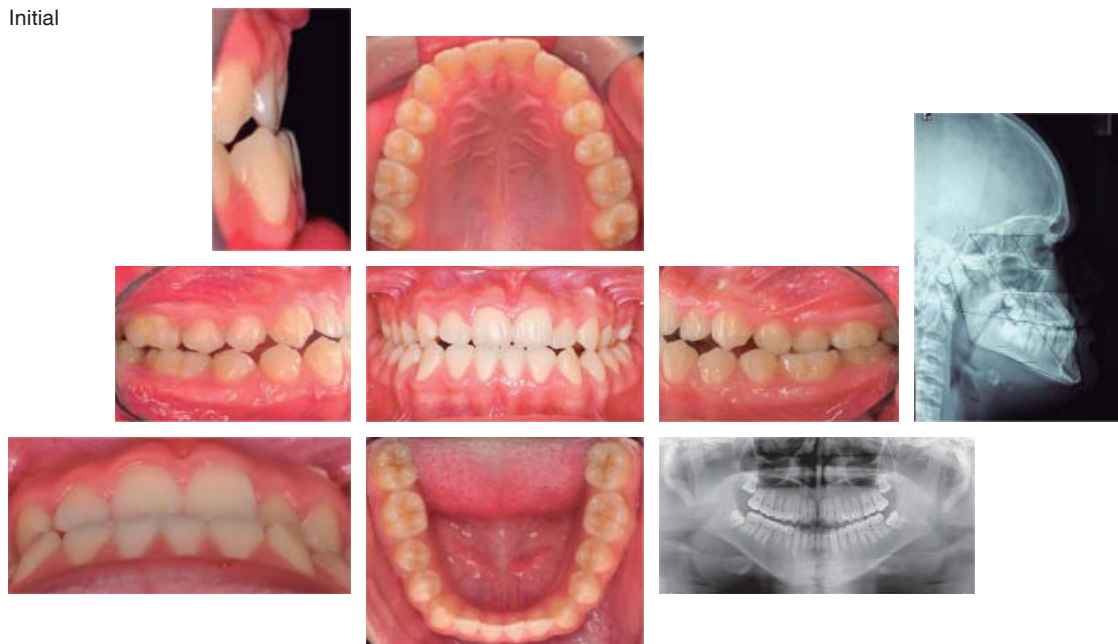

Initial

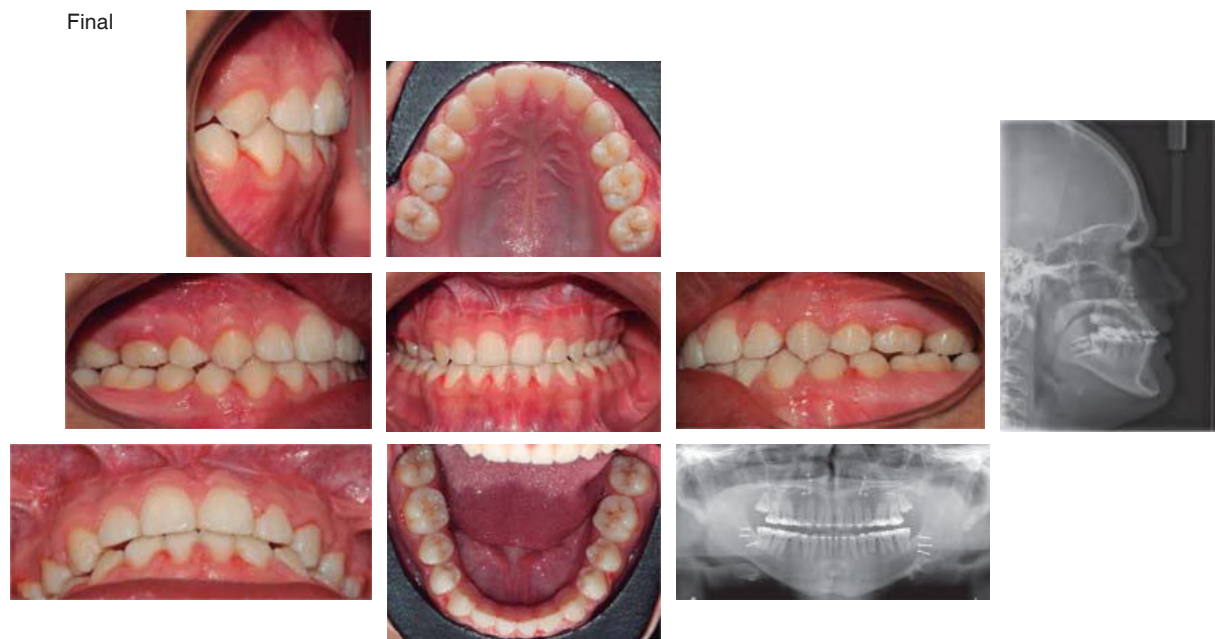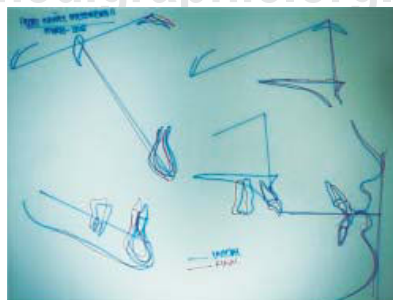
Final

Continue figure 13.

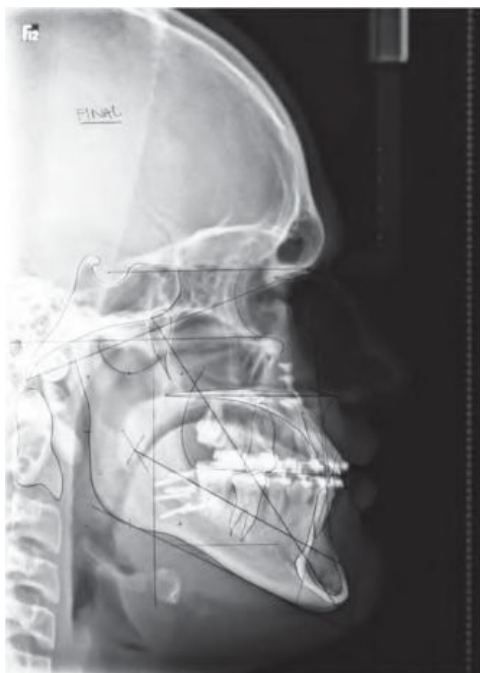Initial



Final

www.mediagraphic.org.mx**Figure 13.**

Comparative facial and intraoral photographs, initial and final panoramic radiographs, lateral headfilms and superimposition.

**Table III.** Initial and final cephalometric values.

Steiner's cephalometric analysis			
Angle	Norm	Initial	Final
SNA	82°	92	94
SNB	80°	96	93
ANB	2°	-4	1
GO-GN: S-N	32°	25	26
OCCL: S-N	14.1°	2	3
Interincisal	131°	135	135
⊥ - N-A	4 mm	+4 mm	+4 mm
⊥ y N-A	22°	28	23
T - N-B	4 mm	+3 mm	+2 mm
T y N-B	25°	20	20
T y GO-GN (IMPA)	93°	78	80
Others			
WITTS	H -1 mm M 0 mm	-7 mm	-3 mm
⊥ -Maxillary plane	110°	123	119

REFERENCES

1. Proffit WR. *Ortodoncia contemporánea*. 4a. ed. Barcelona, España. Elsevier Mosby, 2008.
2. Graber TM. *Ortodoncia principios y técnicas actuales*. 4a. ed. Madrid, España. Elsevier, 2006.
3. Gregoret J. *Ortodoncia y cirugía ortognática diagnóstico y planificación*. 4a. ed. Madrid, España. ESPAXS, S.A. 2008.
4. Baccetti T, Reyes BC, McNamara JA Jr. Gender differences in class III malocclusion. *Angle Orthod*. 2005; 75: 510-520.
5. Xue SA, Lam CW, Whitehill TL, Samman N. Effects of class III malocclusion on young male adults' vocal tract development: a pilot study. *J Oral Maxillofac Surg*. 2011; 69: 845-852.
6. Quintero Y. Relación esquelética clase III con factor genético predominante. Reporte de caso clínico. *Revista CES Odontología*. 2007; 20 (2): 43-50.
7. Guyer E, Ellis EE 3rd, McNamara JA Jr, Behrents RG. Components of class III malocclusion in juveniles and adolescents. *Angle Orthod*. 1986; 56 (1): 7-30.
8. Singh GD, McNamara JA Jr, Lozanoff S. Mandibular morphology in subjects with class III malocclusions: finite-element morphometry. *Angle Orthod*. 1998; 68 (5): 409-418.
9. Burns NR, Musich DR, Martin C, Razmus T, Gunel E, Ngan P. Class III camouflage treatment: What are the limits? *Am J Orthod Dentofacial Orthop*. 2010; 137 (9): .e1-9.e13.
10. Jakobsone G, Stenvik A, Sandvik L, Espeland L. Three-year follow-up of bimaxillary surgery to correct skeletal Class III malocclusion: stability and risk factors for relapse. *Am J Orthod Dentofacial Orthop*. 2011; 139: 80-89.
11. Bhamrah G, Ahmad S, NiMhurchadha S. Internet discussion forums, an information and support resource for orthognathic patients. *Am J Orthod Dentofacial Orthop*. 2015; 147 (1): 89-96.
12. Cho H. Effect of rigid fixation on orthodontic finishing after mandibular bilateral sagittal split setback: the case for miniplate monocortical fixation. *J Oral Maxillofac Surg*. 2012; 70: e310-e321.
13. Proffit WR, Jackson TH, Turvey TA. Changes in the pattern of patients receiving surgical-orthodontic treatment. *Am J Orthod Dentofacial Orthop*. 2013; 143 (6): 793-798.
14. Nicodemo D, Pereira MD, Ferreira LM. Self-esteem and depression in patients presenting angle class III malocclusion submitted for orthognathic surgery. *Med Oral Patol Oral Cir Bucal*. 2008; 13 (1): E48-51.
15. Kilinc A, Ertas U. An assessment of the quality of life of patients with class III deformities treated with orthognathic surgery. *J Oral Maxillofac Surg*. 2015; 73 (7): 1394.e1-5. doi: 10.1016/j.joms.2015.02.019.

Mailing address:

Alejandra Vázquez Valencia

E-mail: alejandra.vazval@gmail.com