



# Esthetic assessment of class III patients before and after surgical treatment according to the divine proportion

## *Valoración estética en pacientes clase III antes y después del tratamiento quirúrgico de acuerdo a la proporción divina*

Evelyn Cristina Carrera Garrido,\* Miguel Piña Reynoso,<sup>§</sup> Gabriel Sáez Espínola,<sup>||</sup> Abigail Flores Ledesma<sup>||</sup>

### ABSTRACT

This study was designed to aesthetically assess class III patients before and after surgical treatment according to the divine proportion. Class III or mesio-occlusion, is characterized by the mesial relationship of the mandibular dental arch with respect to the maxillary dental arch taking as reference the mesial buccal cusp of the upper first molar which occludes mesial to groove of the lower first molar. This pathology greatly compromises facial esthetics and psychosocial status and adversely affects the self-esteem of those who suffer from it. It is one of the most difficult challenges that the clinician can face; if left untreated it can progress to a degree so severe, that in most cases, the only treatment option is orthognathic surgery in adulthood. Surgical techniques had their origin in the twentieth century from then on, they have been modified into versatile and predictable methods for the correction of maxillofacial malformations. The aesthetic problem is the main reason for consultation in orthodontics. The divine proportion is being studied more and more every day for diagnostic and therapeutic purposes related to facial aesthetics. **Materials and methods:** Twenty patients were included in the sample for this study. Pre and post-treatment cephalograms and photographs (scale 1.1) were obtained. Seven angular measurements were taken from the pre/post-treatment cephalograms and seven linear measurements were obtained from frontal photographs. **Results:** An inter-class correlation coefficient was conducted as calibration analysis in the measured proportions as well as a Student's t-test for related samples. **Conclusions:** It was considered that in twenty-eight studied measurements, sixteen presented a statistically significant difference approximating to the golden number after surgical treatment in class III patients.

### RESUMEN

Este estudio fue diseñado para valorar estéticamente los pacientes clase III antes y después del tratamiento quirúrgico de acuerdo a la proporción divina. La clase III o mesioclusión, se caracteriza por la relación mesial de la arcada dentaria mandibular con respecto a la maxilar tomando como referencia la cúspide mesiovestibular del primer molar superior ocluyendo mesial al surco del primer molar inferior. Esta patología compromete mucho la estética facial y el estado psicosocial, que influye desfavorablemente en la autoestima de quien lo padece. Constituye uno de los retos más difíciles con los que se puede encontrar el clínico, si se dejan sin tratar pueden avanzar a un grado tan severo, que en la mayoría de los casos, la única alternativa de tratamiento se reduce a intervenciones de cirugía ortognática en edad adulta. Las técnicas quirúrgicas tuvieron su origen en el siglo XX. A partir de entonces, han sido modificadas hasta convertirlas en métodos versátiles y predecibles en la corrección de malformaciones maxilofaciales. La afectación estética es el principal motivo de consulta de los pacientes de Ortodoncia. La proporción divina está siendo estudiada cada día más, con fines diagnósticos y terapéuticos relacionados con la estética facial. **Material y métodos:** Veinte pacientes se incluyeron en la muestra de este estudio, cefalografías laterales y fotografías pre-/post-tratamiento (escala 1.1), siete razones angulares se midieron pre/post-tratamiento en cefalografías laterales y siete medidas lineales fueron medidas desde fotos frontales. **Resultados:** Se realizó el coeficiente de correlación interclase como análisis de calibración, en las proporciones medidas. Así como la prueba T-Student para muestras relacionadas. Se marca con un asterisco (\*) los grupos con diferencias estadísticamente significativas ( $p < 0.05$ ). **Conclusiones:** Consideramos de que en veinte y ocho razones estudiadas, diez y seis se diferenciaron de forma estadísticamente significativa, acercándose al número áureo después del tratamiento quirúrgico en pacientes clase III.

**Key words:** Divine proportion, class III patients, surgical treatment.

**Palabras clave:** Proporción divina, pacientes clase III, tratamiento quirúrgico.

### BACKGROUND

Leonardo de Pissa published «Liber Abacci», a mathematical treatise which showed the Fibonacci sequence, 1, 1, 2, 3, 5, 8, 13, 21, 34, 55, 89, 144... and so on to the infinite. When adding the first number to the second it always sums the third (e.g.  $1 + 1 = 2$ ,

\* Student of the Orthodontics Specialty.

§ Professor of the Faculty of Dentistry.

|| Doctor of Dental Science, Dental Materials Laboratory of the Faculty of Dentistry, National Autonomous University of Mexico.

|| Master of Dental Science, Dental Materials Laboratory of the Faculty of Dentistry, National Autonomous University of Mexico.

This article can be read in its full version in the following page:  
<http://www.medigraphic.com/ortodoncia>

1 + 2 = 3, 2 + 3 = 5, etc.) and while the succession moves forward when one number is divided between the previous it gets close to 1,618, so that he not only defined the golden number, but also proved that this ratio rules nature.<sup>1</sup>

Fray Lucca Paccioli published «Divine Proportion» with illustrations of Leonardo da Vinci. There, he applied the Fibonacci succession to the straight line and therefore to geometry where the smallest part fits the bigger 1,618 times and at the same time the greater part fits in the bigger 1,618 times.<sup>2</sup>

Vitruvius tried to illustrate the human body according to the divine proportion by placing it within the pentacle. Later, Leonardo da Vinci, who had a great interest in the topic, resumed Vitruvius work and payed homage in his work «The Man of Vitruvius», where he placed the human body in a circle and a square that shows how balanced and in divine proportion it is.<sup>3</sup>

Subsequently, Robert Ricketts published the article «The Golden Divider» in which he talks about an instrument that measures the divine proportion. In «The biologic significance of the divine proportion and Fibonacci series», he suggested several facial and cephalometric measurements that a face should have to be considered aesthetic: proportion, harmony and therefore health.<sup>4,5</sup>

Nowadays, Stephan Marquardt has conducted several studies in aesthetic faces, especially in actresses and actors that appear in magazine covers, and has created his «Golden Decagon Mask», which is a mask formed by divine proportions that has been adapted to different ethnic groups from around the world.<sup>6</sup>

On account of the aforementioned, surgeons began to assess proportions and the beauty of the human face using the «golden proportion». Many artists have made and still make reference to the «Divine Proportion» as one which achieves a balance of forms emphasizing its aesthetic value.<sup>7</sup>

Since orthognathic surgical treatments act directly over the bone that supports the teeth, these dental and bone movements have an impact on the patient's face which provides an esthetic improvement.<sup>8</sup> Each year in the Department of Orthodontics of the National Autonomous University of Mexico a substantial number of orthodontic-surgical cases are finished but the aesthetic aspect of treatment is considered rather subjectively except for some cephalometric measurements.

The aim of this study was to aesthetically assess class III patients before and after surgical treatment according to the divine proportion.

## MATERIALS AND METHODS

For this study, files belonging to the Department of Orthodontics of the National Autonomous University of Mexico from the period 2010-2013 were obtained.

Initial and post-surgical treatment frontal photographs and cephalograms were searched for and printed on a scale of 1:1. They were measured manually. To obtain the ratio the following first-degree equation was used:

$$1 \times \text{Larger distance} / \text{Smaller distance that results in } 1.618$$

The measurements used in this study were the ones suggested by Robert M. Ricketts and MatylaGhyka presented in the *annex 1 and 2*.

The interclass correlation coefficient was used as a calibration analysis (0.89-0.95) and the Student's t test for related samples.

## RESULTS

Paired samples were analyzed to describe the relations between the tracings of the initial and final cephalograms/photographs on each variable (T-test, mean, standard deviation and mean standard error).

An analysis of the paired samples test was conducted on the relations of the average differences between the two cephalograms/photographs for each variable (mean, standard deviation with a confidence interval of 95%).

The results showed that in the angular ratios there were statistically significant differences between variables (mandibular body length: mandibular ramus length, gnathion-center of cranium: center of cranium-gonion, gnathion-anterior nasal spine plane-center of the condyle: anterior nasal spine plane-center of cranium, menthon-palatal plane: palatal plane-eye canthus, pogonion-lower lip: lower lip-point A) before and after surgical treatment but not in the variables (gonion-geometric center of the ramus: geometric center of the ramus-pogonion, pogonion-point a: point A-Frankfort) (*Figures 1 and 2*) ( $p > 0.05$ ).

Likewise, it was observed that there were statistically significant differences in the facial ratios: in the variable (Chin –wing of the nose: wing of the nose - bipupilarplane, bipupilar plane-labial commissure: labial commissure-chin) and not in the variables (bipupilar plane-chin: trinchon- bipupilar plane, trinchon-wing of the nose: wing of the nose-chin, chin-labial commissures: labial commissures –wing of the nose, maximum head height: maximum head width, bipupilar plane-chin: wing of the nose-chin) (*Figures 3 and 4*) ( $p > 0.05$ ).

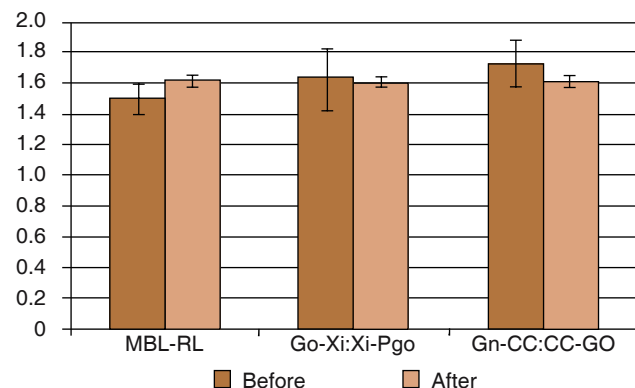
## DISCUSSION

Divine proportion has been known since ancient times; it was widely used in architecture and art, after having been studied and described by many artists, philosophers and mathematicians. This study makes reference to the golden proportion, especially to its relationship with

aesthetics, as to facial harmony, in skeletal class III patients before and after surgical treatment.

Ghyka<sup>9</sup> (1977) and Ricketts<sup>10</sup> (1982) introduced an individualized cephalometric analysis to study divine proportion in dentistry. Few authors reported on the divine proportion with respect to surgical treatment of class III patients. Baker & Woods<sup>8</sup> (2001) studied

Mean	Before		S.D.	Before	
	Before	After		Before	After
MBL: RL	1.5015	1.62		0.10027725	0.036273813
Go-Xi:Xi-Pgo	1.631	1.615		0.19686758	0.033007176
Gn-CC: CC-GO	1.736	1.621		0.15645413	0.0362593

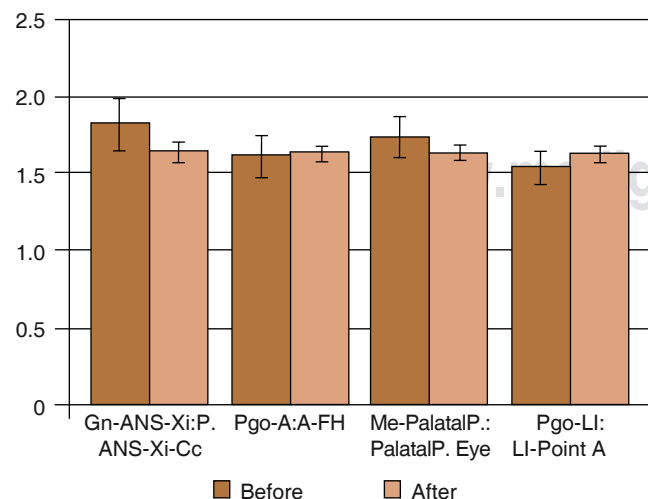


Mandibular body length:  
mandibular ramus length.  
Gonion-geometric center of  
the ramus: geometric center  
of the ramus-pogonion.  
Gnathion-center of cranium:  
center of cranium-gonion.

**Figure 1.**

Angular measurements. Paired T test  $p < 0.05$ .

Mean	Before		S.D.	Before	
	Before	After		Before	After
Gn-ANS-Xi: P. ANS-Xi-Cc	1.8265	1.651		0.16965212	0.070255174
Pgo-A: A-FH	1.622	1.635		0.13881453	0.047183851
Me-Palatal P.: Palatal P.-Eye Cant.	1.7405	1.6405		0.12987747	0.046393625
Pgo-li: li-Point A	1.5475	1.6355		0.11616119	0.044541524



Gnathion-anterior nasal spine  
plane-center of condyle:  
anterior nasal spine  
plane-center of cranium.  
Pogonion-point A: point  
A-Frankfort.  
Menthon-palatal plane: palatal  
plane-eye canthus.  
Pogonion-lower lip: lower  
lip-point A.

**Figure 2.**

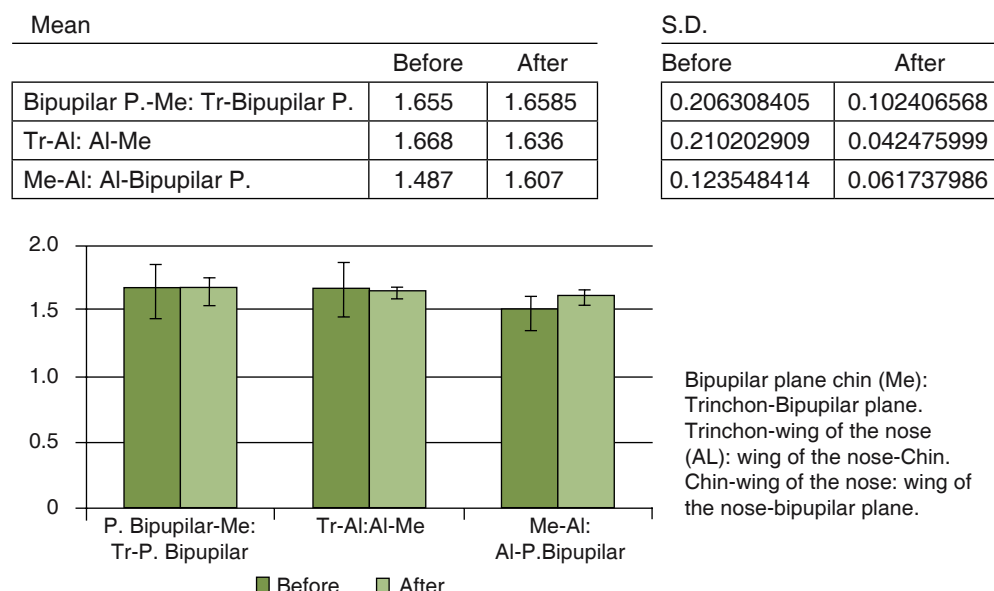
Paired T test  $p < 0.05$ .

divine proportion associating orthodontic treatment with orthognathic surgery.

The results of this study agree with Ricketts,<sup>10</sup> (1982), Field<sup>11</sup> (1987) and Learreta<sup>12</sup> (1999) in stating that orthodontists must seek a stable and functional occlusion to obtain a balanced and aesthetically pleasing facial profile. Likewise, the authors agree with

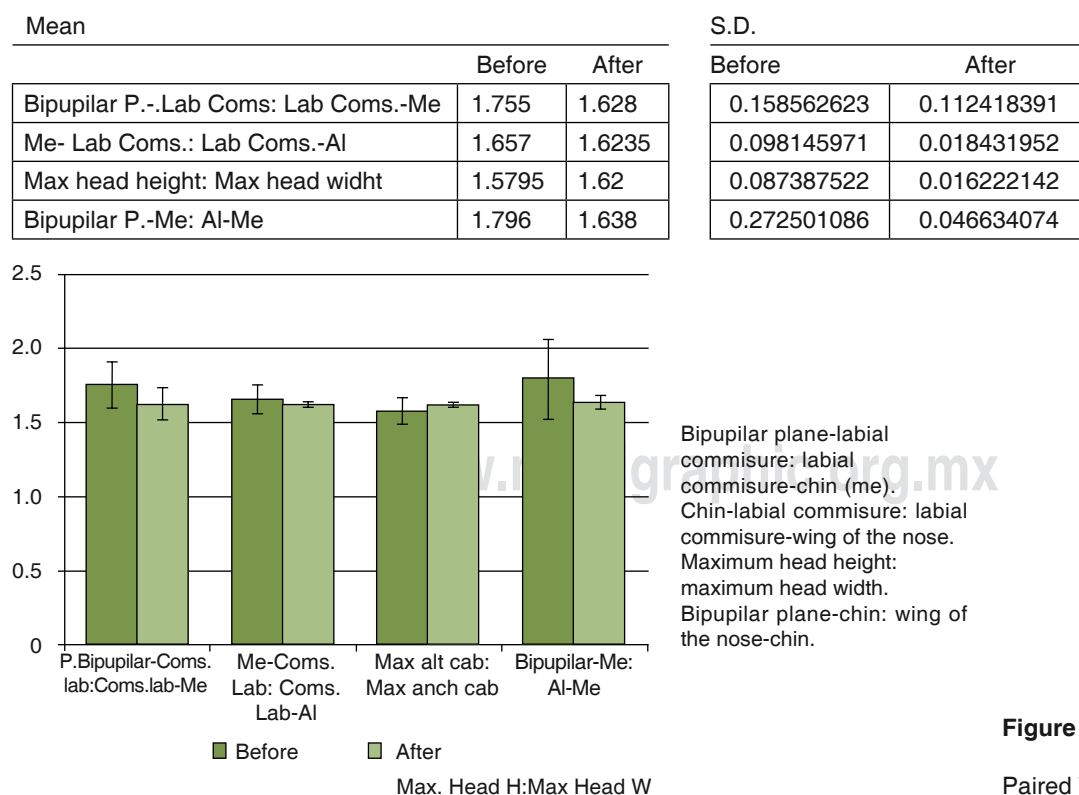
Loanidis<sup>10</sup> (1957); Baker<sup>8</sup> (2001) and Ricketts (1982) who mentioned that together, the orthodontist and surgeon should seek harmony and facial aesthetics, and use divine proportion as an auxiliary for surgical treatment planning.

The results of the present study are in disagreement with those of Mendoza<sup>13</sup> (2000) who reported that



**Figure 3.**

Facial measurements. Paired T test  $p < 0.05$ .



**Figure 4.**

Paired T test  $p < 0.05$ .

mandibular growth was one of the main factors through surgical modification of skeletal vertical distances. They used a sample of ten Asian class III patients and the measurements were not assessed aesthetically, they were only based on the surgical technique.

With regard to this study, the angular ratio MBL/RL, Gn-Cc/Cc-Go, exhibited a statistically significant difference after surgical treatment; it approximated to the absolute value of the divine proportion because it is the area that might suffer the most movement. We agree with Proffit<sup>14</sup> (1994), in that there is extensive modification in the facial harmony of class III patients.

This study coincides with Ricketts<sup>10</sup> (1982), Proffit<sup>14</sup> (1999) since the angular ratio Gn-ANS-Xi/ANS-Xi-Cc, Me-Palatal Plane/Palatal-Eye can thus and PGO-LI/LI-A is statistically significant, approximating to the golden ratio, since these are segments that can suffer occlusal variations, acting directly over the relationship between maxillary retrusion and prognathism. Lundstrom<sup>15</sup> (1960) stated that the orthodontist, by correcting the inadequate skeletal and dental position, also contributes to approximating facial structures to the golden number.

No significant differences were observed between the genders in none of the studied ratios; this coincides with the results of Loanidis<sup>10</sup> (1957) and Baker<sup>8</sup> (2001) who expressed that the divine proportion is observed or not regardless of the gender.

In regard to the linear ratios Me-AI/AI-Bipupilar Plane, Bipupilar Plane-Labial Commisure/Labial Commissure-Me, the authors agree with Yosh<sup>7</sup> (2004), since in class III patients, the upper incisors are proclined with a depressed upper lip, compromising facial harmony. However, when compared after the surgical treatment the anterior teeth are aligned in a more harmonious fashion and change in a statistically significant way being close to the golden number. In the measurements Tr-AI/AI-Me, Me-Labial commisure/Labial Commissure-AI, Maximum Head Height/Maximum Head Width and Bipupilar-Me Plane/AI-Me it was found that the values before and after surgical treatment in class III patients did not statistically differ. This is due to the fact that these ratios are related to the intermaxillary distance which experiences few changes hence the orthodontist can do little to change them.

## CONCLUSIONS

On the basis of the applied methodology and analysis of the results, it is concluded:

- From the twenty-eight angular and facial ratios studied, sixteen (mandibular body length:

mandibular ramus length; gnathion-center of cranium: center of cranium-gonion; gnathion-anterior nasal spine plane-center of condyle: anterior nasal spine plane-center of cranium; chin-palatal plane: palatal plane-eye canthus; pogonion-lower lip: lower lip-pointa; chin-wing of the nose: wing of the nose-bipupilar plane; bipupilar plane-labial commissure: labial commissure-chin; chin-labial commissure: labial commissure-wing of the nose; bipupilar plane-chin: wing of the nose-chin) presented a statistically significant difference in the aesthetic assessment before and after surgical treatment in class III patients who were then close to divine proportion.

- The measurements suggested by Ricketts<sup>10,11</sup> and Ghyka<sup>15</sup> that should be in divine proportion in beautiful faces are equally likely to differ from this golden number in a combined orthodontic/orthognathic surgery treatment especially if the treatment is not planned according to the divine proportion.
- Diagnosis of class III malocclusions and their surgical treatment with a previously designed treatment plan and prediction in plaster models are fundamental for obtaining excellent results; however not all the studied patients were within divine proportion due to the lack of communication between the Orthodontics and Maxillofacial Surgery specialties.
- In the Le Fort I and Sagittal Osteotomy surgical treatment it is of the utmost importance to know the anatomical structures involved as well as the domain of the surgical technique.
- The patient must be involved and accept the treatment suggestion that will restore not only functionality and aesthetics, but also self-confidence by raising self-esteem thus transforming an introverted, shy and anxious individual into a extroverted, confident, happy and useful to society one.

## REFERENCES

1. Leonardo de Pisa publicó "*Liber Abaci*" Oriol Orellana.
2. Paccioli Luca. *La divina proporción*. Ediciones Akal, 1991.
3. Vitrubio Polión M. *Los diez libros de Arquitectura*. Con prólogo de D. Rodríguez, "*Vitrubio y la piel del clasicismo*". Madrid: Editorial Alianza. 2009. pp. 11-51.
4. Ricketts R. The Golden Divide. *JCO*. 1981; 15: 11.
5. Ricketts R. The biologic significance of the divine proportion and Fibonacci series. *AJO*. 1982; 81 (5): 351-370.
6. JCO Interview Dr. Stephen R. Marquardt on the golden decagon an facial beauty. *JCO-Online*. 2003; 36 (6): 339-334.
7. Jefferson Y. Facial beauty – establishing a universal standard. *Int J Orthod Milwaukee*. 2004; 15 (1): 9-22.

8. Baker BW, Woods MG. The role of the divine proportion in the esthetic improvement of patients undergoing combined orthodontic/orthognathic surgical treatment. *Int J Adult Orthod Orthognath Surg.* 2001; 16 (2): 108-120.
9. Ghyka Matila C. *El número de oro*. Editorial Poseidon Los Ritmos, 1984.
10. Loanidis M. Interpretación y aplicación de la cefalometría computarizada lateral y frontal de Ricketts. *Odontológica Bonaerense.* 1957.
11. Campo BLA, Esquivel CDL, Peña CMH. Correlación cefalométrica de perfilograma y frontograma según patrón esquelético en una muestra de población colombiana. *Odontol Maxilofac.* 1987; (2): 17-24.
12. Learreta J, Bono. A. Evaluación de las vías aéreas superiores en el diagnóstico ortodóncico. *Revista S. Argentina de Ortodoncia.* Buenos Aires. 1999.
13. Mendoza J, Perales ZS, Orellana O. Estudio dentoantropológico de una población infantil de 6 a 13 años en la Clínica Odontológica de la UNMSM. *Odontología Sanmarquina.* 2000; 1 (6): 33-37.
14. Proffit W, Fields H. *Ortodoncia teórica y práctica*. Ed. Mosby. Doyma. Libros Madrid, 1994.
15. Lundstrom A. *Introducción a la Ortodoncia*. Ed. Mundi, Buenos Aires. 9: 1960. pp. 159-187.

Mailing address:  
**Evelyn Cristina Carrera Garrido**  
 E-mail: eccg1617@gmail.com



**Annex 1.**

Facial and angular measurements.

## Facial measurements

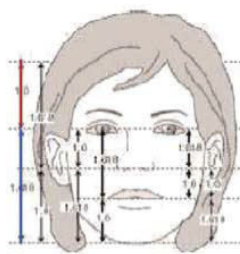
- Bipupilar plane-chin: trinchon-bipupilar plane
- Eye canthus-labial commissure: labial commissure-chin
- Chin-labial commissure: labial commissure-wing of the nose
- Chin-wing of the nose: wing of the nose-bipupilar plane
- Maximum head height: maximum head width
- Bipupilar plane-chin: wing of the nose-chin
- Trinchon-wing of the nose: wing of the nose-chin

## Angular measurements

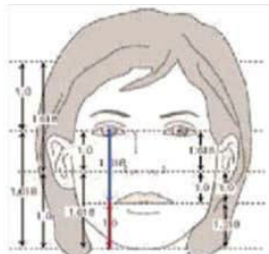
- Mandibular body length: mandibular ramus length
- Gonion-calculated geometric center of the ramus: calculated geometric center of the ramus-pogonion
- Gnathion-center of cranium: center of cranium-gonion
- Gnathion-anterior nasal spine plane-center of condyle: anterior nasal spine plane-center of cranium
- Pogonion-point A: point A-Frankfort
- Chin-palatal plane: palatal plane-eye canthus
- Pogonion-lower lip: lower lip-point A

**Annex 2.**

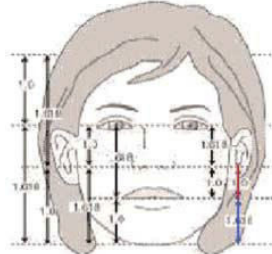
Facial and angular measurements.



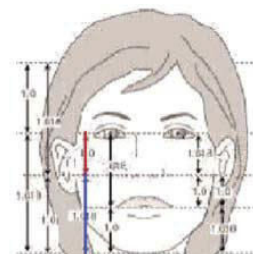
Bipupilar plane-Me (1.618):  
Tr-bipupilar plane (1)



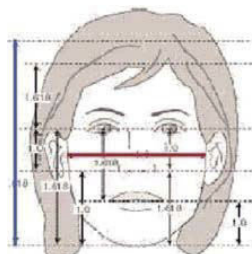
Eye canthus-labial  
commissures (1.618):  
labial commissures-Me (1)



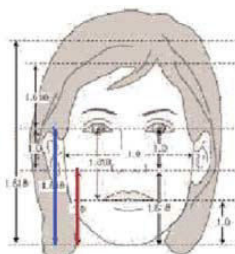
Me-labial commissures (1.618):  
labial commissures-Al (1)



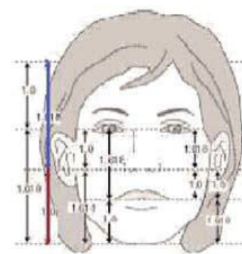
Me-Al (1.618):  
Al-bipupilar plane (1)



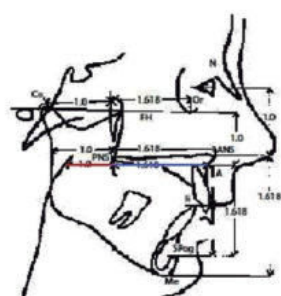
Maximum head height (1.618):  
maximum head width (1)



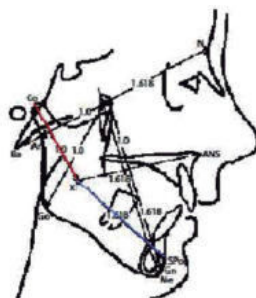Bipupilar plane-Me  
(1.618): Al-Me (1)



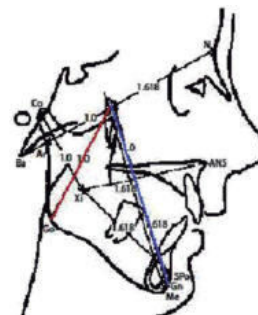
Tr-Al (1.618): Al-Me (1)



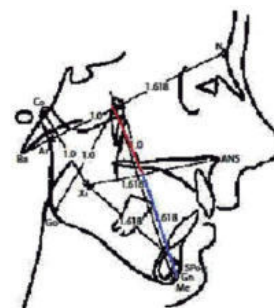Mandibular body length  
(1.618): ramus length (1)



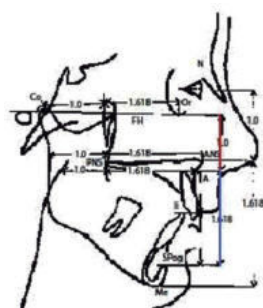
Go-Xi (1.618): Xi-Go (1)



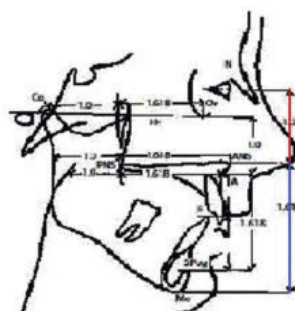
Gn-CC (1.618): CC-Go(1)



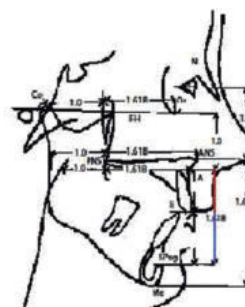Gn-ANS plane-Xi (1.618):  
ANS plane-Xi-CC (1)



Pgo-A (1.618): A-FH (1)



Me-palatal plane (1.618): palatal  
plane-eye canthus (1)



Pgo-LI (1.618): LI-point A (1)