



Comparative study between cone-beam and digital lateral head film cephalometric measurements

Estudio comparativo entre mediciones cefalométricas en cone-beam y radiografía lateral digital

Jansen Valeria Ramírez Huerta,* José Guillermo Oropeza Sosa,§ Abigail Flores Ledesma^{II}

ABSTRACT

Objective: The objective of the present study was to determine the differences between cephalometric measurements obtained by two different methods: cone-beam tomography and digital lateral head film. **Material and methods:** Measurements were performed (anterior facial height, mandibular length, upper incisor to the A-Pog line, lower incisor to the A-Pog line, ANS-PNS, ANB angle) on 30 patients by means of lateral digital radiography and cone-beam. The statistic test used was the t-Student. **Results:** The measurement that presented a statistically significant difference was the mandibular length ($p = 0.001$). **Conclusion:** Measurements performed in cone-beam scans for a 3D cephalometric analysis did not show evidence of being more effective or reliable in comparison with measurements performed in 2D.

Key words: Cone-beam, lateral head film, cephalometry, reliability.

Palabras clave: Cone-beam, radiografía lateral, cefalometría, confiabilidad.

RESUMEN

Objetivo: El objetivo del presente estudio fue determinar las diferencias de las mediciones cefalométricas realizadas por dos métodos diferentes: cone-beam y la radiografía lateral de cráneo. **Material y métodos:** Se realizaron mediciones (altura facial anterior, longitud mandibular, incisivo superior a A-pg, incisivo inferior a A-pg, ENA-ENP, ANB) de 30 pacientes por medio de radiografía lateral digital y cone-beam, se usó la prueba t-Student. **Resultados:** La longitud mandibular del lado derecho e izquierdo del cone-beam presentó diferencia estadísticamente significativa con las radiografías laterales ($p = 0.001$). **Conclusión:** Las mediciones realizadas en tomografías para la realización de un trazado cefalométrico en 3D no presentaron una evidencia de una mayor eficacia y fiabilidad en comparación a las medidas realizadas en 2D.

INTRODUCTION

Radiographic imaging is an important diagnostic tool for the orthodontic patient's assessment; since the introduction of cephalometry by Brodie in 1931, cephalometry has contributed to the analysis of both dental and skeletal malocclusions and has become a standardized diagnostic method in orthodontic practice and in research since it provides a detailed morphological analysis through the sagittal and vertical evaluation of bony, dental and soft tissues. Likewise, it permits a thorough analysis of growth through the comparison of cephalograms in different time intervals or by means of predictions.^{1,2}

Conventionally, cephalometric analysis is performed in geometric projections of a 2D radiograph in which landmarks for bone and dental structures are identified. These projections present some difficulties such as:^{3,4}

- Distortion: it is the result of an inadequate patient's head orientation in the cephalostat, incorrect aligning of the film or the central beam.

- Magnification: it is defined as the enlargement of an object's real size. The factors that influence enlargement are the size of the silver halide crystals in the emulsion or several characteristics of the intensifying screens.⁴

Cone-beam computerized tomography (CBCT) is a technology initially developed for angiographs in 1982 and was subsequently applied in maxillofacial imaging.

* Postgraduate student.

§ Professor.

^{II} Professor at the Dental Materials Laboratory.

Division of Postgraduate Studies and Research (DEPeI) of the Faculty of Dentistry (FD), National Autonomous University of Mexico (UNAM).

This article can be read in its full version in the following page:
<http://www.medigraphic.com/ortodoncia>

Since 1990 it was possible to manufacture smaller and less expensive clinical systems.³

The advantages of CBCT is that it allows the clinician to locate cephalometric points in 3D images in order to personalize cephalometric analysis with linear and angular measurements on the left and right side of the patient.^{5,6}

One of the most important advantages is the localization of cephalometric landmarks through cone-beam imaging. Their location can be described in the three planes of space: sagittal, axial and coronal.⁷⁻¹⁰

In 1995 Jacobson and Gereb developed a 3D cephalometric analysis which was capable of accurately measuring oral and facial surfaces in three dimensions. This program defined distances between anatomical landmarks.⁴

Among the disadvantages of cone-beam imaging is the high dose of radiation that the patient receives. However it should be considered that for an orthodontic patient, additional radiographs may be required such as a panoramic X-Ray or lateral head film which in sum result in higher doses of radiation compared to those of the cone-beam.^{7,10}

The objective of this study was to determine the differences between linear cephalometric measurements performed on conventional lateral radiographs and in cone beam scans of patients who attended the Orthodontics clinic of the Division of Postgraduate Studies and Research, Faculty of Odontology, UNAM, between the years of 2011 and 2013.

MATERIALS AND METHODS

To conduct this study, thirty-two patients who attended the Orthodontics Clinic in the scholar year 2011-2013, who signed an informed consent and had digital lateral head films or cone-beam scans were randomly selected. Inclusion criteria were the radiographs of patients with complete permanent dentition, without any syndrome regardless of the gender.

Radiographs and CBCT that were not taken with the cephalostat orthopos XG plus and the NewTom VGI tomograph were excluded. Digital radiographs were taken with the orthopos XG Plus cephalostat under the following conditions: 25 KV_a, 15 mA and an exposure time of 0.04 second.

The CBCT were taken with a NewTom VGI tomograph, at 70 Kv, 1-20 mA amperage, 3.6 to 5.4 seconds exposure with a sensor of 15 x 15 cm and a 0.03 x 0.03 x 0.03 Voxel measurement.

The following linear measurements were analyzed: anterior facial height, right side and the left side

Table I. Definition of variables.

Measurements	Definition
Anterior facial height	Plane formed by Nasion and Menthon points
Mandibular plane	Tangent line to the mandibular lower rim that connects Me point with the lowest point of the mandibular ramus
Upper incisor to A-Pg	Distance between the most labial portion of the upper central incisor and the A-Pg plane
Lower incisor to A-Pg	Distance between the most labial portion of the lower central incisor and the A-Pg plane
ANS-PNS	Distance between the anterior nasal spine point and the posterior nasal spine point
ANB	Angle formed by the NA-point B plane and the NA-point A plane

mandibular length, nasal spine length, upper and lower incisor to plane A-P of the right side and on the left side. The angular measurement was ANB (*Table I*).

The linear and angular measurements in the digital radiographs were obtained through the Nemotec Dental Studio NX program software (Nemotec Software 2005, SL, Madrid, Spain) while the Conebeam were obtained through the viewfinder OnDemand.

Each of the measurements was taken twice with a difference of two weeks between them and they were performed by a single operator. The statistical analysis was obtained with SPSS version 15 using a Student's t-test and ANOVA with a post-hoc Tukey test.

RESULTS

The operator performed previous tests for measurement calibration; an intraclass correlation coefficient (ICC) was used thus obtaining a 0.83 to 0.99 reliability. Once the calibration was performed, the measurements for the study were obtained.

A Kolmogorov-Smirnov test was used to determine data distribution. According to the results, the statistical tests would be parametric.

The anterior facial height, ANS-PNS and ANB in the lateral head film and in the cone-beam were compared using a Student's t-test ($p < 0.05$). No statistically significant differences were found (*Table II*). Subsequently, the mandibular length, upper incisor to A-Po and lower incisor to A-Po were compared in the

lateral head film and in the right side and left side cone-beam using the ANOVA test ($p < 0.05$) (Table III).

Statistically significant differences were found in the mandibular length. The *post hoc* Tukey test was conducted and a statistically significant difference was found between the lateral head film and the right-side cone-beam and the lateral head film and the left side cone-beam ($p > 0.05$) (Table IV and Figure 1).

DISCUSSION

There are several programs available that perform 3D cephalometry. These programs are costly and their use is complex; CBCT are usually equipped with viewfinders that allow measurement realization. However, some of the viewfinders, like the one used in this study, exhibit limitations, such as the difficulty for carrying out measurements on internal structures. Nevertheless, they provide the ability to perform many other measurements both linear and angular.

Identification of anatomical landmarks in 3D images is complex because currently, there is no standard for proper identification features. Kumar et al.¹⁰ pointed out that the evaluation of 3D anatomical landmarks is under development; according to the author, transition from 2D to 3D could be achieved through the synthesis of obtained CBCT Cephalograms.

The results of the statistical analysis clearly show a difference in the mandibular length, given that this

measurement performed in radiographs is linear. Since the mandibular structure often presents curvatures, cone-beam measurements provide a more natural and accurate structure identification.

The accuracy and precision of cephalometric measurements in 3D images obtained from computerized tomography has been assessed in different ways by several authors.^{5,10-13} Moreira et al.¹³ concluded that there were no statistical significant differences between measurements taken in cone-beam and lateral head films of dry skulls. Our study agrees with this author's results.

Grauer et al.¹⁴ conducted a study in 2010 in which the cephalometric measurements obtained from digital lateral radiographs were compared with those obtained from CBCT. Grauer's results were the same as those obtained by this study. We conclude that the similarity of the results is due to the fact that the same programs were used for obtaining the measurements.

Table IV. Tukey test for mandibular length.

Variable	p
Radiograph versus right cone-beam	0.001
Radiograph versus left cone-beam	0.001
Right cone-beam versus left cone-beam	0.756

Table II. Mean and standard deviation between parenthesis.

Variable	Lateral headfilm	Cone-beam	p
Anterior facial height	117.98 (9.73)	117.9 (8.51)	0.842
ANS-PNS	49.21 (3.74)	50.53 (2.85)	1.39
ANB	3.81 (5.61)	50.53 (2.85)	1.39

Table III. Mean and standard deviation between parenthesis.

Variable	Lateral headfilm	Right cone-beam	Left cone-beam	p
Mandibular length	67.22 (6.62)	85.07 (5.52)	86.18 (2.84)	0.001
Upper incisor to A-Pg	7.07 (2.65)	7.93 (2.24)	8.67 (2.24)	0.68
Lower incisor to A-Pg	4.50 (3.08)	5.76 (2.75)	5.19 (2.30)	0.221

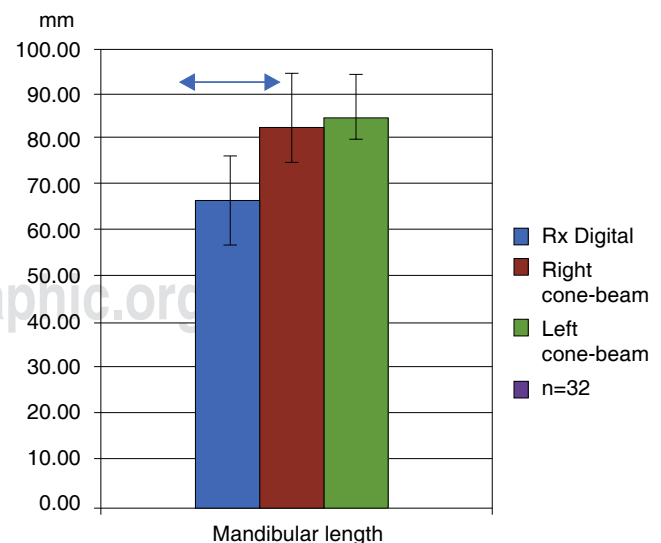


Figure 1. The upper lines show the groups with Tukey statistically significant differences ($p < 0.05$)

Shokri et al¹⁵ in 2014 conducted an *in vitro* study in which they found a statistically significant difference in mandibular length, similar to this study. However they found a statistically significant difference in the anterior facial height, which differs from our results. In the study by Shokri et al a statistically significant difference was also found in the ANS-S measurement that was not considered in this study due to the fact that the program used did not have the option of marking internal structure anatomical points.

CONCLUSIONS

The measurements in CBCTs for the realization of a 3D cephalometric tracing did not demonstrate a clear evidence of more efficiency and reliability in comparison to the measurements performed in 2D images.

Cone-beam tomography requires a higher radiation dose in comparison to digital radiography. For these reasons, their use should be limited to specific indications, such as patients with impacted teeth, facial asymmetries, and craniofacial anomalies or to determine the morphology of the temporomandibular joint among others.

REFERENCES

1. Athanasios Athanasiou. Orthodontic cephalometry. Mosby Wolfe 1995.
2. Jacobson A, Richard L. Radiographic cephalometry from basics to 3 D Chicago Quintessence books; 2006.
3. Ahlgvist J, Eliasson S, Welander U. The effect of projection errors on cephalometric length measurements. *Eur J Orthod.* 1986; 8 (3): 141-148.
4. Swennen GRJ, Schutyser F. *Three dimensional cephalometry.* Belgium. 2005.
5. Kumar V, Ludlow J, Soares CLH. *In vivo* comparison of conventional and cone beam CT synthesized cephalograms. *Angle Orthod.* 2008; 78 (5): 873-879.
6. Houston WJ. The analysis of errors in orthodontic measurements. *Am J Orthod.* 1983; 83: 382-390.
7. Navarro R de L, Oltramari-Navarro PV, Fernandes TM. Comparison of manual and digital lateral CBCT cephalometric analyses. *J Appl Oral Sci.* 2013; 2 (21): 167-176.
8. Grauer D, Cevdanes LS, Proffit WR. Working with DICOM craniofacial images. *Am J Orthod Dentofacial Orthop.* 2009; 136 (3): 460-470.
9. Bruntz LQ, Palomo JM, Baden S, Hans MG. A comparison of scanned lateral cephalograms with corresponding original radiographs. *Am J Orthod Dentofacial Orthop.* 2006; 130: 340-348.
10. Kumar V, Ludlow JB, Mol A, Cevdanes L. Comparison of conventional and cone beam CT synthesized cephalograms. *Dentomaxillofac Radiol.* 2007; 36: 263-269.
11. Cattaneo PM, Bloch CB, Calmar D, Hjortshøj M, Melsen B. Comparison between conventional and cone-beam computed tomography-generated cephalograms. *Am J Orthod Dentofacial Orthop.* 2008; 134: 798-802.
12. Pittayapat P, Limchaichana-Bolstad N, Willems G, Jacobs R. Three-dimensional cephalometric analysis in orthodontics: a systematic review. *Orthod Craniofac Res.* 2014; 17 (2): 69-91.
13. Moreira CR, Sales MA, Lopes PM. Assessment of linear and angular measurements on three-dimensional cone-beam computed tomographic images. *Oral Surg Oral Med Pathol Oral Radiol Endod.* 2009; 108 (3): 430-436.
14. Grauer D, Cevdanes LS, Styner MA, Heulfe I, Harmon ET, Zhu H et al. Accuracy and landmark error calculation using cone-beam computed tomography-generated cephalograms. *Angle Orthod.* 2010; 80: 286-294.
15. Shokri A, Khajeh S, Khavid A. Evaluation of the accuracy of linear measurements on lateral cephalograms obtained from cone-beam computed tomography scans with digital lateral cephalometric radiography: an in vitro study. *J Craniofac Surg.* 2014; 25 (5): 1710-1713.

RECOMMENDED READINGS

- Damstra J, Fourie Z, Huddleston Slater JJ, Ren Y. Reliability and the smallest detectable difference of measurements on 3-dimensional cone-beam computed tomography images. *Am J Orthod Dentofacial Orthop.* 2011; 140: e107-114.
- Halazonetis DJ. From 2-dimensional cephalograms to 3-dimensional computed tomography scans. *Am J Orthod Dentofacial Orthop.* 2005; 127: 627-637.
- Swennen GR, Schutyser F. Three-dimensional cephalometry: spiral multi-slice vs cone-beam computed tomography. *Am J Orthod Dentofacial Orthop.* 2006; 130: 410-416.
- Yu SH, Nahm DS, Baek SH. Reliability of landmark identification on monitor-displayed lateral cephalometric images. *Am J Orthod Dentofacial Orthop.* 2008; 133: 790.e1-6.
- http://www.nemotec.com/nemoceph3D-0S_catalogo.php

Mailing address:

Jansen Valeria Ramírez Huerta

E-mail: cdjansenvrh@hotmail.com