



# Revista Iberoamericana de Micología

[www.elsevier.es/reviberoammicol](http://www.elsevier.es/reviberoammicol)



## Note

# Subcutaneous phaeohyphomycosis due to *Curvularia lunata* in a renal transplant patient

Elsa Vásquez-del-Mercado\*, Lorena Lammoglia, Roberto Arenas

Sección de Micología, Departamento de Dermatología. Hospital General Dr. Manuel Gea González, Mexico City, Mexico

## ARTICLE INFO

### Article history:

Received 1 February 2012

Accepted 22 October 2012

Available online 12 November 2012

### Keywords:

Phaeohyphomycosis

Melanized fungi

Subcutaneous mycosis

*Curvularia*

## ABSTRACT

**Background:** Phaeohyphomycosis is defined as an infection caused by melanized fungi. It predominates in tropical climate and is currently classified as superficial, allergic, central nervous system or lung infections, and disseminated. *Curvularia* is one of the many genres which can cause this disease. *Phialophora*, *Alternaria* and *Exophiala* are more commonly isolated from subcutaneous lesions.

**Case report:** A 25-year-old male, renal transplant recipient presents with an ulcer on his left leg. Subcutaneous phaeohyphomycosis due to *Curvularia lunata* was diagnosed based on mycological examination and histopathological findings. He was successfully treated with systemic itraconazole and surgical resection.

**Conclusion:** The incidence of phaeohyphomycosis has increased in the last decades, especially in immunosuppressed individuals; nevertheless the number of cases does not allow for therapeutic controlled trials to be performed. Hence, we consider that it is important to communicate individual cases and reviews of the literature, to increase awareness of the disease, its clinical presentation and response to treatment.

© 2012 Revista Iberoamericana de Micología. Published by Elsevier España, S.L. All rights reserved.

## Feohifomicosis subcutánea producida por *Curvularia lunata* en un paciente receptor de un trasplante renal

## RESUMEN

**Fundamento:** La feohifomicosis se define como una infección causada por hongos dematiáceos (melanizados). Predomina en climas tropicales y en la actualidad es bien conocido que se manifiesta en forma superficial, cutánea, subcutánea y sistémica del sistema nervioso central o pulmonar diseminada. *Curvularia* es uno de los numerosos géneros que pueden causar esta infección. En las formas subcutáneas es más frecuente aislar *Phialophora*, *Alternaria* o *Exophiala*.

**Caso clínico:** Un hombre de 25 años de edad, receptor de un trasplante renal, se presentó con una úlcera en la pierna izquierda. Mediante examen micológico y los hallazgos histopatológicos se estableció el diagnóstico de feohifomicosis subcutánea producida por *Curvularia lunata*. Se trató satisfactoriamente con itraconazol sistémico y la resección quirúrgica de la úlcera.

**Conclusión:** A pesar de que, en las últimas décadas, se ha incrementado la incidencia de feohifomicosis, en particular en pacientes inmunosuprimidos, el número de casos no permite que se emprendan ensayos controlados terapéuticos. Por esta razón, consideramos que es importante comunicar los casos clínicos individuales y revisar los estudios publicados para aumentar los conocimientos sobre esta enfermedad, su presentación clínica y la respuesta al tratamiento.

© 2012 Revista Iberoamericana de Micología. Publicado por Elsevier España, S.L. Todos los derechos reservados.

### Palabras clave:

Feohifomicosis

Hongos dematiáceos (melanizados)

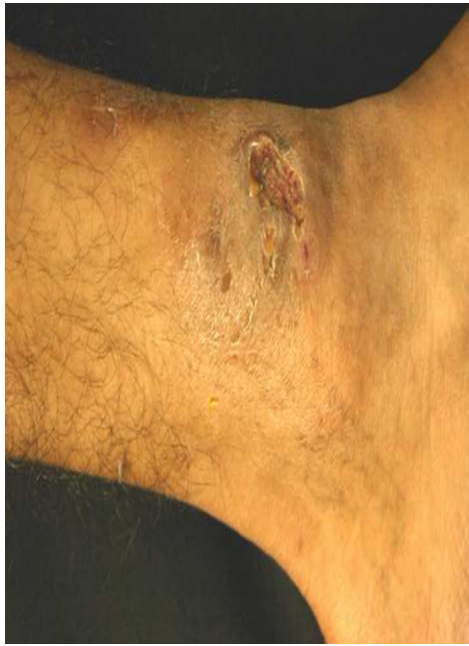Micosis subcutánea

*Curvularia*

Phaeohyphomycosis is a term used to describe infection due to melanized fungi. It is currently classified as superficial, allergic, lung or central nervous system infections and disseminated disease.<sup>2</sup>

\* Corresponding author.

E-mail address: [elsavmk@yahoo.com](mailto:elsavmk@yahoo.com) (E. Vásquez-del-Mercado).



**Fig. 1.** Multiple subcutaneous nodules surrounding an irregularly shaped ulcer.

We report the case of a 25-year-old, Mexican male with subcutaneous phaeohyphomycosis due to *Curvularia lunata*. He is dedicated to agriculture in the Southeast of Mexico, an area of tropical climate.

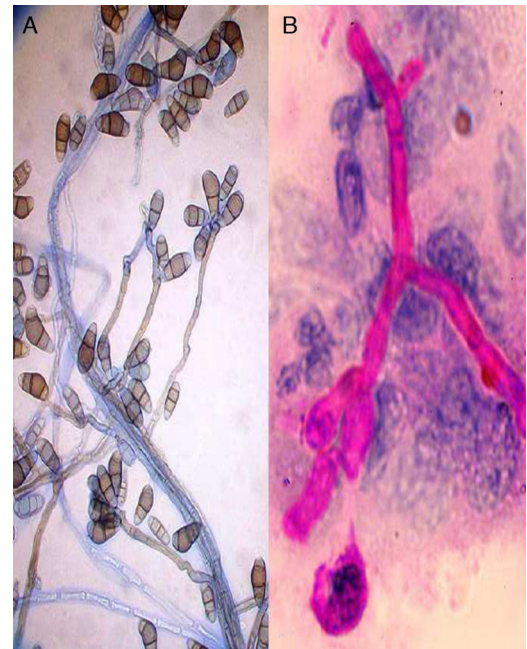
The patient had a significant past medical history of long standing renal failure and hemodialysis. He received a related-donor kidney transplant when he was 22 years old but the organ was lost after thrombosis of its main artery. He was then diagnosed as suffering from antiphospholipid syndrome. At age 23, he received a second related-donor kidney transplant. Eighteen months later, he noticed a nodule on his left leg, which slowly enlarged and finally ruptured into an ulcer with seropurulent discharge (Fig. 1). He reported mild pain, and although he did not remember a specific trauma to the area, he admitted being frequently wounded as a result of his job's activity. His medications included: prednisone, tacrolimus, mofetyl mycophenolate, allopurinol and acenocoumarol.

A direct examination of the secretion showed abundant neutrophils and lightly pigmented branching hyphae which were more evident with periodic acid-Schiff (PAS) stain (Fig. 2b).

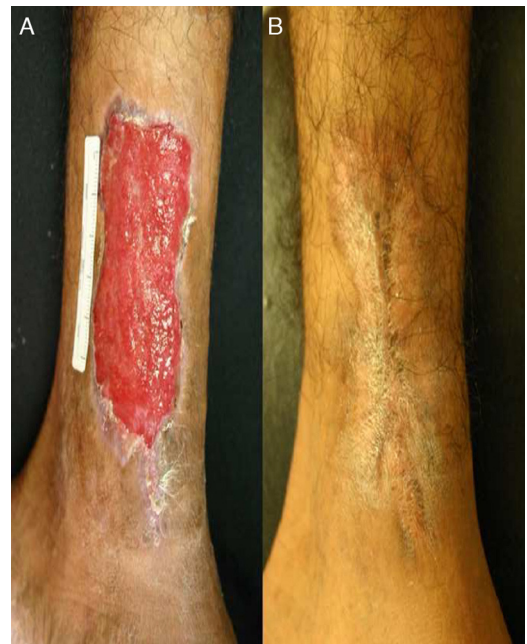Histology confirmed the presence of fungal structures both in superficial and deep dermis along with a suppurative granulomatous reaction. Serial cultures from the skin lesion grew a velvety, initially white and later becoming green to blackish colony.

On microscopy, it showed characteristic pigmented conidia with three septa, curved at the subterminal cell, which was distinctly larger and the last cell paler (Fig. 2a). With these findings the fungi was classified as *C. lunata* according to morphological guidelines suggested by de Hoog, Guarro and Figueras.<sup>8</sup> Molecular analysis was not performed since these techniques were not available to us at that time.

The patient was initially treated with itraconazole 200 mg PO a day which resulted in only slight improvement after 2 months. Seropurulent discharge continued, and erythema and edema persisted. However, the infected tissue appeared to be better circumscribed, so surgical excision was considered. A large excision of affected skin and subcutaneous tissue was performed, until healthy appearing subcutaneous tissue was observed and direct mycological examination was negative for the presence of hyphae. The wound was left to heal on secondary intention with close monitoring of serial cultures, all of which turned out negative (Fig. 3a).



**Fig. 2.** (A) Pigmented conidiophores with sympodial, septated and curved conidia, characteristic of *Curvularia* (400×). (B) Branched hyphae. PAS stained cytology (400×).



**Fig. 3.** (A) View after surgical resection. (B) Complete healing after 8 months.

With the aid of hydrocolloid and alginate dressings, the wound healed in 4 months but the patient was kept on itraconazole for a total of 8 months (Fig. 3b). He has been followed for over two years without recurrence.

## Discussion

The term phaeohyphomycosis was first used by Ajello in 1974, when referring to diseases caused by black molds other than chromoblastomycosis or mycetoma.<sup>20</sup> Years later, McGinnis also included infections caused by dematiaceous yeasts.<sup>6</sup>

Black fungi are worldwide distributed, found mainly in soil, water, plants and decay organic matter.<sup>19</sup>

Recently, the term “melanized” fungi has been proposed as being more accurate than just dematiaceous or black fungi. Melanin is found on the cell wall and is thought to be a virulence factor since it can neutralize free radicals and breakdown enzymes secreted by phagocytes, thus turning the fungus more resistant to natural destructive mechanisms.<sup>19,20</sup>

Over 60 different genres have been described as pathogenic, and some of them are implicated in certain types of infection, such as *Exophiala*, *Alternaria* and *Phialophora* which are common etiologic agents of subcutaneous disease, whereas *Curvularia* and *Bipolaris* are more frequently related to allergic sinusitis.<sup>19,20</sup> Infection is usually acquired through inhalation of spores or traumatic inoculation.<sup>14</sup> Although phaeohyphomycosis was originally described in immunocompetent patients, an increased number of cases have been reported in immunosuppressed individuals who are also at greater risk for dissemination.<sup>26</sup>

Disease spectrum is wide. Phaeohyphomycosis can present as a superficial infection of skin and soft tissues, allergic sinusitis, pneumonia, cerebral abscess or disseminated infection.<sup>2,3,19</sup>

When affecting the skin, it may present as a nodule, abscess or ulcer and can extend to deeper tissues, even bone. Renal transplant patients are somehow more likely to develop this kind of infection, especially during the first year after transplantation. Other risk factors are contact with soil, diabetes mellitus and skin trauma.<sup>11,28</sup>

*Curvularia* is not a common pathogen for subcutaneous infection, nevertheless, it has been isolated and reported both in immunocompetent and immunosuppressed patients.<sup>1,4,5,9,10,12,16,21,25</sup> It has also been found as a causative agent of endophthalmitis,<sup>17</sup> pneumonia,<sup>19,20</sup> burns' infection,<sup>24</sup> brain,<sup>7,23</sup> hepatic or spleen abscesses,<sup>22</sup> contamination of breast implants,<sup>15</sup> fungal peritonitis in peritoneal dialysis patients<sup>18,27</sup> and fatal systemic infections.<sup>7,26</sup>

Many *Curvularia* species have been isolated from clinical samples such as *Curvularia geniculata*, *Curvularia pallescens*, *Curvularia senegalensis*, *Curvularia brachyspora*, *Curvularia clavata*, *Curvularia verruculosa*, *Curvularia inaequalis* and *C. lunata*. The latter is the most frequently reported.<sup>19,20</sup>

Direct examination of tissue or secretion may visualize pigmented branching hyphae and due to its feasibility and rapidness, should always be performed. Histology is even more sensitive in identifying fungal structures, particularly with PAS, Gomori–Grocott and Fontana–Masson stains.<sup>20</sup>

Dematiaceous fungi are commonly found as contaminants in routine cultures. Only about 10% of isolates are of clinical importance, so a high degree of clinical suspicion is required for diagnosis. Based on macro and microscopical morphology it is possible to identify the fungal genre. Physicochemical tests or even molecular and ribosomal gene analysis are required to accurately identify the different species.<sup>3,18,20</sup>

Therapy regimens are not standardized since randomized clinical trials are virtually impossible due to the infrequent occurrence of cases.<sup>20</sup> Case reports are useful in this matter, helping define optimal therapy. In vitro sensibility tests have been performed for some of the reported isolates with itraconazole, posaconazole and voriconazole showing more consistent activity against them.<sup>14,19,20</sup> Careful attention should be given to possible drug interactions. Azoles are known to increase tacrolimus serum levels in renal transplant patients.<sup>28</sup>

In visceral or disseminated disease, amphotericin B is the preferred treatment, followed by long-term administration of azoles.

It has been suggested that combination therapy with azoles and terbinafine or azoles and caspofungin may be synergistic.<sup>20</sup> However, *Scedosporium* has proved to be resistant to most of the treatments. Treatment duration depends on clinical outcome.

For localized disease, surgery has proved to be a great option, either alone or in combination with systemic antifungals.<sup>3,11,13,20,26</sup>

## References

- Agrawal A, Singh SM. Two cases of cutaneous phaeohyphomycosis caused by *Curvularia pallescens*. *Mycoses*. 1995;38:301–3.
- Arenas R, editor. Phaeohyphomycosis. In: *Micología Médica Ilustrada*. 4th ed. México City: McGraw-Hill-Interamericana; 2011. p. 320–43.
- Baradkar VP, Mathur M, Kumar S. Phaeohyphomycosis of subcutaneous tissue caused by *Phaeoacremonium parasiticum*. *Indian J Med Microbiol*. 2009;27:66–9.
- Berlango JJ, Querol S, Gallardo D, Ferra C, Grañena A. Successful treatment of *Curvularia* sp. infection in a patient with primarily resistant acute promyelocytic leukemia. *Bone Marrow Transplant*. 1995;16:617–9.
- Bonduel M, Santos P, Turienzo CF, Chantada G, Paganini H. Atypical skin lesions caused by *Curvularia* sp. and *Pseudallescheria boydii* in two patients after allogeneic bone marrow transplantation. *Bone Marrow Transplant*. 2001;27:1311–3.
- Brandt ME, Warnock DW. Epidemiology, clinical manifestations and therapy of infections caused by dematiaceous fungi. *J Chemother*. 2003;15 Suppl. 2:36–47.
- Carter E, Boudreaux C. Fatal cerebral phaeohyphomycosis due to *Curvularia lunata* in an immunocompetent patient. *J Clin Microbiol*. 2004;42:5419–23.
- De Hoog GS, Guarro GJ, Figueras MJ, editors. *Curvularia*. In: *Atlas of clinical fungi*. 2nd ed. Utrecht, The Netherlands: Ciudad, Centraalbureau voor Schimmelfcultures; 2000. p. 598.
- Fan YM, Huang WM, Li SF, Wu GF, Li W, Chen RY. Cutaneous phaeohyphomycosis of foot caused by *Curvularia clavata*. *Mycoses*. 2008;52:544.
- Fernández M, Noyola DE, Rossmann SN, Edwards MS. Cutaneous phaeohyphomycosis caused by *Curvularia lunata* and a review of *Curvularia* infections in pediatrics. *Pediatr Infect Dis J*. 1999;18:727–31.
- Gallelli B, Viviani M, Nebuloni N, et al. Skin infection due to *Alternaria* species in kidney allograft recipients: report of a new case and review of the literature. *J Nephrol*. 2006;19:668–72.
- Grieshop TJ, Yarbrough 3rd D, Farrar WE. Case report: phaeohyphomycosis due to *Curvularia lunata* involving skin and subcutaneous tissue after an explosion at a chemical plant. *Am J Med Sci*. 1993;305:387–9.
- Heinz T, Perfect J, Schell W, Ritter E, Ruff G, Serafin D. Soft-tissue fungal infections: surgical management of 12 immunocompromised patients. *Plast Reconstr Surg*. 1996;97:1391–9.
- Hiromoto A, Nagano T, Nishigori C. Cutaneous infection caused by *Curvularia* species in an immunocompetent patient. *Br J Dermatol*. 2008;158:1374–5.
- Kainer MA, Keshavarz H, Jensen BJ, et al. Saline-filled breast implant contamination with *Curvularia* species among women who underwent cosmetic breast augmentation. *J Infect Dis*. 2005;192:170–7.
- Lavoie SR, Espinel-Ingroff A, Kerker T. Mixed cutaneous phaeohyphomycosis in a cocaine user. *Clin Infect Dis*. 1993;17:114–6.
- Pathengay A, Shah GY, Das T, Sharma S. *Curvularia lunata* endophthalmitis presenting with a posterior capsular plaque. *Indian J Ophthalmol*. 2006;54:65–6.
- Pimentel JD, Mahadevan K, Woodgryer A, et al. Peritonitis due to *Curvularia inaequalis* in an elderly patient undergoing peritoneal dialysis and a review of six cases of peritonitis associated with other *Curvularia* spp. *J Clin Microbiol*. 2005;43:4288–92.
- Revankar SG. Phaeohyphomycosis. *Infect Dis Clin North Am*. 2006;20:609–20.
- Revankar SG, Sutton DA. Melanized fungi in human disease. *Clin Microbiol Rev*. 2010;23:884–928.
- Russo JP, Raffaelli R, Ingratta SM, Rafti P, Mestroni S. Cutaneous and subcutaneous phaeohyphomycosis. *Skinmed*. 2010;8:366–9.
- Shigemori M, Kawakami K, Kitahara T, et al. Hepatosplenic abscess caused by *Curvularia boedijnii* in a patient with acute monocytic leukemia. *Pediatr Infect Dis J*. 1996;15:1128–9.
- Smith T, Goldschlager T, Mott N, Robertson T, Campbell S. Optic atrophy due to *Curvularia lunata* mucocoele. *Pituitary*. 2007;10:295–7.
- Still Jr JM, Law EJ, Pereira GL, Singletary E. Invasive burn wound infection due to *Curvularia* species. *Burns*. 1993;19:77–9.
- Subramanyam VR, Rath CC, Mishra M, Chhotrai GP. Subcutaneous infection due to *Curvularia* species. *Mycoses*. 1993;36:449–50.
- Tessari E, Forni A, Ferretto R, et al. Lethal systemic dissemination from a cutaneous infection due to *Curvularia lunata*. *J Eur Acad Dermatol Venereol*. 2003;17:440–2.
- Vachharajani TJ, Zaman F, Latif S, Penn R, Abreo KD. *Curvularia geniculata* fungal peritonitis: a case report and review of the literature. *Int Urol Nephrol*. 2005;37:781–4.
- Vermeire SEM, de Jonge H, Lagrou K, Kuypers DRJ. Cutaneous phaeohyphomycosis in renal allograft recipients: report of 2 cases and review of the literature. *Diagn Microbiol Infect Dis*. 2010;68:177–80.