



# Revista Iberoamericana de Micología

www.elsevier.es/reviberoammicol



## Note

## Renal abscess due to *Aspergillus fumigatus* as the only sign of disseminated aspergillosis in a patient with AIDS

Humberto Metta<sup>a,\*</sup>, Marcelo Corti<sup>b</sup>, Liliana Redini<sup>a</sup>, Florencia Bruggesser<sup>a</sup>, Alicia Arechavala<sup>c</sup>, Ricardo Negroni<sup>c</sup> and Lisandro Veliz<sup>d</sup>

<sup>a</sup> Unit 17, Infectious Diseases F. J. Muñiz Hospital, Buenos Aires, Argentina

<sup>b</sup> Division of HIV/AIDS, Infectious Diseases F. J. Muñiz Hospital, Buenos Aires, Argentina

<sup>c</sup> Micology Unit, Infectious Diseases F. J. Muñiz Hospital, Buenos Aires, Argentina

<sup>d</sup> Urologic Service, Infectious Diseases F. J. Muñiz Hospital, Buenos Aires, Argentina

### ARTICLE INFO

#### Article history:

Received 27 February 2009

Accepted 17 September 2009

Available online 24 de marzo de 2010

#### Keywords:

*Aspergillus fumigatus*

Renal abscess

AIDS

HIV

### ABSTRACT

**Background:** *Aspergillus fumigatus* can cause a wide variety of clinical syndromes, especially in the three largest immunocompromised groups, such as HIV-infected patients. Primary renal aspergillosis is an extremely rare entity.

**Aims:** We report an unusual case of renal abscess due to *Aspergillus fumigatus* in a patient with AIDS.

**Methods:** We review clinical and laboratory records, and provide follow up of the patient.

**Results:** A 38-year-old man, HIV seropositive, was admitted to our hospital with fever, lumbar pain and respiratory symptoms. Abdominal ultrasound and computerised tomography showed a single and large lesion consistent with an abscess located in the left kidney. *Aspergillus fumigatus* was isolated from clinical sample obtained by ultrasound-guided needle aspiration. Despite a correct treatment based on amphotericin B and drainage of the abscess, surgery was necessary and nephrectomy was carried out. Histopathological examination of the surgical specimen confirmed the diagnosis of renal aspergillosis. Systemic antifungal therapy based on intravenous and oral voriconazole and highly active antiretroviral therapy was started after surgery. The patient had a good response to the established treatment and he remains in a good clinical condition at one year of follow up.

**Conclusions:** Combined medical and surgical treatment is the elective therapy for renal abscesses due to *Aspergillus* when percutaneous drainage and the administration of systemic antifungal drugs, such as amphotericin B and/or oral voriconazole or itraconazole, fail. This case emphasizes renal fungal infections should be included in the differential diagnosis of kidney abscesses in AIDS patients.

© 2009 Revista Iberoamericana de Micología. Published by Elsevier España, S.L. All rights reserved.

## Absceso renal por *Aspergillus fumigatus* como única manifestación de aspergilosis diseminada en un paciente con sida

### RESUMEN

#### Palabras clave:

*Aspergillus fumigatus*

Absceso renal

Sida

VIH

**Antecedentes:** *Aspergillus fumigatus* puede provocar un amplio espectro de síndromes clínicos en diversos grupos de pacientes inmunodeficentes, como los infectados por el VIH. La aspergilosis renal primaria es una entidad extremadamente rara.

**Objetivo:** Comunicar un caso infrecuente de absceso renal por *Aspergillus fumigatus* en un paciente con SIDA.

**Métodos:** Revisión de ficha clínica y seguimiento del paciente.

**Resultados:** Se presenta el caso de un paciente de 38 años, VIH positivo, quien ingresa en el hospital por presentar fiebre, lumbalgia izquierda y síntomas respiratorios. Los estudios de imagen revelaron la existencia de una gran lesión en el riñón izquierdo compatible con un absceso. La biopsia por aspiración dirigida por ecografía logró la obtención de una muestra clínica que permitió el aislamiento de *Aspergillus fumigatus*. A pesar del tratamiento con anfotericina B desoxicolato y el drenaje del absceso, el cuadro no mostró mejoría por lo cual se realizó la nefrectomía. El examen histopatológico de la pieza quirúrgica confirmó el diagnóstico de aspergilosis renal. Tras la exéresis se instauró tratamiento con voriconazol por vía intravenosa y oral en forma secuencial, asociado al tratamiento antirretroviral de gran actividad. El

\* Corresponding author.

E-mail address: hmetta@sinectis.com.ar (H. Metta).

paciente mostró una buena respuesta al esquema terapéutico y continuaba en buena condición clínica un año después de su egreso hospitalario.

**Conclusiones:** La aspergilosis debe incluirse en el diagnóstico diferencial del compromiso renal en pacientes con sida. En el caso que se presenta, el inicio precoz del tratamiento con AMB y luego voriconazol seguido por la nefrectomía permitió la recuperación del paciente con estabilización del cuadro durante el periodo de seguimiento.

© 2009 Revista Iberoamericana de Micología. Publicado por Elsevier España, S.L. Todos los derechos reservados.

Primary renal aspergillosis is a very rare complication of AIDS and it is associated with a poor prognosis and a high mortality rate<sup>1,6</sup>. Aspergillosis is unfrequent in AIDS patients. Its incidence has increased during the last years and it has become an important and commonly fatal complication in advanced HIV disease<sup>5</sup>. Only a few cases have been described in AIDS patients.

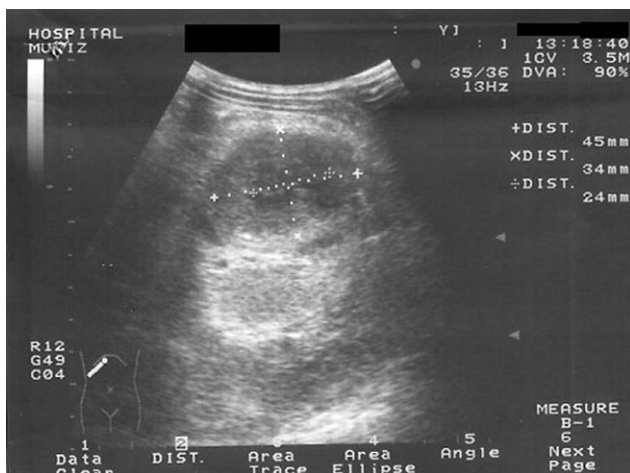We report a case of an AIDS patient who developed a unilateral renal abscess due to *Aspergillus fumigatus* as the only manifestation of disseminated aspergillosis.

### Case report

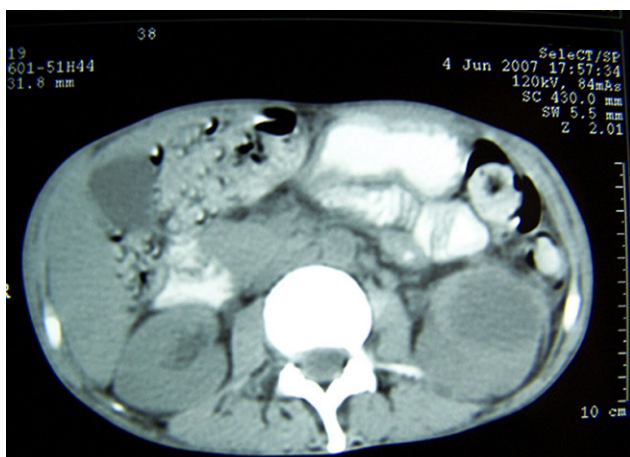
A 38-year-old HIV positive heterosexual man, with history of recurrent pneumonia, disseminated tuberculosis, syphilis, drug

abuse, chronic hepatitis due to HCV (AIDS C3), was admitted to our unit on account of persistent fever, weight loss, dorsal and lumbar pain, cough and expectoration. On admission he was alert and oriented. Relevant laboratory findings included: hemoglobin 7.4 g/dL; hematocrit 21%; white cells count 9700/mm<sup>3</sup>; platelets count 322,000/mm<sup>3</sup>; alkaline phosphatase 389 U/L (N=90–240 U/L); lactate dehydrogenase 376 U/L, CD4T cell count 14 cells/μL (2%). Microscopic examination of sputum was positive for acid fast bacilli. Localized radiological opacity in middle lung zones were found as radiographic abnormalities.

Antibacterial therapy using first-line antituberculous drugs (isoniazid, rifampin, pyrazinamide, and ethambutol) was started. Bacteriologic, mycologic and mycobacterial blood cultures were negative. Abdominal ultrasonography scan and computerized tomography scan disclosed liver enlargement and a hypoechoic lesion (45 × 34 × 24 mm.) in the left kidney, consistent with an

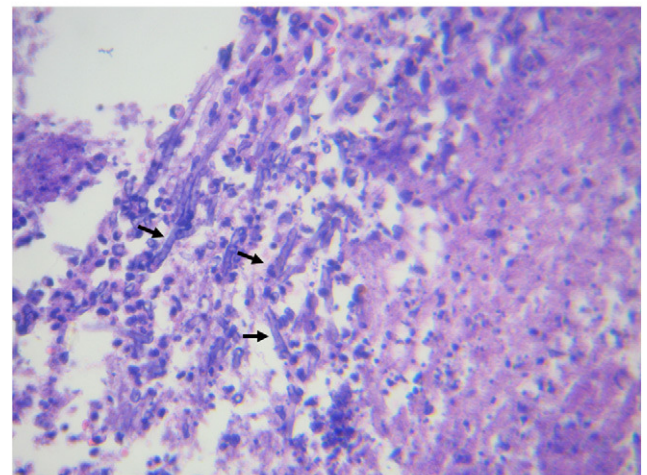


**Fig. 1.** Abdominal ultrasonography scan: hypoechoic lesion (45 × 34 × 24 mm) in the left kidney, consistent with an abscess.

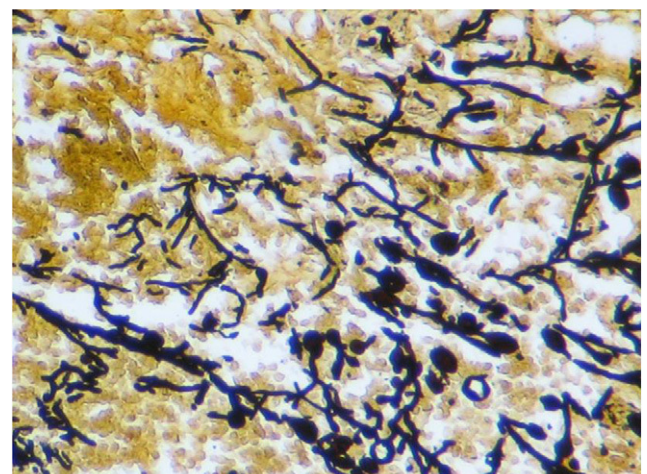


**Fig. 2.** Abdominal computerized tomography scan showing a hypodense image in the left kidney consistent with the renal abscess due to *Aspergillus fumigatus*.

a



b



**Fig. 3.** Septate hyaline filamentous forms consistent with *Aspergillus* spp. (arrows) (a: Hematoxylin–eosin, b: Grocott stain).



abscess (Figs. 1 and 2). Computerized tomography cerebral scan showed no abnormality but cortical brain atrophy. The patient developed left lumbar pain, renal impairment with micro-hematuria and granulomatous casts. Culture of sputum obtained on admission showed *Mycobacterium tuberculosis* mycobacteria other than *Mycobacterium tuberculosis*. Ciprofloxacin and clarithromycin were added to the first therapeutic regimen.

Ultrasonographic percutaneous-guided fine needle drainage of the abscess was performed. Ziehl-Neelsen and Gram stains of the material obtained were negative, but septate hyaline filamentous forms were observed while, in the culture, *Aspergillus fumigatus* grew. No lesion was found in the echocardiogram. Amphotericin B desoxycholate was prescribed up to an accumulative dose of 180 mg, and was discontinued in favor of voriconazole (100 mg bid, adjusted to patient's weight) on account of renal impairment and anemia (creatinine clearance 15.6 mL/min (N: 70–140), hemoglobin 6.2 gr/dL). Finally, a change to pyrazinamide, ethambutol, ofloxacin, clarithromycin (plus voriconazole) was made because of drug interaction between rifampin and voriconazole and *M. tuberculosis* resistance to isoniazid. The patient's condition worsened despite appropriate antimicrobial therapy, with persistence of the renal abscess and perinephric effusion. Accordingly, a nephrectomy was performed. Histopathological examination of the surgical specimen revealed a cavitory structure inside a necrotic mass. Fungal elements were evident in the necrotic material (Fig. 3a and b). Culture of the specimen showed *Aspergillus fumigatus* colonies (Fig. 4). Antifungal therapy based on intravenous voriconazole (6 mg/kg twice a day as an initial dose followed by 4 mg/kg) and highly active antiretroviral therapy was started. After 2 weeks, intravenous voriconazole was replaced by the oral formulation at doses of 200 mg twice a day. During one year follow up period the patient had normal renal function with no evidence of recurrence, resolution of pulmonary mycobacteriosis, and immune reconstitution.

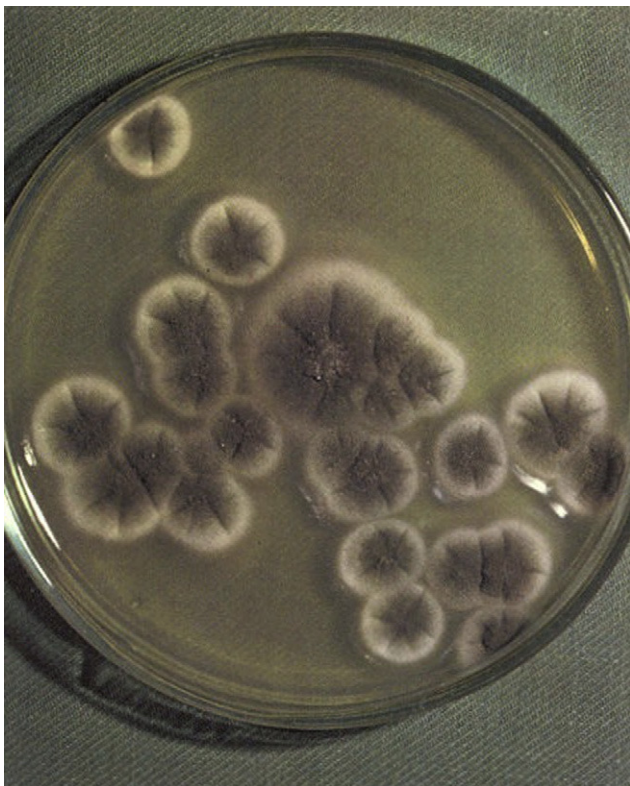

Fig. 4. Culture of the clinical sample showing *Aspergillus fumigatus* colonies.

## Discussion

*Aspergillus* species are ubiquitous fungi, some of which can cause a wide variety of clinical manifestations ranging from colonization to severe and invasive disease.<sup>7</sup>

Only a few species of *Aspergillus* can cause human illness. The most common is *Aspergillus fumigatus* and to a lesser extent these infections are caused by *Aspergillus flavus*, *Aspergillus niger* and *Aspergillus terreus*.<sup>7,8</sup>

Clinical manifestations of *Aspergillus* infections vary depending on circumstances but can include respiratory involvement, allergic bronchopulmonary aspergillosis, intracavitary aspergilloma, chronic forms of pulmonary aspergillosis, acute invasive aspergillosis, tracheobronchitis and rhinosinusitis. The most severe clinical presentation is the acute invasive form. The lung usually is the portal of entry through which the pathogen may disseminate to every organ. Invasive or disseminated aspergillosis mortality rate reaches almost 100%, especially when the central nervous system is infected.<sup>9,10</sup>

The most common underlying conditions for invasive aspergillosis include immunosuppression for solid organ transplantation, cytotoxic chemotherapy resulting in neutropenia, prolonged therapy with corticosteroids, diabetes and, most recently, advanced HIV/AIDS disease.<sup>8,10</sup>

*Aspergillus* abscesses of the kidneys are very rare complications of advanced HIV/AIDS disease and they usually have a fatal outcome.<sup>5</sup> It usually occurs in patients with severe immunodeficiency, as in the case we describe. Most rare in this group of patients is infection limited to the kidneys as was shown in our case.<sup>3</sup> The hematogenous spread of the *Aspergillus* infection acquired by inhalation of spores should be attributed to the loss of normal immune mechanisms, due to the retroviral infection in this case.

Clinical diagnosis of renal aspergillosis includes imaging techniques, histopathology, and microbiological examinations. At ultrasonography, renal abscesses due to *Aspergillus* sp. appear as hypoechoic or anechoic lesions. Computerized tomography scan shows an hypodense and well-defined lesions with ring enhancement, as in our patient. Computerized tomography or ultrasonography guided fine needle aspiration biopsy is the gold standard method to diagnose renal abscess due to *Aspergillus*.<sup>11</sup>

Laboratory diagnostic methods of aspergillosis include histopathological evidence of tissue invasion by fungal hyphae and identification of the microorganism by direct microscopy and cultures.<sup>7,8</sup>

Treatment of renal abscesses due to *Aspergillus* species includes percutaneous drainage and the administration of systemic antifungal drugs such as amphotericin B, followed by oral voriconazole or itraconazole. In the last five years, voriconazole has become the drug of choice for invasive aspergillosis treatment.<sup>4,12</sup> When this strategy fails, as in our patient, nephrectomy followed by a prolonged antifungal systemic therapy is the treatment of choice.<sup>2</sup>

**Conclusions:** Nephrectomy followed by a prolonged antifungal systemic therapy is the treatment of choice of renal abscesses due to *Aspergillus* species when percutaneous drainage and the administration of systemic antifungal drugs such as amphotericin B and/or oral voriconazole or itraconazole fail.

This case emphasizes the fact that renal fungal infection should be included in the differential diagnosis of kidney abscesses in AIDS patients.

## Conflict of interest

The authors declare that they do not have any conflict of interest.

## References

1. Bisi M, Palou J, Segarra J, Salvador J, Villavicencio H. Percutaneous treatment of a primary renal aspergilloma in a patient with AIDS. *Arch Ital Urol Androl.* 2003;75:119–23.
2. Chandrasekar PH, Ito JI. Amphotericin B lipid complex in the management of invasive aspergillosis in immunocompromised patients. *Clin Infect Dis.* 2005;40(Suppl. 6):S392–400.
3. Fiteni I, Crusells MJ, Cuesta J, Letona S. Renal invasive aspergilloma: unusual infection in AIDS. *J Infect.* 1996;33:61–3.
4. Herbrecht R, Denning DW, Patterson TF, Bennett JE, Greene RE, Oestmann JW, et al. Invasive Fungal Infections Group of the European Organisation for Research and Treatment of Cancer and the Global Aspergillus Study Group. Voriconazole versus amphotericin B for the primary therapy of invasive aspergillosis. *N Engl J Med.* 2002;347:408–15.
5. Kümmerle S, Wedler H. Renal abscesses in an AIDS patient caused by *Aspergillus fumigatus*. *Urol Int.* 1998;61:52–4.
6. Martinez-Jabaloyas J, Oscar JM, Ruiz JL, Beamud A, Blanes M, Jimenez-Cruz JF. Renal aspergillosis and AIDS. *Eur Urol.* 1995;27:167–9.
7. Muñoz P, Guinea J, Bouza E. Update on invasive aspergillosis: clinical and diagnostic aspects. *Clin Microbiol Infect.* 2006;12(Suppl. 7):24–39.
8. Mylonakis E, Barlam TF, Flanigan T, Rich JD. Pulmonary aspergillosis and invasive disease in AIDS. Review of 342 cases. *Chest.* 1998;114:251–262.
9. Nadkarni T, Goel A. Aspergilloma of the brain: an overview. *J Postgrad Med.* 2005;51(Suppl. 1):S37–41.
10. Park YS, Seo JB, Lee YK, Do KH, Lee JS, Song JW, et al. Radiological and clinical findings of pulmonary aspergillosis following solid organ transplant. *Clin Radiol.* 2008;63:673–80.
11. Poll LW, Koch J, Medve M, May P, Sarbia M, Engelbrecht V, et al. CT appearance of a renal aspergilloma in a patient with the acquired immunodeficiency syndrome. *Urol Int.* 1999;62:110–3.
12. Walsh TJ, Anaissie EJ, Denning DW, Walsh TJ, Anaissie EJ, Denning DW, et al. Treatment of aspergillosis: clinical practice guideline of the Infectious Diseases Society of America. *Clin Infect Dis.* 2008;46:327–60.