

## Images in medicine

## Conjunctival dermolipoma

## Dermo lipoma conjuntival



Julio C. Salas-Alanís<sup>a</sup>, Mauricio Salas-Garza<sup>b</sup>, Isaac H. Sicsik-Arévalo<sup>c</sup>, Lucía E. Varela-Martínez<sup>c</sup>,  
María G. Moreno-Treviño<sup>c</sup> and Gerardo Rivera-Silva<sup>c,\*</sup>

<sup>a</sup> Preparatoria No 5, Autonomous University of Nuevo León, Monterrey, NL, Mexico

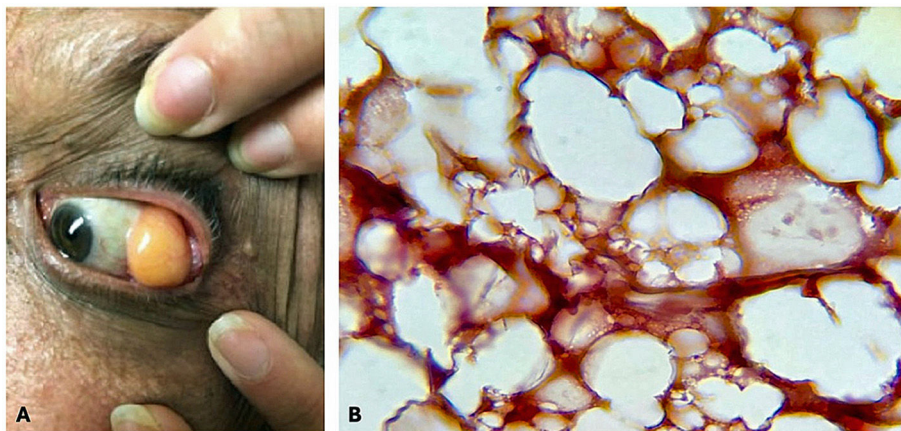
<sup>b</sup> Debra Foundation Mexico, Monterrey, NL, Mexico

<sup>c</sup> Academic Department, School of Medicine, University of Monterrey, Monterrey, NL, Mexico

A 52-year-old man visited our clinic with concerns about a fleshy growth on the upper outer part of his left eye. He reported that the mass had been gradually increasing in size over the past two years. His medical history was unremarkable. During the examination, a yellow, encapsulated mass—presumed to be a dermolipoma—was identified on the superotemporal bulbar conjunctiva of the left eye (Fig. 1A). The lesion's size restricted eye movements, particularly those involving the lateral rectus muscle, and caused persistent friction between the mass and the eyelids during blinking. No signs of infection, pain, or tenderness were observed. The tumor was surgically excised. Histopathological evaluation revealed a composition predominantly of adipose tissue interspersed with reticular fibers (Fig. 1B). The final diagnosis confirmed conjunctival dermolipoma. A surgical removal of the lipoma was performed.

## Ethical consideration

Patient written informed consent was obtained.



**Figure 1.** General appearance of the lipoma (A). Adipose tissue with reticular fibers (B. Orcine stain, 40X).

\* Corresponding author at: Av. I. Morones Prieto # 4500 Pte, San Pedro Garza Garcia, NL, 66238, Mexico.  
E-mail address: gerardo.rivera@udem.edu (G. Rivera-Silva).

### **Ethical committee**

Comité de Investigación de la UDEM.

### **Declarations of interest**

None.

There was no funding or financial support in the creation of this clinical image.