

Images in medicine

A foreign body identified in the X-ray

Un cuerpo extraño en la radiografía de de tórax

Makram Tbini^{a,b,*}, Ines Riahi^{a,b}, Chaima Ben Ammar^{a,b} and Mamia Ben Salah^{a,b}

^a ENT Department, Charles Nicolle Hospital, Boulevard du 9-Avril 1938, 1006 Tunis, Tunisia

^b Faculty of Medicine of Tunis, University Tunis el Manar, Tunisia



A 3-year-old girl presented to our emergency room after swallowing an unknown object, probably metallic, according to her parents. Physical exam reveals hypersialorrhea. A chest X-ray was requested showing a round, opaque object at the C6 level with a double-ring sign (Fig. 1A). A button battery ingestion was suspected. An emergency esophagoscopy under general anesthesia was performed, and a button battery was extracted (Fig. 1B).

Ingestion of foreign bodies is more common among children, particularly those under the age of 5. The most common are coins and the most dangerous batteries. 'Double-ring' or 'halo' sign is a pathognomonic sign.

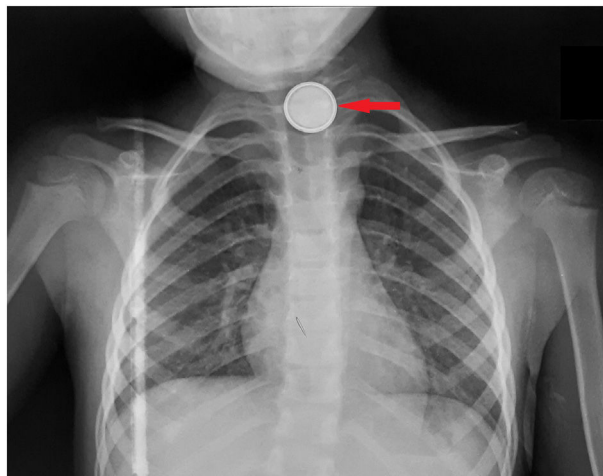


Figure 1A. Chest X-ray showing a radiopaque foreign body with a double-ring sign.

* Corresponding author at: ENT Department, Charles Nicolle Hospital, Boulevard du 9-Avril 1938, 1006 Tunis, Tunisia.
E-mail address: makramtb@yahoo.com (M. Tbini).



Figure 1B. Button battery extracted.

Funding

None.

Ethical approval

Case reports are exempt from ethical approval at our institution.

Consent

Written informed consent for publication of clinical details and images was obtained from the patient's parents.

CRediT authorship contribution statement

Ines Riahi: Writing – original draft. **Chaima Ben Ammar:** Writing – review & editing. **Mamia Ben Salah:** Supervision.

Conflict of interest

None.