

Images in medicine

Osteochondritis of the ischiopubic synchondrosis: Don't confuse it with a tumor!



Osteocondritis de la sincondrosis isquiopúbica: ¡no lo confundas con un tumor!

Aleix Jareno-Badenas*, Gary Amseian, Valèria Richart and Marta Porta-Vilaró

Department of Radiology, Hospital Clínic Barcelona, Barcelona, Spain

A 15-year-old female hockey player presented to our hospital with incapacitating pain in the right groin/buttock area, persisting for several months. The pain was localized to the insertion point of the ischial tendons and within the region of the adductor muscles. Despite periods of rest and rehabilitation, there was no reported improvement. No other concurrent symptoms or anomalous findings were observed in laboratory tests.

To better characterize the pain, magnetic resonance imaging (MRI) was performed. The MRI revealed a pseudonodular, slightly insuflating image localized around the synchondrosis of the right ischiopubic ramus. This image was associated with concomitant bony edema and mild involvement of adjacent soft tissues, as well as localized intraosseous enhancement with a central hypointense line (Fig. 1). Considering these findings in conjunction with the patient's clinical history, the diagnosis of osteochondritis of the ischiopubic synchondrosis was suggested.

Ischiopubic osteochondritis is a rare and benign cause of unilateral pain in the pediatric pelvis, characterized by localized and asymmetric hyperostosis at the ischiopubic synchondrosis. Typically, it responds well to symptomatic treatment. Recognizing this condition is crucial to distinguish it from primary differentials such as stress fractures, osteomyelitis, and bone tumors. This differentiation is essential to avoid unnecessary aggressive interventions.

* Corresponding author.

E-mail address: ajarenba95@gmail.com (A. Jareno-Badenas).

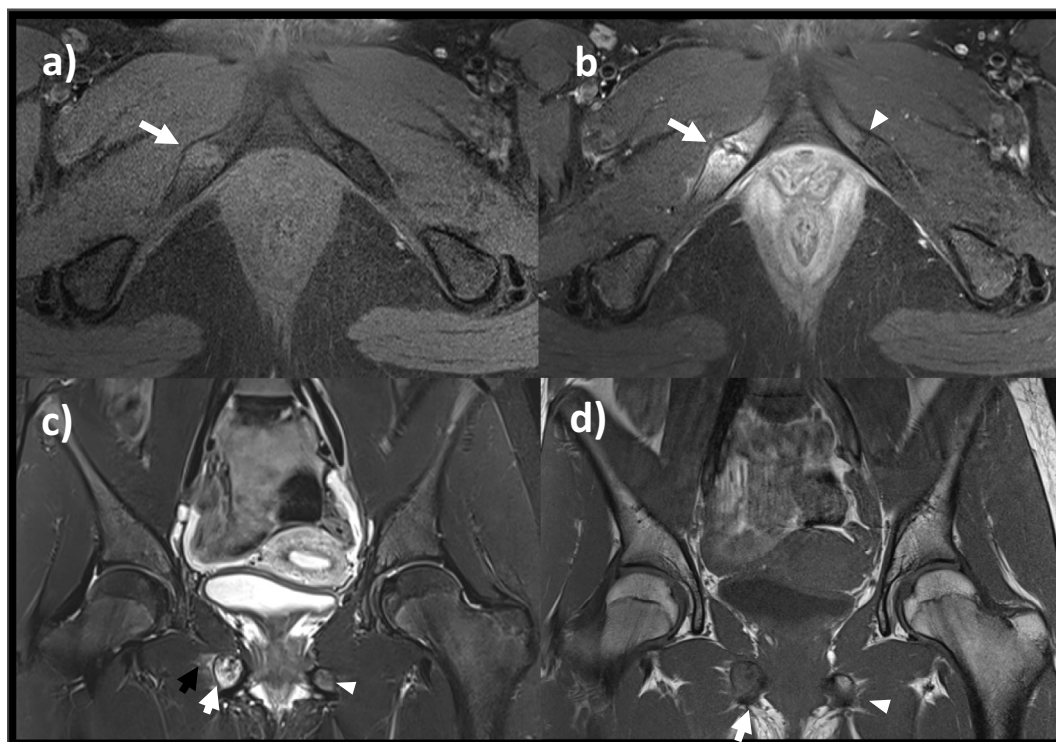


Fig. 1. (a) Axial T1FS shows a pseudonodular and slightly insufflating image (arrow) adjacent to the right ischiopubic synchondrosis. (b) Axial T1FS + C reveals contrast enhancement of the bone around a central hypointense line (white arrow) in the right ischiopubic synchondrosis. The contralateral synchondrosis exhibits a normal appearance (arrowhead). (c) Coronal STIR displays the insufflating lesion with bone edema (white arrow) and adjacent soft tissue edema (black arrow) around the right ischiopubic synchondrosis. The contralateral bone maintains a normal appearance (arrowhead). (d) Coronal T1 depicts the insufflating lesion (white arrow) around the right ischiopubic synchondrosis. The contralateral bone exhibits a normal appearance (arrowhead).

Funding

No funding has been received.

Ethical considerations

Verbal consent was obtained from the legal representative of the patient.

Declaration of competing interest

The authors declare no conflict of interest.