

Image in medicine

An unusual cause of massive hemoptysis: Mycotic pseudoaneurism from a pulmonary artery branch

Una causa infrecuente de hemoptisis masiva: pseudoaneurisma micótico de una rama de la arteria pulmonar

Enric Barbeta Viñas^{a,*}, Daniel Corominas Muñoz^b, Nuria Albacar^a

^a Servicio de Neumología, Instituto Clínico Respiratorio, Hospital Clínico de Barcelona, Spain

^b Centre Diagnòstic per Imatge, Hospital Clínic, Barcelona, Spain

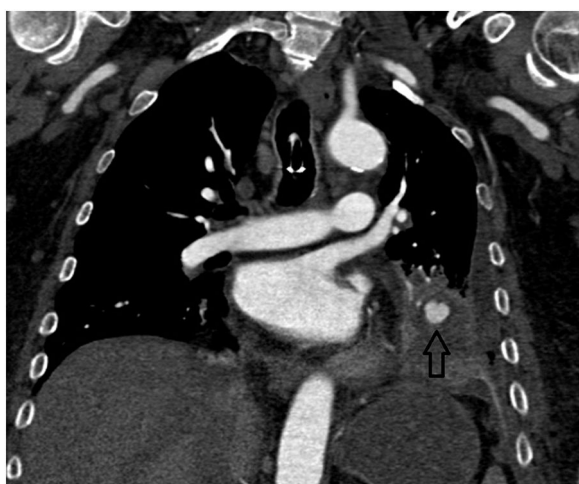


Fig. 1.

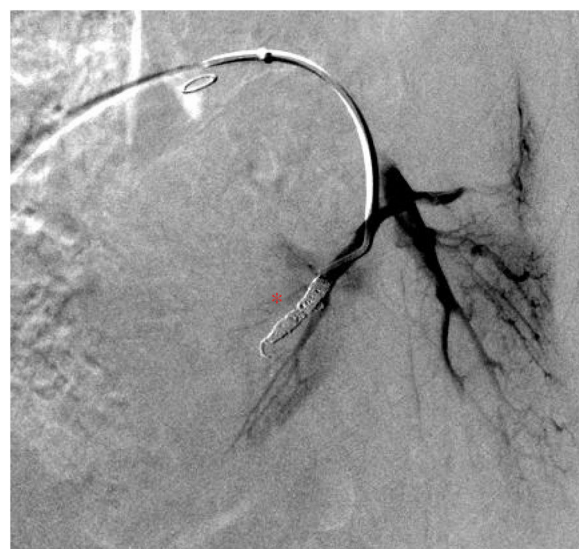

Fig. 2.

A 67-year-old patient suffering from diabetes mellitus type II. He was receiving enteral feeding through a gastrostomy tube due to a laryngeal neoplasm 20 years ago. The current problem was a necrotizing pneumonia from the left lung lobe and a pleural empyema. As a result of this, he presented with massive hemoptysis. A selective arteriography from the bronchial circulation was performed accordingly. Despite the procedure, hemoptysis was not eliminated and the case was thereby referred to our center. A computed tomography with angiographic reconstruction was performed and a pulmonary hematoma coming from a pulmonary artery branch was identified (Fig. 1). The selective pulmonary arteriography showed a nodular-like contrast leak confirming the diagnosis of a pulmonary pseudoaneurism. Microcoils embolization was performed to exclude it (Fig. 2). The patient recovered correctly without any further episodes of massive hemoptysis. Pulmonary artery mycotic aneurisms/pseudoaneurisms are an unusual cause of massive hemoptysis. Necrotizing pneumonia may cause it through extension and direct microorganism invasion to the arterial wall. It is indispensable to recognize them before a selective arteriography procedure, as it guides the access either to the bronchial (systemic) or pulmonary circulation.

* Corresponding author.

E-mail address: ebarbeta@uic.es (E. Barbeta Viñas).