



## IMAGE OF THE MONTH

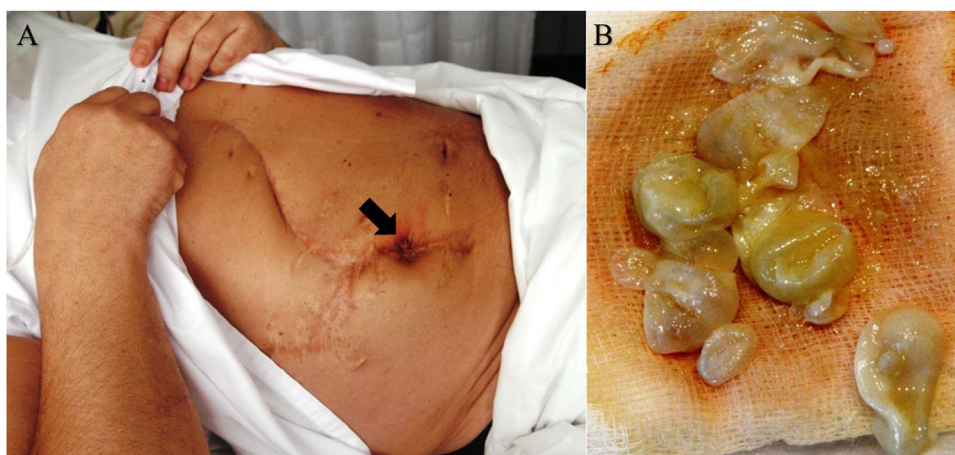
## Spontaneous cutaneous fistula secondary to hepatic hydatidosis

## Fístula cutánea secundaria a hidatidosis hepática

Miguel Sogbe<sup>a,b</sup>, José Luis del Pozo<sup>a,c,d,\*</sup><sup>a</sup> Infectious Diseases Division, Clínica Universidad de Navarra, Pamplona, Spain<sup>b</sup> Internal Medicine Department, Clínica Universidad de Navarra, Pamplona, Spain<sup>c</sup> IdiSNA, Navarra Institute for Health Research, Pamplona, Spain<sup>d</sup> Microbiology Department, Clínica Universidad de Navarra, Pamplona, Spain

A 63-year-old man with a history of cystectomies due to hepatic hydatidosis presented to the emergency department with a 5-day history of abdominal pain, fever, and reddish swelling on the abdominal wall. On physical examination, there was tenderness in the right upper quadrant, an abdominal wall fistula (Fig. 1A, arrow) draining grape-like bodies (Fig. 1B). Laboratory testing revealed: C-reactive

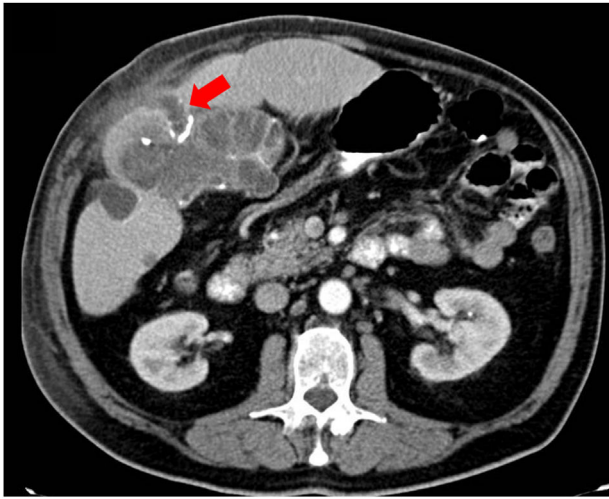
protein 24.8 mg/dl (normal value, <1), total leucocyte count of  $18.6 \times 10^9/L$  (normal value, 4.8–10.8) with 75% neutrophils, total eosinophil count  $0.52 \times 10^9/L$  (normal value, <0.4), total bilirubin 0.71 mg/dl (normal value, <1.2), gamma-glutamyl transpeptidase 152 IU/L (normal value, <0.38), alkaline phosphatase 85 IU/L (normal value, 28–86). Computed tomography of the abdomen revealed multiple



**Figure 1** Cutaneous fistula (arrow) in the right upper quadrant of the abdominal wall (A) with draining grape-like bodies (B).

\* Corresponding author.

E-mail address: [jdelpozo@unav.es](mailto:jdelpozo@unav.es) (J.L. del Pozo).



**Figure 2** Abdominal CT with oral and intravenous contrast with multiple cystic formations in the segment V of the liver with fistulous communication between the abdominal wall and the hydatid vesiculation (red arrow).

cystic formations in the segment V of the liver. A fistulous communication between the abdominal wall and the hydatid vesiculation was observed (Fig. 2, arrow). The serology was positive for *Echinococcus*. The patient was treated with oral albendazole (400 mg bid) three months before surgery. This patient did well after the right hepatectomy and was discharged on postoperative day 5. Histopathology confirmed the clinical diagnosis. No problem occurred over the 3-month follow-up.

### Funding

None declared.

### Conflicts of interest

José Luis del Pozo has been a consultant for Pfizer, MSD, Gilead, and Novartis. Other authors: No reported conflicts.