



## ORIGINAL ARTICLE

# Magnetic resonance imaging for evaluation of bowel inflammation and disease activity in Crohn's disease: A systematic review and meta-analysis



Xian-feng Meng<sup>a</sup>, Qing-yan Lin<sup>b</sup>, Hong-lei Yin<sup>b</sup>, Zeng-qi Li<sup>c,\*</sup>

<sup>a</sup> Department of Medical Imaging, Heilongjiang Provincial Hospital, Harbin, Heilongjiang 150036, China

<sup>b</sup> Department of Respiratory and Critical Care Medicine, Heilongjiang Provincial Hospital, Harbin, Heilongjiang 150036, China

<sup>c</sup> Department of Stomatology, Heilongjiang Provincial Hospital, Harbin, Heilongjiang 150036, China

Received 15 June 2022; accepted 5 October 2022

Available online 13 October 2022

## KEYWORDS

Crohn's disease;  
Magnetic resonance  
imaging;  
Systematic review;  
Meta-analysis

## Abstract

**Background:** The aim of this systematic review and meta-analysis was to determine the performance of magnetic resonance imaging (MRI) in the diagnosis of bowel inflammation and disease activity in Crohn's disease (CD).

**Methods:** MEDLINE, Embase and Web of Science databases of biomedical literature were systematically searched to identify studies that investigated the diagnostic accuracy of MRI in diagnosing bowel inflammation and disease activity in CD by comparing it with reference standards. Quality Assessment of Diagnostic Accuracy Studies-2 tool was used to assess study quality. The summary sensitivity and specificity were estimated using the bivariate model, and hierarchical summary receiver operating characteristic (HSROC) parameters were calculated and plotted.

**Results:** Of 5492 citations of interest, 34 articles contained the diagnostic accuracy data. Of these, results for the small bowel and the colorectum were reported separately in 19 studies and jointly by 21 studies. The meta-analytic summary sensitivity and specificity under the bivariate model were 90.9% (95% CI, 85.8%–94.2%) and 90.2% (95% CI, 81.9%–95.0%), respectively. The sensitivities and specificities of individual studies ranged from 55% to 100% and 51% to 100%, respectively. Substantial heterogeneity was observed in both sensitivity ( $I^2 = 84.9\%$ ) and specificity ( $I^2 = 78.8\%$ ). The HSROC curve also showed considerable heterogeneity between studies.

**Conclusion:** Although the meta-analytic summary accuracy of MRI was high for the diagnosis of bowel inflammation in CD, the summary estimates might be unreliable due to the presence of high heterogeneity.

© 2022 Elsevier España, S.L.U. All rights reserved.

\* Corresponding author.

E-mail address: [lizengqi4866@163.com](mailto:lizengqi4866@163.com) (Z.-q. Li).

**PALABRAS CLAVE**

Enfermedad de Crohn;  
Imagen de resonancia magnética;  
Revisión sistemática;  
Metaanálisis

## Imágenes por resonancia magnética para la evaluación de la inflamación intestinal y la actividad de la enfermedad en la enfermedad de Crohn: una revisión sistemática y un metaanálisis

**Resumen**

**Antecedentes:** El objetivo de esta revisión sistemática y metaanálisis fue determinar el rendimiento de la resonancia magnética nuclear (RM) en el diagnóstico de la inflamación intestinal y la actividad de la enfermedad en la enfermedad de Crohn (EC).

**Métodos:** Se realizaron búsquedas sistemáticas en las bases de datos de literatura biomédica de MEDLINE, Embase y Web of Science para identificar estudios que investigaran la precisión diagnóstica de la RM en el diagnóstico de la inflamación intestinal y la actividad de la enfermedad en la EC comparándola con estándares de referencia. Evaluación de la calidad de los estudios de precisión diagnóstica: se utilizó la herramienta 2 para evaluar la calidad del estudio. La sensibilidad y la especificidad resumidas se estimaron mediante el modelo bivariado, y se calcularon y trazaron los parámetros de características operativas del receptor resumidas jerárquicas (HSROC).

**Resultados:** De 5.492 citas de interés, 34 artículos contenían datos de precisión diagnóstica. De estos, los resultados para el intestino delgado y el colorrectal se informaron por separado en 19 estudios y en forma conjunta en 21 estudios. La sensibilidad y la especificidad del resumen metaanalítico bajo el modelo bivariado fueron del 90,9% (IC del 95%, 85,8%-94,2%) y el 90,2% (IC del 95%, 81,9%-95,0%), respectivamente. Las sensibilidades y especificidades de los estudios individuales variaron del 55 al 100% y del 51 al 100%, respectivamente. Se observó heterogeneidad sustancial tanto en la sensibilidad ( $I^2 = 84,9\%$ ) como en la especificidad ( $I^2 = 78,8\%$ ). La curva HSROC también mostró una considerable heterogeneidad entre los estudios.

**Conclusión:** Aunque la precisión del resumen metaanalítico de la RM fue alta para el diagnóstico de inflamación intestinal en la EC, las estimaciones del resumen pueden no ser confiables debido a la presencia de una gran heterogeneidad.

© 2022 Elsevier España, S.L.U. Todos los derechos reservados.

## Introduction

Crohn's disease (CD) is a type of inflammatory bowel disease that frequently affects the gastrointestinal tract including the small and large bowels.<sup>1–3</sup> As symptoms of comorbid irritable bowel syndrome (IBS) can indicate active disease, it is essential to determine the presence of inflammation prior to commencement of medical or surgical therapy even if CD is in remission.<sup>1</sup> Additionally, it is critical to differentiate between mild, moderate or severe disease as treatments are different for various stages of the disease.<sup>1,4</sup>

Endoscopy is the reference standard for the diagnosis and staging of CD.<sup>2</sup> However, some of its drawbacks include low patient acceptance rates and visualization of only a portion of the bowel.<sup>5</sup> Although computed tomography (CT) is more accurate, patients are subjected to large doses of radiation.<sup>6</sup> Because it is often necessary to frequently assess disease activity and progression of CD, repeated exposure to radiation can increase the risk of cancer incidence. In fact, in the United States of America, approximately 2% of all cancers have been associated with radiation from CT scans.<sup>7</sup>

Magnetic resonance imaging (MRI) is a non-invasive technique that does not involve ionizing radiation. Hence, it is increasingly used to diagnose and stage CD.<sup>5</sup> Whereas some studies have reported MRI to be accurate in both diagnosing and staging CD, others have suggested that MRI is either inferior to colonoscopy or has high rates of false-negatives.<sup>8–13</sup>

This necessitates a systematic review of studies that evaluated the diagnostic accuracy of MRI in CD diagnosis and monitoring.

The aim of the present study was to conduct a systematic review of all relevant studies and to perform a meta-analysis of diagnostic accuracy indices to determine the performance of MRI in the diagnosis of bowel inflammation in patients with CD.

## Materials and methods

### Search strategy

Systematic searches using a combination of search terms including "magnetic resonance imaging", "magnetic resonance enterography", "magnetic resonance enteroclysis", "magnetic resonance enterocolonography", "magnetic resonance colonography", "Crohn's Disease" and "inflammatory bowel disease" were conducted in the Ovid MEDLINE, Ovid Embase, and Web of Science databases of biomedical literature to identify studies relevant to this review.

Initially, titles and/or abstracts were screened, and then full-text articles of potential studies were retrieved to determine eligibility. Only full-text articles and studies published in English were considered for inclusion. Case reports, narrative and systematic reviews, meta-analyses, editorials,

letters, commentaries and conference abstracts or proceedings were excluded. Studies with limited data such as those lacking comparative designs, sensitivity and specificity values, or reference test procedures were also excluded. References lists of all relevant studies and systematic reviews on this topic were hand-searched to identify additional potential studies for inclusion in this meta-analysis.

## Study selection

All identified studies were carefully checked to determine if they met the following inclusion criteria: (1) provided data on disease activity of CD; (2) used MRI, magnetic resonance enterography, magnetic resonance enteroclysis, or magnetic resonance enterocolonography to diagnose inflammation associated with CD; (3) used histopathology, endoscopy, colonoscopy, radiological methods, or surgery as the reference standard.

## Study characteristics

The study characteristics of all included studies were assessed, and relevant data were extracted. Data on study outcomes including true positive, true negative, false positive and false negative rates and the sensitivity and specificity values in the dichotomous diagnosis of bowel inflammation were extracted. For the study design, both observational studies (retrospective or prospective) and randomized controlled trials were considered.

## Patient characteristics

The patient characteristics that were extracted included (1) number of patients in each diagnostic arm (sample size); (2) sex distribution (number of male and female patients); (3) mean age of patients in years (range/variance); (4) part of the gastrointestinal tract examined.

## Study quality assessment

The Quality Assessment of Diagnostic Accuracy Studies-2 (QUADAS-2) tool was used to determine the fulfillment of following criteria<sup>14,15</sup>:

- (1) Representativeness of the patient population who are likely to receive MRI in real-world clinical practice.
- (2) Clear description of patient selection criteria.
- (3) Time between MRI and reference standard (if the time was short enough to ensure that the disease condition did not alter between the tests).
- (4) Whether all patients in the study received the reference standard.
- (5) Whether the entire MRI procedure was described in adequate detail to allow replication.
- (6) Whether there was a description of the reference standard procedure in adequate detail, especially to diagnose the various stages of the disease, to allow replication.
- (7) Whether the MRI and reference standard procedure results were evaluated and interpreted independently.

## Imaging features

For MRI, data on (1) magnetic field strength; (2) coil used; (3) bowel preparation and type (bowel cleansing, fasting or diet status, use of spasmolytics); (4) amount and type of intravenous and/or luminal contrast medium (enteroclysis, oral and/or rectal contrast medium); and (5) bowel sequences used for disease evaluation, were identified and extracted.

## Imaging criteria for staging disease activity

The imaging criteria, including pathological bowel wall thickening, bowel wall enhancement and stenosis that were used to stage CD on MRI were identified and extracted.

## Data synthesis and statistical analysis

### Accuracy of MRI in diagnosing active bowel inflammation

*Descriptive analysis:* The small bowel and colorectum results from all studies were analyzed separately to investigate the effect of bowel location (small versus large bowels) on the accuracy of MRI. The sensitivity and specificity values of MRI and comparator groups in each study and their 95% confidence intervals (CIs) were recorded. The generic inverse variance method was used to weight individual study effect sizes. Higgins  $I^2$  statistics was used to determine the presence of statistical heterogeneity across studies in summary sensitivity and specificity. Substantial heterogeneity was indicated by  $I^2 > 50\%$ . A fixed effects model was used for all outcomes where  $I^2$  was  $< 50\%$ , which was indicative of low heterogeneity across studies, and a random effects model was used where  $I^2$  was  $> 50\%$ . When the fixed-effects model was used, results were re-examined through random effects analysis, as tests of heterogeneity do not definitely exclude variation between studies.<sup>16</sup>

*Meta-analytic summary:* The meta-analytic summary was calculated using the hierarchical modeling methods. The bivariate random-effects model was used to obtain the summary sensitivity and specificity and their 95% CIs.<sup>17</sup> The hierarchical summary receiver operating characteristic (HSROC) model was used to obtain the summary receiver operating characteristic curve.<sup>18</sup>

Review Manager software (version 5.4; Cochrane Collaboration; Nordic Cochrane Center, Copenhagen) was used to summarize article characteristics and to assess the quality of included studies with QUADAS-2 scale. For all other statistical analyses, OpenMeta[Analyst] software (Center for Evidence Synthesis in Health, Brown University, Rhode Island, USA) was used.  $P < 0.05$  was considered statistically significant.

## Results

Initially, 5492 citations of interest were obtained in the electronic searches from which duplicate and non-relevant citations were excluded (Fig. 1). Among the retrieved articles, 40 presented extractable data that were relevant to this meta-analysis. The diagnostic accuracy of MRI was reported by 34 articles. Of these, results for the small bowel

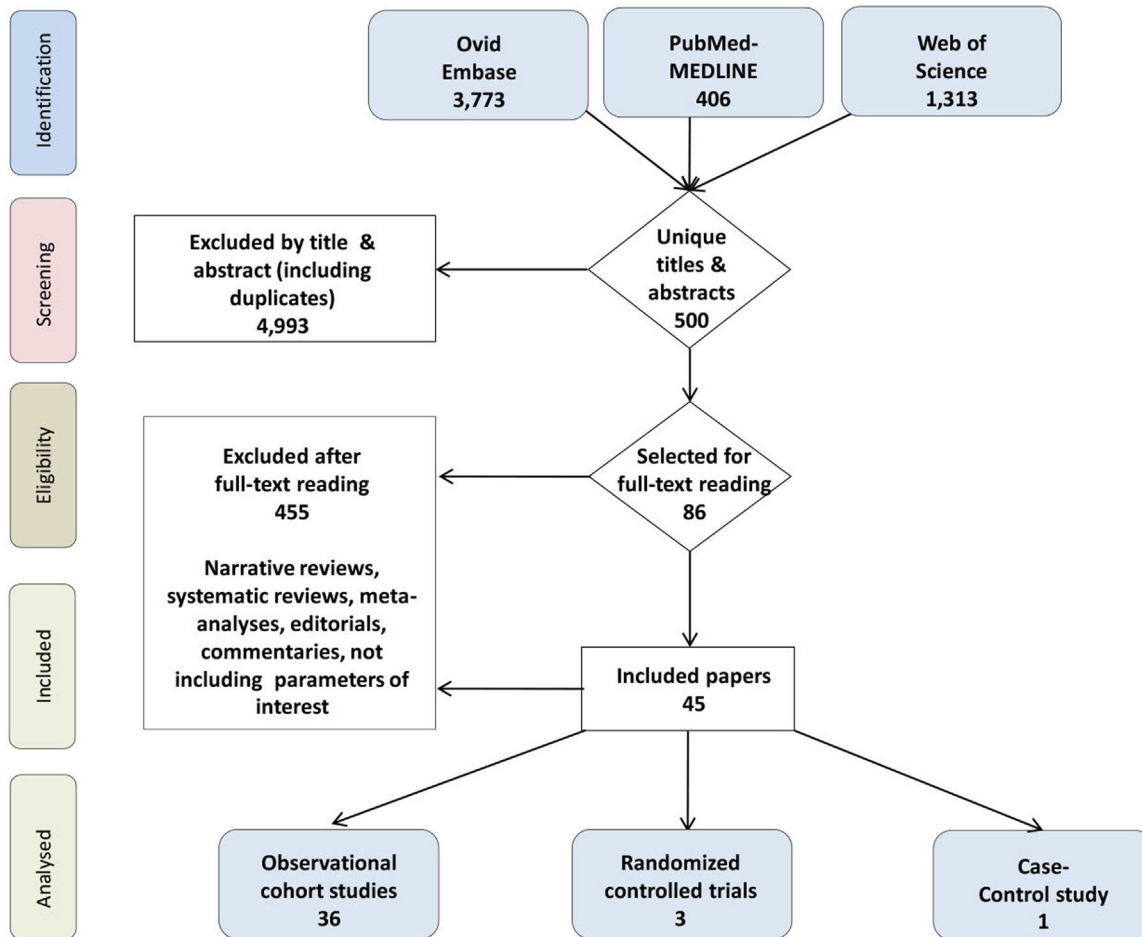


Figure 1 CONSORT flowchart.

and the colorectum were reported separately in 19 and jointly in 21 articles.

### Quality assessment of studies using QUADAS-2

The characteristics of all studies included in this meta-analysis are summarized in Table 1. All studies reported results on a per-bowel segment basis and were single-reader studies. Fig. 2 summarizes the quality of each study included in this meta-analysis. The main concern in these studies was the lack of blinding or no mention of blinding.

### Accuracy of MRI in diagnosing active bowel inflammation (all bowel segments combined)

Results of 38 studies were published in 34 articles (17, 5, and 16 for the small bowel, colorectum, and mixed location, respectively) that provided 2488 bowel segments for the meta-analysis. Table 2 summarizes the results of meta-analysis. The sensitivities and specificities of individual studies in diagnosing active bowel inflammation with MRI ranged from 55% to 100% and 51% to 100%, respectively. Substantial statistical heterogeneity was observed in meta-analysis outcomes for both sensitivity ( $I^2 = 84.9\%$ ) and

specificity ( $I^2 = 78.8\%$ ). The coupled forest plots of sensitivity and specificity did not show a threshold effect (Fig. 3).

The meta-analytic summary sensitivity and specificity under the bivariate model were 90.9% (95% CI, 85.8–94.2) and 90.2% (95% CI, 81.9–95.0), respectively. The HSROC curve also showed considerable heterogeneity between studies (Fig. 4).

### Accuracy of MRI in detecting active bowel inflammation in individual segments

Only 2 studies reported the accuracy of MRI in detecting inflammation in the jejunum (Table 3a).<sup>19,20</sup> In these studies, the sensitivities were 75% (95% CI, 43–94) and 86% (95% CI, 70–94), respectively, whereas the specificities were 94% (95% CI, 73–100) and 96% (95% CI, 82–100).<sup>19,20</sup> The reference standard in both studies were ileocolonoscopy.<sup>19,20</sup>

The accuracy of MRI in detecting inflammation in the proximal and middle ileum was reported by 3 studies (Table 3b).<sup>19–21</sup> All three studies reported high sensitivities and specificities ranging from 87.5% to 100% and 92% to 100%, respectively. The reference standard was ileocolonoscopy in two studies and enteroclysis in one study.<sup>19–21</sup>

Three studies assessed the accuracy of MRI in detecting inflammation in the terminal ileum and reported high

**Table 1** Characteristics of the articles included.

Author	Study design	Study type	Indication for MRE/MRI	Patient age (yr)	Bowel location (sample size)	Preparation and spasmolytics	MR magnet (T)	Overall examination quality	Blinding during MRI/MRE interpretation	Reference standards
Adamek et al.	Prospective	Cohort	Usual clinical indications	18–68	Mixed small and large bowels, 104	2000 ml oral mannitol and buscopan	3.0	Diagnostic in all patients	Yes	Endoscopy, surgical pathology
Aloi et al.	Prospective	Cohort	Usual clinical indications	12.2 ± 4.6	Small bowel, 34	250 ml oral PEG and macrogol	1.5	Diagnostic in all patients	Yes	Consensus reference standard, ileocolonoscopy
Barber et al.	Retrospective	Cohort	Usual clinical indications	5–15	Mixed small and large bowels, 15	Senna and sodium picosulphate combination	1.5	Diagnostic in all patients	Yes	Endoscopy
Beall et al.	Prospective	Cohort	Usual clinical indications	22–84	Mixed bowels, 44	No antiperistaltic, 1.5 contrast agents	1.5	Diagnostic in all patients	No	Helical computed tomography
Borthne et al.	Prospective	Cohort	Usual clinical indications	5–16	Mixed small and large bowels, 43	1000 ml oral mannitol and buscopan	1.5	Diagnostic in all patients	Yes	Endoscopy
Buisson et al.	Prospective	Cohort	Usual clinical indications	12–63	Small bowel, 31	1000 ml oral PEG and glucagon	1.5	Diagnostic in all patients	No	Intravenous contrast-enhanced MRE
Caruso et al.	Retrospective	Cohort	Usual clinical indications	34–45	Small bowel, 55	1500 ml oral PEG and buscopan	1.5	Diagnostic in all patients	No	Intravenous contrast-enhanced MRE and endoscopy
Crook et al.	Prospective	Cohort	Usual clinical indications	25–83	Small bowel, 19	1000 ml oral mannitol and buscopan	1.5	Diagnostic in all patients	Yes	Video capsule endoscopy
Darbari et al.	Prospective	Cohort	Usual clinical indications	13.2 ± 3.8	Mixed small and large bowels, 58	Unstated	Unstated	Diagnostic in all patients	No	Endoscopy, surgical pathology
Fiorino et al.	Prospective	RCT	Usual clinical indications	19–61	Mixed small and large bowels, 44	700 ml oral PEG and glucagon	1.5	Diagnostic in all patients	Yes	Ileocolonoscopy

Table 1 (Continued)

Author	Study design	Study type	Indication for MRE/MRI	Patient age (yr)	Bowel location (sample size)	Preparation and spasmolytics	MR magnet (T)	Overall examination quality	Blinding during MRI/MRE interpretation	Reference standards
Gale et al.	Retrospective	Cohort	Usual clinical indications	4–18	Mixed small and large bowels, 84	450–1350 ml oral PEG and iopamidol	1.5 or 3	Diagnostic in all patients	Yes	Surgical pathology
Gourtsoyiannis et al.	Prospective	Cohort	Usual clinical indications	18–57	Small bowel, 52	1500–2000 ml oral PEG and glucagon	1.5	Diagnostic in all patients	Yes	Enteroclysis
Grand et al.	Retrospective	Cohort	Usual clinical indications	20–94	Mixed small and large bowels, 310	900 cc low-density oral contrast medium	1.5	Diagnostic in all patients	Yes	Endoscopy
Hahneemann et al.	Retrospective	Cohort	Usual clinical indications	15.3–72.5	Small bowel, 30	1000–1500 ml oral mannitol and scopolamine	1.5	Diagnostic in all patients	Yes	Capsule endoscopy and ileocolonoscopy
Hordonneau et al.	Prospective	Cohort	Usual clinical indications	13–70	Small bowel, 352; large bowel, 496	1000 ml oral PEG and glucagon	1.5	Diagnostic in all patients	No	Intravenous contrast-enhanced MRE
Hijaz et al.	Prospective	Cohort	Usual clinical indications	13.48 ± 2.02	Small bowel, 45	480–960 ml oral PEG	Unstated	Diagnostic in all patients	Yes	Surgical pathology
Jensen et al.	Prospective	Cohort	Usual clinical indications	18–76	Small bowel, 50	1000 ml oral mannitol and buscopan	1.5	Diagnostic in all patients	Yes	Ileoscopy
Jesuratnam-Nielsen et al.	Prospective	Cohort	Usual clinical indications	26–76	Mixed small and large bowels, 20	1350 ml oral barium sulphate and buscopan	1.5	Diagnostic in all patients	Yes	Enteroclysis
Kim et al.	Prospective	Cohort	Usual clinical indications	18–42	Mixed small and large bowels, 50	1500 ml 2.5% oral sorbitol and buscopan	3.0	Diagnostic in all patients	Yes	Endoscopy
Lai et al.	Retrospective	Cohort	Usual clinical indications	1–16	Small bowel, 55	2.5% oral isotonic mannitol and anisodamine	1.5	Diagnostic in all patients	Unstated	Video capsule endoscopy and conventional gastrointestinal radiography
Malgras et al.	Retrospective	Cohort	Usual clinical indications	18–69	Mixed small and large bowels, 52	1600 ml water and glucagon	1.5	Diagnostic in all patients	Unstated	Surgical pathology
Miao et al.	Prospective	Cohort	Usual clinical indications	17–78	Mixed small and large bowels, 30	600 ml water and glucagon	1.0	Diagnostic in all patients	Unstated	Endoscopy

**Table 1** (Continued)

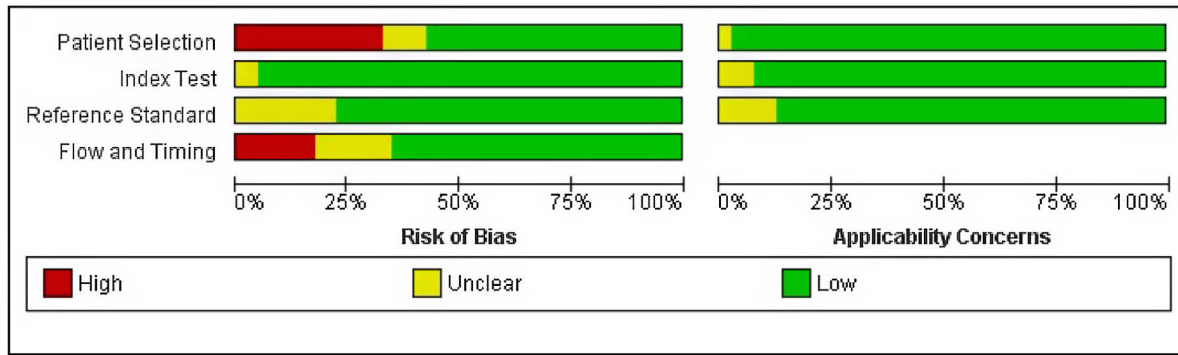
Author	Study design	Study type	Indication for MRE/MRI	Patient age (yr)	Bowel location (sample size)	Preparation and spasmolytics	MR magnet (T)	Overall examination quality	Blinding during MRI/MRE interpretation	Reference standards
Neubauer et al.	Retrospective	Cohort	Usual clinical indications	10–20	Small bowel, 66; large bowel, 66	200–2000 ml oral 2.5% mannitol and buscopan	1.5	Diagnostic in all patients	No	Intravenous contrast-enhanced MRE and endoscopy
Negaard et al.	Prospective	RCT	Usual clinical indications	18–73	Small bowel, 40	1000 ml oral 6% mannitol and buscopan	1.5	Diagnostic in all patients	Yes	Ileoscopy, capsule endoscopy, surgical pathology, ileocolonoscopy
Oliva et al.	Prospective	Cohort	Usual clinical indications	8–18	Mixed small and large bowels, 40	2000 ml oral PEG and domperidone	Unstated	Diagnostic in all patients	Yes	Endoscopy and surgical pathology
Oto et al. <sup>1</sup>	Retrospective	Cohort	Usual clinical indications	21–74	Large bowel, 45	1350 ml oral VoLumen and glucagon	1.5	Diagnostic in all patients	Unstated	Endoscopy and surgical pathology
Oto et al. <sup>2</sup>	Retrospective	Case-control	Usual clinical indications	20–53	Small bowel, 36	1350 ml oral VoLumen and glucagon	1.5	Unstated	Unstated	Endoscopy and surgical pathology
Potthast et al.	Retrospective	Cohort	Usual clinical indications	14–74	Small bowel, 46	1200 ml water and 1.5 buscopan	1.5	Diagnostic in all patients	Unstated	Enteroclysis
Qi et al.	Retrospective	Cohort	Usual clinical indications	13–63	Small bowel, 100	1000 ml oral PEG and buscopan	3.0	Unstated	Yes	Endoscopy
Rieber et al.	Retrospective	RCT	Usual clinical indications	19–81	Small bowel, 84	1000 ml oral barium sulfate and buscopan	1.5	Diagnostic in all patients	Unstated	Enteroclysis
Sato et al.	Prospective	Cohort	Unspecified	18–67	Mixed small and large bowels, 141	1000–1500 ml oral PEG and buscopan	1.5	Unstated	Unstated	Endoscopy
Schmidt et al.	Prospective	Cohort	Usual clinical indications	19–66	Mixed small and large bowels, 48	2000 ml oral barium sulfate and buscopan	1.5	Diagnostic in all patients	Yes	Enteroclysis
Schreyer et al.	Prospective	Cohort	Usual clinical indications	18–65	Mixed small and large bowels, 30	1000 ml oral mannitol and buscopan	1.5	Diagnostic in all patients	Yes	Conventional colonoscopy

**Table 1** (Continued)

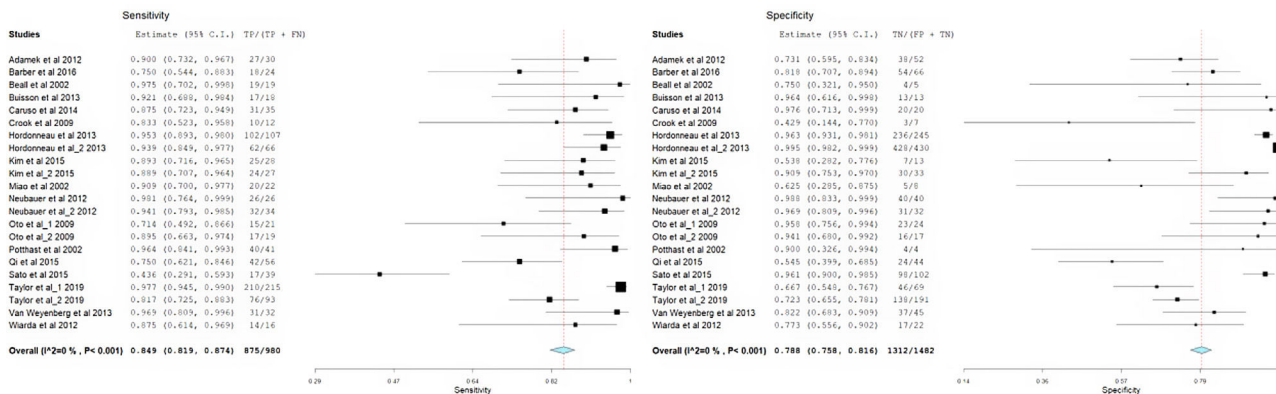
Author	Study design	Study type	Indication for MRE/MRI	Patient age (yr)	Bowel location (sample size)	Preparation and spasmolytics	MR magnet (T)	Overall examination quality	Blinding during MRI/MRE interpretation	Reference standards
Seastedt et al.	Retrospective	Cohort	Usual clinical indications	18–78	Mixed small and large bowels, 76	1350 ml oral barium sulfate and glucagon	1.5	Diagnostic in all patients	Unstated	Enterography
Sinha et al.	Prospective	Cohort	Usual clinical indications	19–81	Mixed small and large bowels, 49	1200–1300 ml oral mannitol and buscopan	1.5	Diagnostic in all patients	Yes	Enterography
Taylor et al.	Prospective	Cohort	Usual clinical indications	16–45	Small bowel, 284	3350 ml oral mannitol or PEG	1.5	Diagnostic in all patients	Yes	Endoscopy
Van Weyenberg et al.	Retrospective	Cohort	Usual clinical indications	4–83	Mixed small and large bowels, 77	2000 ml 0.5% oral methyl-cellulose	1.5	Diagnostic in all patients	Unstated	Capsule endoscopy
Wiarda et al.	Prospective	Cohort	Usual clinical indications	20–74	Small bowel, 38	1000–3000 ml 0.5% methyl-cellulose and buscopan	Unstated	Diagnostic in all patients	Yes	Balloon-assisted enteroscopy
Yüksel et al.	Prospective	Cohort	Usual clinical indications	26–61	Mixed small and large bowels, 25	1500–2000 ml 3% oral mannitol and buscopan	1.5	Diagnostic in all patients	Yes	Endoscopy
Ziech et al.	Prospective	Cohort	Usual clinical indications	10–17	Mixed small and large bowels, 28	400 ml 3.5% oral sorbitol and buscopan	3.0	Diagnostic in all patients	Unstated	Endoscopy and surgical pathology

MRE, magnetic resonance enterography; RCT, randomized controlled trial.





**Figure 2** Results of quality assessments, risk of bias and applicability concerns of the articles according to QUADAS-2 criteria. The methodological quality of all included articles is presented as the proportion of articles (0%–100%) with low (i.e., high quality), high, or unclear risks of bias and the proportion of articles with low (i.e., high quality), high, or unclear concerns regarding applicability for each domain. For articles analyzed in this study, regarding flow and timing, 64%, 16%, and 20% had low, high, and unclear risks of bias, respectively.



**Figure 3** Forest graph showing the sensitivity and specificity of MRI in diagnosing bowel inflammation in CD patients.

sensitivities and specificities ranging from 94% to 100% and 80% to 91%, respectively (Table 3c).<sup>19–21</sup>

### Accuracy of MRI in detecting other aspects of Crohn's disease

The accuracy of MRI in detecting bowel wall thickening was reported by 5 studies (Table 4a).<sup>22–26</sup> Reference standards used were ileocolonoscopy, surgical pathology, enteroclysis, enterography and capsule endoscopy. The sensitivities ranged from 62.5% to 90% and specificities from 86% to 100%.<sup>22–26</sup>

Four studies (Table 4b) reported the accuracy of MRI in detecting bowel wall enhancement. The sensitivities ranged from 53% to 93% and specificities from 53% to 96%.<sup>22,23,25,26</sup>

The accuracy of MRI in detecting fistulas was reported by 7 studies (Table 4c).<sup>21,22,24,26–29</sup> Enteroclysis, enterography and ileocolonoscopy were the reference standards used. The sensitivities ranged from 40% to 100% and specificities from 93% to 100%.<sup>21,22,24,26–29</sup>

Two studies reported the accuracy of MRI in detecting strictures (Table 4d).<sup>22,26</sup> Ileocolonoscopy and enterography were the reference standards used. Whereas the

sensitivity and specificity in one study were 92% and 90%, respectively;<sup>22</sup> the other reported the sensitivity and specificity of 56% and 98%, respectively.<sup>26</sup>

The accuracy of MRI in detecting superficial and deep ulcers was reported by two studies (Table 4e and f).<sup>24,26</sup> Enteroclysis and enterography were the reference standards used. In one study, the sensitivity and specificity of detecting superficial ulcers were 57.1% and 85.7%, respectively, whereas the sensitivity and specificity of detecting deep ulcers were 89.5% and 100%, respectively.<sup>24,26</sup> In the other study, the sensitivity and specificity of detecting superficial ulcers were 50% and 97%, respectively, whereas the sensitivity and specificity of detecting deep ulcers were 69% and 98%, respectively.<sup>26</sup>

Five studies reported the accuracy of MRI in detecting stenosis (Table 4g). Enteroclysis, enterography, ileoscopy, capsule endoscopy and surgical pathology were the reference standards used. The sensitivities ranged from 44.4% to 100% and specificities from 92.9% to 100%.<sup>21,24,25,28,29</sup>

The accuracy of MRI in detecting abscess was reported by five studies (Table 4h). Enteroclysis and enterography were the reference standards used. The sensitivities ranged from 77% to 100% and the specificities from 87% to 100%.<sup>21,26–29</sup>

**Table 2** Accuracy of MRI in diagnosing active bowel inflammation.

Author	Bowel location	Reference standard	Number of bowel segments				Sensitivity (%)	Specificity (%)
			TP	FP	FN	TN	(95% CI)	(95% CI)
Adamek et al.	Mixed	Endoscopy, surgical pathology	27	3	14	38	65.9	76
Aloi et al.	Small	Consensus reference standard, ileocolonoscopy	–	–	–	–	88 (71, 97)	89 (78, 96)
Barber et al.	Mixed	Endoscopy	18	6	12	54	60 (40.6, 77.3)	90 (79.5, 96.2)
Beall et al.	Mixed	Helical computed tomography	19	0	1	4	95	100
Borthne et al.	Mixed	Endoscopy	–	–	–	–	81.8 (52.0, 94.8)	100 (70.1, 100)
Buisson et al.	Small	Intravenous contrast-enhanced MRE	17	1	0	13	100 (80, 100)	93 (66, 100)
Caruso et al.	Small	Intravenous contrast-enhanced MRE and endoscopy	31	4	0	20	100 (89, 100)	83 (63, 95)
Crook et al.	Small	Video capsule endoscopy	10	2	4	3	71.4	60
Darbari et al.	Mixed	Endoscopy, surgical pathology	–	–	–	–	96.4 (81.7, 99.9)	92.3 (64.0, 99.8)
Fiorino et al.	Mixed	Ileocolonoscopy	–	–	–	–	88 (78, 99)	88 (68, 100)
Grand et al.	Mixed	Endoscopy	–	–	–	–	85	85
Hahnemann et al.	Small	Capsule endoscopy and ileocolonoscopy	–	–	–	–	55.2	99.5
Hordonneau et al.	Small	Intravenous contrast-enhanced MRE	102	5	9	236	92 (85, 96)	98 (95, 99)
Hordonneau et al.	Large	Intravenous contrast-enhanced MRE	62	4	2	428	97 (89, 100)	99 (98, 100)
Hijaz et al.		Small Surgical pathology	–	–	–	–	100 (55, 100)	57.1 (28.9, 82.3)
Jensen et al.	Small	Ileoscopy	–	–	–	–	74 (57, 88)	80 (44, 98)
Jesuratnam-Nielsen et al.	Mixed	Enteroclysis	–	–	–	–	75 (23, 99)	93 (91, 93)
Kim et al.	Small	Endoscopy	25	3	6	7	81 (63, 93)	70 (35, 93)
Kim et al.	Large	Endoscopy	24	29	3	30	89 (71, 98)	51 (37, 64)
Lai et al.	Small	VCE and conventional gastrointestinal radiography	–	–	–	–	85.7	70
Malgras et al.	Mixed	Surgical pathology	–	–	–	–	100	–
Miao et al.	Mixed	Endoscopy	20	2	3	5	87	71
Neubauer et al.	Small	Intravenous contrast-enhanced MRE and endoscopy	26	0	0	40	100 (87, 100)	100 (91, 100)
Neubauer et al.	Large	Intravenous contrast-enhanced MRE and endoscopy	32	2	1	31	97 (84, 100)	94 (80, 99)

**Table 2** (Continued)

Author	Bowel location	Reference standard	Number of bowel segments				Sensitivity (%)	Specificity (%)
			TP	FP	FN	TN	(95% CI)	(95% CI)
Oliva et al.	Mixed	Ileocolonoscopy	–	–	–	–	85 (70, 94)	89 (74, 96)
Oto et al. <sup>1</sup>	Large	Endoscopy and surgical pathology	15	6	1	23	94 (70, 100)	79 (60, 92)
Oto et al. <sup>2</sup>	Small	Endoscopy and surgical pathology	17	2	1	16	94 (73, 100)	89 (65, 99)
Potthast et al.	Small	Enteroclysis	40	1	0	4	100	80
Qi et al.	Small	Endoscopy	42	14	20	24	68 (55, 79)	63 (46, 78)
Rieber et al.	Small	Enteroclysis	–	–	–	–	95.2	92.6
Sato et al.	Mixed	Endoscopy	17	22	4	98	81 (58, 95)	82 (74, 88)
Schreyer et al.	Mixed	Conventional colonoscopy	–	–	–	–	55.1	98.2
Taylor et al.	Small	Endoscopy	210	5	23	46	97 (91, 99)	96 (86, 99)
Taylor et al.	Large	Endoscopy	76	17	53	138	64 (50, 75)	96 (90, 98)
Van Weyenberg et al.	Mixed	Capsule endoscopy	31	1	8	37	79 (63, 90)	97 (85, 100)
Wiarda et al.	Small	Balloon-assisted enteroscopy	14	2	5	17	73	90
Yüksel et al.	Mixed	Endoscopy	–	–	–	–	92	–
Ziech et al.	Mixed	Endoscopy and surgical pathology	–	–	–	–	57	100

CI, confidence interval; FN, false negative; FP, false positive; MRE, magnetic resonance enterography; MRI, magnetic resonance imaging; TN, true negative; TP, true positive; VCE, video capsule endoscopy.

**Table 3** Accuracy of MRI in detecting inflammation.

Author	Bowel location	Reference standard	PPV (%)	NPV (%)	Sensitivity (%) (95% CI)	Specificity (%) (95% CI)
<i>a: Accuracy of MRI in detecting inflammation in the jejunum</i>						
Aloi et al.	Small	Consensus reference standard, ileocolonoscopy	90 (55, 100)	85 (62, 97)	75 (43, 94)	94 (73, 100)
Oliva et al.	Mixed	Ileocolonoscopy	92 (78, 98)	92 (77, 98)	86 (70, 94)	96 (82, 100)
<i>b: Accuracy of MRI in detecting inflammation in the proximal and mid ileum</i>						
Aloi et al.	Small	Consensus reference standard, ileocolonoscopy	67 (43, 96)	100 (84, 100)	100 (56, 100)	92 (73, 99)
Oliva et al.	Mixed	Ileocolonoscopy	83 (67, 93)	96 (83, 100)	91 (76, 97)	92 (78, 98)
Potthast et al.	Small	Enteroclysis	–	–	87.5	100
<i>c: Accuracy of MRI in detecting inflammation in the terminal ileum</i>						
Aloi et al.	Small	Consensus reference standard, ileocolonoscopy	84 (60, 97)	92 (64, 100)	94 (71, 100)	80 (51, 96)
Oliva et al.	Mixed	Ileocolonoscopy	88 (73, 96)	95 (82, 99)	94 (80, 99)	91 (76, 97)
Potthast et al.	Small	Enteroclysis	–	–	100	80

CI, confidence interval; MRI, magnetic resonance imaging; NPV, negative predictive value; PPV, positive predictive value.

## Discussion

This systematic review and meta-analysis has demonstrated that MRI has high accuracy in diagnosing active bowel inflammation with the meta-analytic summary sensitivity and specificity of 90.9% (95% CI, 85.8%–94.2%)

and 90.2% (95% CI, 81.9%–95.0%), respectively. However, there was high statistical heterogeneity between studies as indicated by  $I^2$  of 85% for sensitivity and  $I^2$  of 79% for specificity. Hence, these meta-analytical summary estimates do not achieve sufficient degree of reliability.

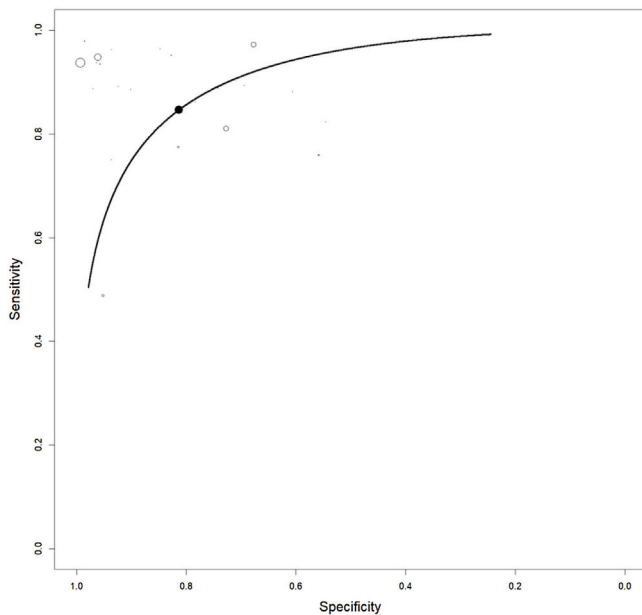
**Table 4** Accuracy of MRI in detecting symptoms in Crohn's disease.

Author	Bowel location	Reference standard	PPV (%)	NPV (%)	Sensitivity (%) (95% CI)	Specificity (%) (95% CI)
<i>a: Accuracy of MRI in detecting bowel wall thickening in Crohn's disease</i>						
Fiorino et al.	Mixed	Ileocolonoscopy	–	–	90 (86, 100)	91 (76, 100)
Gale et al.	Mixed	Surgical pathology	–	–	69 (64, 74)	91 (87, 94)
Gourtsoyiannis et al.	Small	Enteroclysis	100	84.6	62.5	100.0
Negaard et al.	Small	Ileoscopy, capsule endoscopy, surgical pathology	89	89	88	89
Sinha et al.	Mixed	Enterography	90	72	79 (62, 91)	86 (68, 96)
<i>b: Accuracy of MRI in detecting bowel wall enhancement in Crohn's disease</i>						
Fiorino et al.	Mixed	Ileocolonoscopy	–	–	81 (65, 97)	95 (86, 100)
Gale et al.	Mixed	Surgical pathology	–	–	53 (47, 59)	96 (93, 98)
Negaard et al.	Small	Ileoscopy, capsule endoscopy, surgical pathology	93	94	93	94
Sinha et al.	Mixed	Enterography	50	91	89 (69, 98)	53 (42, 57)
<i>c: Accuracy of MRI in detecting fistulas in Crohn's disease</i>						
Fiorino et al.	Mixed	Ileocolonoscopy	–	–	40 (0, 82)	94 (87, 100)
Gourtsoyiannis et al.	Small	Enteroclysis	75	100	100	97.8
Potthast et al.	Small	Enteroclysis	–	–	87	93
Rieber et al.	Small	Enteroclysis	–	–	70.6	–
Schmidt et al.	Mixed	Enteroclysis	–	–	44.4	100
Seastedt et al.	Mixed	Enterography	100	81	60	100
Sinha et al.	Mixed	Enterography	100	95	76 (61, 77)	99 (95, 99)
<i>d: Accuracy of MRI in Detecting Strictures in Crohn's disease</i>						
Fiorino et al.	Mixed	Ileocolonoscopy	–	–	92 (79, 100)	90 (79, 100)
Sinha et al.	Mixed	Enterography	100	88	56 (41, 63)	98 (93, 99)
<i>e: Accuracy of MRI in detecting superficial ulcers in Crohn's disease</i>						
Gourtsoyiannis et al.	Small	Enteroclysis	40	92.3	57.1	85.7
Sinha et al.	Mixed	Enterography	89	84	50 (38, 55)	97 (93, 99)
<i>f: Accuracy of MRI in detecting deep ulcers in Crohn's disease</i>						
Gourtsoyiannis et al.	Small	Enteroclysis	100	93.8	89.5	100
Sinha et al.	Mixed	Enterography	96	90	69 (56, 71)	98 (92, 99)
<i>g: Accuracy of MRI in detecting stenosis in Crohn's disease</i>						
Gourtsoyiannis et al.	Small	Enteroclysis	91.3	100	100	92.9
Negaard et al.	Small	Ileoscopy, capsule endoscopy, surgical pathology	75	96	86	93
Potthast et al.	Small	Enteroclysis	–	–	100	96
Schmidt et al.	Mixed	Enteroclysis	–	–	44.4	100
Seastedt et al.	Mixed	Enterography	100	65	68	100
<i>h: Accuracy of MRI in detecting abscess in Crohn's disease</i>						
Potthast et al.	Small	Enteroclysis	–	–	100	97
Rieber et al.	Small	Enteroclysis	–	–	77.8	–
Schmidt et al.	Mixed	Enteroclysis	–	–	83.3	100
Seastedt et al.	Mixed	Enterography	87	97	87	87
Sinha et al.	Mixed	Enterography	100	98	77 (48, 79)	100 (97, 100)

CI, confidence interval; MRI, magnetic resonance imaging; NPV, negative predictive value; PPV, positive predictive value.

Consistent with the high statistical heterogeneity in the results of this meta-analysis, the diagnostic accuracies for bowel inflammation of CD reported in individual studies were also highly heterogeneous, as sensitivity and

specificity values ranged from 55% to 100% and 51% to 100%, respectively. Thirty three percent of the included studies reported sensitivity below 80% and 22% of the included studies reported specificity below 80%. Furthermore, not all



**Figure 4** HSROC curve for the accuracy of MRI in diagnosing active bowel inflammation in CD patients. The sample sizes of individual studies are indicated by the sizes of the clear circles (individual study estimate). The dark circle on the HSROC curve indicates the summary point estimate.

bowel segments or conditions affecting the bowel in CD were evaluated in all studies, making it difficult to identify the accuracy of MRI for all bowel segments and all conditions.

Among the reference standards, endoscopy was the most utilized modality which was used in 51% the included studies. This was followed by the surgical pathology (18%), enteroclysis (9%), and enterography (9%). Moreover, many studies used more than one reference standards. Use of different reference standards may also be the source of heterogeneity. Bowel preparation is also an important confounder in the outcomes of endoscopies and may also affect MRI outcomes. Moreover, recently it has been found that the timing of bowel preparation may also affect the outcomes of a test or reference. All such factors can affect the outcomes of individual studies and thence bring heterogeneity in the meta-analysis. Included studies were either prospective or retrospective in design. Retrospective studies may have several types of biases inherently that can affect the outcomes of a meta-analysis combining data arising from studies with different designs.

This meta-analytical review has some limitations. Firstly, statistical heterogeneity was high in the meta-analytical summary estimates which attenuates the reliability of MRI in CD diagnosis. It was difficult to determine the causes of between-study statistical heterogeneity due to less availability of related information in the research articles of the included studies. Secondly, methodological issues might have also played a role in outcomes observed herein. For example, most studies did not specify the exact criteria to define test positivity on MRI. Moreover, the quality of the examination for individual bowel segments was also not separately reported.

## Conclusions

The meta-analytic summary accuracy of MRI was quite high for the diagnosis of bowel inflammation in CD. However, it is likely that some studies may have overestimated the accuracy of MRI, as adequate blinding was not used during interpretation of the MRI or was not reported by some studies. Hence, this could have accounted for the large between-study statistical heterogeneity observed herein. As a result, the meta-analytic summary estimates might be unreliable. Nevertheless, MRI can be used for the diagnosis of bowel inflammation in CD.

## Funding

This research was supported by the Heath Commission of Heilongjiang Province (No. 2020-245).

## Conflict of interest

None.

## Acknowledgements

None.

## References

1. Choi SH, Kim KW, Lee JY, Kim KJ, Park SH. Diffusion-weighted magnetic resonance enterography for evaluating bowel inflammation in Crohn's disease: a systematic review and meta-analysis. *Inflamm Bowel Dis.* 2016;22:669–79, <http://dx.doi.org/10.1097/mib.0000000000000607>.
2. Veauthier B, Hornecker JR. Crohn's disease: diagnosis and management. *Am Fam Physician.* 2018;98:661–9.
3. Baumgart DC, Sandborn WJ. Crohn's disease. *Lancet.* 2012;380:1590–605, [http://dx.doi.org/10.1016/s0140-6736\(12\)60026-9](http://dx.doi.org/10.1016/s0140-6736(12)60026-9).
4. Baumgart DC, Sandborn WJ. Inflammatory bowel disease: clinical aspects and established and evolving therapies. *Lancet.* 2007;369:1641–57, [http://dx.doi.org/10.1016/s0140-6736\(07\)60751-x](http://dx.doi.org/10.1016/s0140-6736(07)60751-x).
5. Horsthuis K, Bipat S, Stokkers PC, Stoker J. Magnetic resonance imaging for evaluation of disease activity in Crohn's disease: a systematic review. *Eur Radiol.* 2009;19:1450–60, <http://dx.doi.org/10.1007/s00330-008-1287-0>.
6. Desmond AN, O'Regan K, Curran C, McWilliams S, Fitzgerald T, Maher MM, et al. Crohn's disease: factors associated with exposure to high levels of diagnostic radiation. *Gut.* 2008;57:1524–9, <http://dx.doi.org/10.1136/gut.2008.151415>.
7. Brenner DJ, Hall EJ. Computed tomography – an increasing source of radiation exposure. *N Engl J Med.* 2007;357:2277–84, <http://dx.doi.org/10.1056/NEJMra072149>.
8. Horsthuis K, Bipat S, Bennink RJ, Stoker J. Inflammatory bowel disease diagnosed with US MR, scintigraphy, and CT: meta-analysis of prospective studies. *Radiology.* 2008;247:64–79, <http://dx.doi.org/10.1148/radiol.2471070611>.
9. Ryan ER, Heaslip IS. Magnetic resonance enteroclysis compared with conventional enteroclysis and computed tomography enteroclysis: a critically appraised topic. *Abdom Imaging.* 2008;33:34–7, <http://dx.doi.org/10.1007/s00261-007-9308-z>.
10. Schreyer AG, Gölder S, Scheibl K, Völk M, Lenhart M, Timmer A, et al. Dark lumen magnetic resonance

- enteroclysis in combination with MRI colonography for whole bowel assessment in patients with Crohn's disease: first clinical experience. *Inflamm Bowel Dis.* 2005;11:388–94, <http://dx.doi.org/10.1097/01.mib.0000164022.72729.06>.
11. Schreyer AG, Rath HC, Kikinis R, Völk M, Schölmerich J, Feuerbach S, et al. Comparison of magnetic resonance imaging colonography with conventional colonoscopy for the assessment of intestinal inflammation in patients with inflammatory bowel disease: a feasibility study. *Gut.* 2005;54:250–6, <http://dx.doi.org/10.1136/gut.2003.037390>.
  12. Albert J, Scheidt T, Basler B, Pahle U, Schilling D, Layer G, et al. [Magnetic resonance imaging in diagnosis and follow-up of Crohn's disease – is conventional enteroclysis still necessary?]. *Z Gastroenterol.* 2002;40:789–94, <http://dx.doi.org/10.1055/s-2002-33875>.
  13. Ajaj WM, Lauenstein TC, Pelster G, Gerken G, Ruehm SG, Debatin JF, et al. Magnetic resonance colonography for the detection of inflammatory diseases of the large bowel: quantifying the inflammatory activity. *Gut.* 2005;54:257–63, <http://dx.doi.org/10.1136/gut.2003.037085>.
  14. Whiting P, Rutjes AW, Reitsma JB, Bossuyt PM, Kleijnen J. The development of QUADAS: a tool for the quality assessment of studies of diagnostic accuracy included in systematic reviews. *BMC Med Res Methodol.* 2003;3:25, <http://dx.doi.org/10.1186/1471-2288-3-25>.
  15. Whiting PF, Weswood ME, Rutjes AW, Reitsma JB, Bossuyt PN, Kleijnen J. Evaluation of QUADAS, a tool for the quality assessment of diagnostic accuracy studies. *BMC Med Res Methodol.* 2006;6:9, <http://dx.doi.org/10.1186/1471-2288-6-9>.
  16. Higgins JP, Thompson SG, Deeks JJ, Altman DG. Measuring inconsistency in meta-analyses. *BMJ.* 2003;327:557–60, <http://dx.doi.org/10.1136/bmj.327.7414.557>.
  17. Reitsma JB, Glas AS, Rutjes AW, Scholten RJ, Bossuyt PM, Zwinderman AH. Bivariate analysis of sensitivity and specificity produces informative summary measures in diagnostic reviews. *J Clin Epidemiol.* 2005;58:982–90, <http://dx.doi.org/10.1016/j.jclinepi.2005.02.022>.
  18. Rutter CM, Gatsonis CA. A hierarchical regression approach to meta-analysis of diagnostic test accuracy evaluations. *Stat Med.* 2001;20:2865–84, <http://dx.doi.org/10.1002/sim.942>.
  19. Aloï M, Di Nardo G, Romano G, Casciani E, Civitelli F, Oliva S, et al. Magnetic resonance enterography, small-intestine contrast US, and capsule endoscopy to evaluate the small bowel in pediatric Crohn's disease: a prospective, blinded, comparison study. *Gastrointest Endosc.* 2015;81:420–7, <http://dx.doi.org/10.1016/j.gie.2014.07.009>.
  20. Oliva S, Cucchiara S, Civitelli F, Casciani E, Di Nardo G, Hassan C, et al. Colon capsule endoscopy compared with other modalities in the evaluation of pediatric Crohn's disease of the small bowel and colon. *Gastrointest Endosc.* 2016;83:975–83, <http://dx.doi.org/10.1016/j.gie.2015.08.070>.
  21. Potthast S, Rieber A, Von Tirpitz C, Wruk D, Adler G, Brambs HJ. Ultrasound and magnetic resonance imaging in Crohn's disease: a comparison. *Eur Radiol.* 2002;12:1416–22, <http://dx.doi.org/10.1007/s00330-001-1191-3>.
  22. Fiorino G, Bonifacio C, Peyrin-Biroulet L, Minuti F, Repici A, Spinelli A, et al. Prospective comparison of computed tomography enterography and magnetic resonance enterography for assessment of disease activity and complications in ileocolonic Crohn's disease. *Inflamm Bowel Dis.* 2011;17:1073–80, <http://dx.doi.org/10.1002/ibd.21533>.
  23. Gale HI, Sharatz SM, Taphey M, Bradley WF, Nimkin K, Gee MS. Comparison of CT enterography and MR enterography imaging features of active Crohn disease in children and adolescents. *Pediatr Radiol.* 2017;47:1321–8, <http://dx.doi.org/10.1007/s00247-017-3876-z>.
  24. Gourtsoyiannis NC, Grammatikakis J, Papamastorakis G, Koutroumbakis J, Prassopoulos P, Rousomoustakaki M, et al. Imaging of small intestinal Crohn's disease: comparison between MR enteroclysis and conventional enteroclysis. *Eur Radiol.* 2006;16:1915–25, <http://dx.doi.org/10.1007/s00330-006-0248-8>.
  25. Negaard A, Paulsen V, Sandvik L, Berstad AE, Borthne A, Try K, et al. A prospective randomized comparison between two MRI studies of the small bowel in Crohn's disease, the oral contrast method and MR enteroclysis. *Eur Radiol.* 2007;17:2294–301, <http://dx.doi.org/10.1007/s00330-007-0648-4>.
  26. Sinha R, Murphy P, Sanders S, Ramachandran I, Hawker P, Rawat S, et al. Diagnostic accuracy of high-resolution MR enterography in Crohn's disease: comparison with surgical and pathological specimen. *Clin Radiol.* 2013;68:917–27, <http://dx.doi.org/10.1016/j.crad.2013.02.012>.
  27. Rieber A, Aschoff A, Nüssle K, Wruk D, Tomczak R, Reinshagen M, et al. MRI in the diagnosis of small bowel disease: use of positive and negative oral contrast media in combination with enteroclysis. *Eur Radiol.* 2000;10:1377–82, <http://dx.doi.org/10.1007/s003300000354>.
  28. Schmidt T, Reinshagen M, Brambs HJ, Adler G, Rieber AC, Kratzer VTW. [Comparison of conventional enteroclysis, intestinal ultrasound and MRI-enteroclysis for determining changes in the small intestine and complications in patients with Crohn's disease]. *Z Gastroenterol.* 2003;41:641–8, <http://dx.doi.org/10.1055/s-2003-40547>.
  29. Seastedt KP, Trencheva K, Michelassi F, Alsaleh D, Milson JW, Sonoda T, et al. Accuracy of CT enterography and magnetic resonance enterography imaging to detect lesions preoperatively in patients undergoing surgery for Crohn's disease. *Dis Colon Rectum.* 2014;57:1364–70, <http://dx.doi.org/10.1097/dcr.0000000000000244>.