

Actas Urológicas Españolas

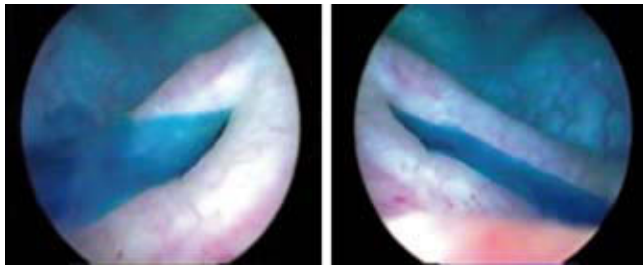
www.elsevier.es/actasuro



Images in Urology

Positive indigo carmin test to verify ureteral indemnity in vaginal surgery

Prueba ureteral positiva con índigo carmín, para verificar indemnidad de los uréteres en cirugía vaginal



Figures 1 and 2 – CAT views showing a double cava system causing compression hydronephrosis in an adolescent male.

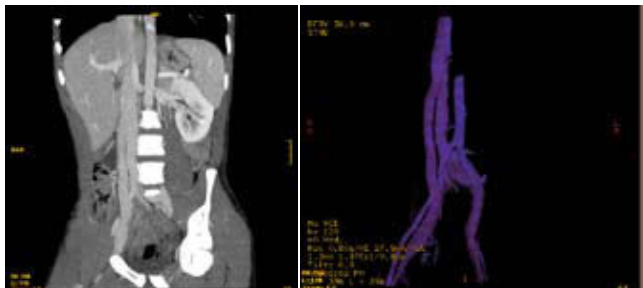
P. Ricci Arriola*, J. Pardo Schanz, and V. Solà Dalenz

Urogynecology and Vaginal Surgery Unit, Clínica Las Condes, Santiago, Chile

*Author for correspondence.

E-mail: pricci@cclinicalascondes.cl (P. Ricci Arriola).

Right hydro nephrosis in a young Hidronefrosis derecha en adolescente



Figures 1 and 2 – CAT scan showing a double cava system in different sections and in three-dimensional reconstruction.

J. Martínez Ruiz*, J. Gabriel Lorenzo Romero, H. Pastor Navarro, P. Carrión López, C. Martínez Sanchiz, and J.A. Virseda Rodríguez

Department of Urology, Complejo Hospitalario Universitario de Albacete, Albacete, Spain

*Author for correspondence.

E-mail: jesus.martinez.ruiz@gmail.com (J. Martínez Ruiz).