

# ACTAS UROLÓGICAS ESPAÑOLAS

www.elsevier.es/actasuro



## Short original – Suprarenal

## Laparoscopic adrenalectomy for metachronous metastasis. Experience in 12 cases

J. I. Pascual Piédrola\*, A. Rincón Mayans, E. Tolosa Eizaguirre, J. Barba Abad, L. Romero Vargas and D. Rosell Costa

Department of Urology, Clínica Universidad de Navarra, Navarra, Spain

### ARTICLE INFORMATION

#### Article history:

Received on 21 July, 2009

Accepted on 29 October, 2009

#### Keywords:

Adrenal tumor

Adrenal metastasis

Laparoscopic adrenalectomy

### ABSTRACT

**Objective:** To assess the peroperative and oncological results of laparoscopic adrenalectomy for an isolated metastasis.

**Material and methods:** A retrospective, descriptive study was conducted of 12 laparoscopic adrenalectomies performed for metastases out of a total of 40 adrenalectomies performed from May 1998 to April 2009. The primary tumor was pulmonary in 7 patients, renal in 3, and colonic in 2. Demographic data collected included median age, operating time, blood loss, complications, tumor size, and length of hospital stay. The Kaplan-Meier method was used to analyze survival.

**Results:** Operating time was 150 min (range, 90-206). Peroperative bleeding was 60 ml (range, 15-150). Peroperative complications occurred in 3% of patients. Tumor size was 4.5 cm (range, 1.3-8.5). No positive margins were seen in the resected specimens. Hospital stay was 3 days (range 3-5). Actuarial survival was 55.6% at 23 months (range, 2-38) with mean and median follow-up times of 20.9 and 23 months.

**Conclusions:** In selected patients, laparoscopic adrenalectomy for metastasis is a safe procedure with oncological results superimposable to those of open surgery.

© 2009 AEU. Published by Elsevier España, S.L. All rights reserved.

## Adrenalectomía laparoscópica por metástasis metácrona. Experiencia en 12 casos

### RESUMEN

#### Palabras clave:

Tumor adrenal

Metástasis adrenal

Adrenalectomía laparoscópica

**Objetivos:** evaluar los resultados perioperatorios y oncológicos de la adrenalectomía laparoscópica por metástasis aislada.

**Material y métodos:** estudio retrospectivo y descriptivo de 12 adrenalectomías laparoscópicas por metástasis de un total de 40 realizadas entre mayo de 1998 y abril de 2009. El tumor primario fue en siete casos de pulmón, en tres renal y en dos de colon. Los datos demográficos de la serie incluyeron edad, tiempo operatorio, sangrado, complicaciones, tamaño

\*Author for correspondence.

E-mail: ipascualp@unav.es (J. I. Pascual Piédrola).

tumoral y estancia hospitalaria expresados como mediana. El análisis de supervivencia se hizo con el método de Kaplan-Meier.

**Resultados:** el tiempo operatorio fue de 150 minutos (rango 90 a 206). El sangrado intraoperatorio fue de 60 cc (rango 15 a 150). Hubo complicaciones intraoperatorias en el 3% de los casos. El tamaño tumoral fue de 4,5 cm (rango 1,3 a 8,5). No se observaron márgenes positivos en las piezas de resección. La estancia hospitalaria fue de tres días (rango 3 a 5). La supervivencia actuarial fue del 55,6% a los 23 meses (rango 2 a 38), con una media y mediana de seguimiento de 20,9 y 23 meses, respectivamente.

**Conclusiones:** la adrenalectomía laparoscópica por metástasis en pacientes seleccionados es una técnica segura con resultados oncológicos superponibles a los de la cirugía abierta.

© 2009 AEU. Publicado por Elsevier España, S.L. Todos los derechos reservados.

## Introduction

The adrenal glands have a rich supply of fine blood vessels that that may promote the implantation and development of metastases. The tumors that most often metastasize to the adrenal gland are carcinomas of the lung, breast, colon, kidney, and melanoma, though there have been reports of metastasis of other origin, such as stomach and ovary<sup>1</sup>. The detection of solitary adrenal metastases discovered during the follow-up of cancer patients provides a greater chance of survival when compared to patients with synchronous metastasis<sup>2</sup>.

Since the description in 1992 of the laparoscopic approach to the adrenal gland, there has been constant controversy on the use of this type of procedure for the treatment of primary and metastatic malignant tumors of the adrenal gland, with series having been reported with long survival following laparoscopic adrenalectomy for cancer<sup>2,3</sup>.

The purpose of this study was to perform a retrospective and descriptive analysis of the perioperative and oncological results of laparoscopic adrenalectomy for a solitary metachronous metastasis.

## Materials and methods

A retrospective, descriptive study of 12 solitary adrenal metastases (mets) from a series of 40 laparoscopic adrenalectomies performed from May 1998 to April 2009. Solitary metastases were found in 10 patients, two of whom had bilateral mets, synchronous in one case and metachronous in the other. Met was on the left side in 7 patients and on the right in 5. The primary tumor was pulmonary in 7 patients, renal in 3, and colonic in 2. All patients were males, with a median age of 59.5 years (range: 49-70). Preoperative staging was performed in all cases by computed tomography (CT) and/or positron emission tomography (PET). Demographic data collected included median age, operating time, blood loss, complications, tumor size, and length of hospital stay.

Mandatory informed consent was obtained in all patients. Mechanical bowel preparation was performed from 24 hours before surgery that included a liquid diet and laxatives. Thromboembolic prophylaxis was administered with low

molecular weight heparin, cross-matched to reserve 2 units of compatible blood. On the same day, a broad-spectrum antibiotic (third-generation cephalosporin) was administered. Surgical details regarding patient placement, approach, number and position of trocars, and surgical technique had been previously described<sup>4</sup>.

## Statistical analysis

Statistical data are expressed as the mean and median. Actuarial survival was performed using the Kaplan-Meier method. Student's t test or the log-rank test was used for comparison of means, considering a p-value < 0.05 as statistically significant.

## Results

A total of 12 solitary adrenal mets were operated using the laparoscopic approach in 10 patients, of which one had synchronous bilateral disease and the other metachronous. Median operating time was 150 minutes (range: 90-206). Median blood loss was 60 mL (range: 15-50). There was one intraoperative complication from splenic capsular tear (3%), treated conservatively. Mean tumor size was 4.5 cm (range: 1.3-8.5). Pathological analysis revealed malignancy related to the primary tumor in all cases. No positive margins were seen in the resected specimens. Median hospital stay was three days (range: 3-5). Demographic, surgical and pathological characteristics of the series are detailed in Table 1.

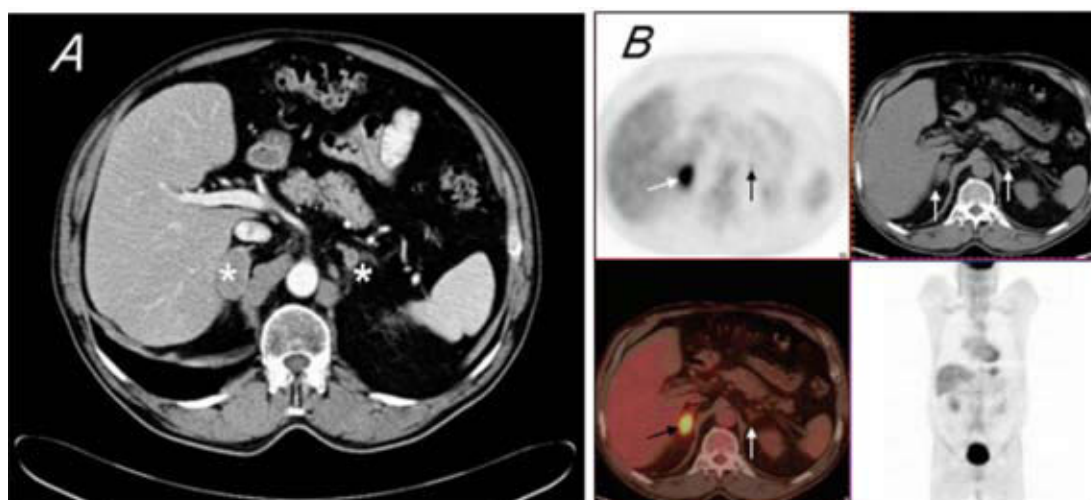
### Adrenal metastases of pulmonary origin

These were the largest group (n = 7; one patient with synchronous bilateral metastasis [Fig. 1]). The predominant cell pattern was classic large cell carcinoma, except in one patient (case 8), in whom a squamous pattern with severe cytoplasmic immune reactivity to cytokeratins predominated. In all cases, systemic chemotherapy regimens were instituted with various drugs and schemes, preferably cisplatin, carboplatin, taxotere, gemcitabine and paclitaxel, before or after treating the primary tumor.

**Table 1 – Demographic, surgical and pathological characteristics of the series**

Case no. (months)	Age	Sex	Side	Size (cm)	Pathological diagnosis	Outcome	Follow-up
1	59	Male	Left	3	Lung cancer metastasis	Dead. Progression	21
2	54	Male	Right	4.5	Renal cancer metastasis	Alive. No disease	38
3	70	Male	Left	3.5	Lung cancer metastasis	Dead. Progression	24
4	60	Male	Left	5	Poorly differentiated lung cancer metastasis	Dead. Progression	21
5*	65	Male	Right	6.8	Colon cancer metastasis	Alive. No disease	34
6**	67	Male	Bilateral	8.5/5	Poorly differentiated lung cancer metastasis	Dead. Progression	6
7	49	Male	Right	5	Lung cancer metastasis	Alive. With disease	32
8	70	Male	Left	4.5	Poorly differentiated squamous lung cancer metastasis	Alive. No disease	30
9*	65	Male	Left	1.3	Colon cancer metastasis	Alive. No disease	26
10	53	Male	Right	3.7	Renal cancer metastasis. Myelolipoma	Alive. No disease	3
11	57	Male	Left	1.5	Renal cancer metastasis	Alive. No disease	2

\*Metachronous metastasis of rectal cancer in the same patient, with a difference of 7 months; \*\*synchronous lung cancer metastasis in the same patient.



**Figure 1 – Synchronous bilateral adrenal metastasis of poorly differentiated lung carcinoma. A: Abdominal computed tomography (CT) showing the increase in both adrenal (asterisks). B: Positron emission tomography with 18FDG showing increased metabolism in both adrenal glands (arrows), consistent with metastasis.**

#### Adrenal metastases of renal origin

Of the three patients from the series, two had the shortest follow-up (three and two months, respectively), and one of them had an associated myelolipoma in pathological analysis of the resected specimen. Case 2, who had a met in the contralateral adrenal gland, had the longest follow-up, and is currently disease-free.

#### Adrenal metastases of intestinal origin

One patient (case 5 and 9) was diagnosed in June 2005 with rectal adenocarcinoma at 5 cm from the anal canal.

The patient was treated with a chemotherapy scheme of oxaliplatin, irinotecan and capecitabine, and 4 additional cycles of cytoreductive radiotherapy before abdominoperineal amputation and terminal colostomy performed in November 2005. In July 2006 and February 2007, laparoscopic adrenalectomy was performed for metachronous mets, followed by three cycles of gemcitabine, oxaliplatin and eritubux. The patient is currently disease-free.

#### Survival analysis

All patients in the series (n = 10) were followed up until the end of the observation period or death. Mean and median

follow-up times were 20.9 and 23 months. At the end of the study, 6 patients (60%) were alive, one of them with stabilized pulmonary disease. Actuarial survival for the overall group, estimated using the of Kaplan-Meier method, was 55.6% at two years. Survival, using the same statistical method, for patients diagnosed with pulmonary mets—the largest group in this series, with a mean and median follow-up of 21.8 and 21 months—was 33.3% at two years. Using Student's *t* test or the log-rank test for comparison of means, no statistically significant difference in survival was found in patients with mets of pulmonary origin compared with overall survival ( $p = 0.09$ ).

## Discussion

In this study we assessed perioperative and oncological results in a group of patients with metachronous adrenal metastases who were treated with laparoscopic adrenalectomy. The presence of adrenal met should be suspected in any patient with a previous history of cancer who has a adrenal tumor greater than 2 cm in diameter. When they are found, they are usually accompanied by multiple synchronous mets in other organs; the finding of a solitary adrenal met is less common<sup>5</sup>. The indication of laparoscopic surgery for a solitary adrenal met remains controversial, as is also the case for a suspected primary adrenal carcinoma. The criterion that should prevail in these cases, in addition to the experience of the surgeon in this type of procedure, is careful patient selection based on whether the tumor is confined to the gland in the imaging studies performed (CT, MRI) and whether the principles of oncologic surgery are followed<sup>2,3</sup>.

There are few series of laparoscopic adrenalectomies for cancer or met published in the literature with more than 10 cases<sup>1,3</sup>. In our study, all adrenalectomies were done for metachronous mets of the same tumor type previously diagnosed and treated. This circumstance of becoming evident an interval of time after initial presentation is less common than those found synchronously with the primary tumor<sup>5</sup>. Most adrenal mets have been traditionally detected in the large post-mortem series in patients with disseminated disease. Adrenal mets of pulmonary origin account for approximately 35.6% of the total, somewhat less than those of breast origin, which are the most common, and which are usually found during a radiological study in patients with known neoplastic disease, or more rarely as a sign of adrenal insufficiency due to unilateral or bilateral destruction of adrenal tissue<sup>6</sup>.

The incidence of adrenal met of renal origin in a recent series of 1,179 patients treated for renal carcinoma was 3.7%, 1.9% of which were ipsilateral, 1.5% contralateral, and 0.3% bilateral, synchronous with the primary tumor in 2.7% of patients and metachronous in 1%<sup>7</sup>. Adrenal mets of colorectal and other organ origins were reported with a much lower incidence in the series consulted<sup>1,2</sup>. In the present series, the proportion of mets over total adrenalectomies was 30%, a much higher figure than the average reported in other series where they accounted for less than 2% of the operated cases. This disproportion could be explained

by the fact that our center is a national reference center for oncological disease.

Tumor size is another factor that has been widely discussed when indicating a laparoscopic or open approach to the adrenal gland. In our series, the largest tumor diameter was 8.5 cm, which posed no problems during surgery, since the imaging studies conducted had ruled out local infiltration or of adjacent organs. A study comparing the role of laparoscopic adrenalectomy to open surgery in tumors less than or greater than 6 cm concluded that results are similar in the absence of local invasion<sup>8</sup>. Similarly, when a correct preoperative assessment is performed, the possibility of intraoperative complications decreases. In our study we had a low complications rate of 3% due to a splenic capsular tear treated conservatively. In other series consulted, the average complication rate ranged from 9% to 12.5% of patients<sup>1</sup>. During the follow-up of our series, we did not observe the presence of tumor implants in the peritoneal cavity or the port sites used for laparoscopic surgery, although in one case rupture of the endobag occurred at the time of collection of the surgical specimen.

The possibility of positive margins following laparoscopic adrenalectomy for suspected met is low, although special care should be taken during dissection, particularly when periadrenal fat tissue is very dense, ill-defined or adhered to nearby structures. Some authors advise against use of the harmonic scalpel for dissection of periadrenal tissue because of the possibility of causing tumor implants from viable neoplastic cells contained in the vapor generated by the scalpel. In our experience, using the harmonic scalpel routinely, we noted no presence of peritoneal or port site implants in this series. The percentage of positive margins ranges, depending on the authors, at around 9%<sup>3</sup>; this is a low figure, possibly resulting from previous selection in patients with suspected neoplastic disease. In our series, one patient had involvement of periadrenal fat tissue, although the final margins in pathological analysis were negative.

Timing of adrenal met appears to influence patient survival. A systematic review with a total of 114 patients on the outcomes of adrenalectomy for isolated synchronous versus metachronous adrenal mets in lung cancer observed that mean survival was shorter in patients with synchronous met than those with metachronous met (12 versus 31 months;  $p = 0.02$ ), although estimated survival at 5 years was equivalent with 26% and 25%, respectively<sup>9</sup>. The authors did not find conclusive factors for the better prognosis of metachronous mets, but postulated a possible relationship between morbidity and mortality associated with thoracotomy in synchronous mets and more aggressive biological behavior as factors influencing survival. In the case of metachronous met of renal carcinoma, disease-free survival increases significantly, depending on the series, to 87% after 39 months of follow-up<sup>10</sup>. In our experience, though it is a small series, metachronous adrenal mets of pulmonary origin did not show a statistically significant difference in survival compared with overall survival ( $p = 0.09$ ), but the limitation of the number of cases and follow-up of the patients should be taken into account.

---

## Conclusions

Laparoscopic adrenalectomy for met in adequately selected patients has been shown to be a safe and feasible technique. Our data show that the therapeutic and oncological results are superimposable to those of open surgery, with a survival for metachronous adrenal met at 3 years higher than 50%. Although the literature supports the surgical indication in patients with adrenal met, prospective studies are lacking to demonstrate that resection of a solitary adrenal met increases patient survival. Therefore, studies are needed including a greater number of patients and longer follow-up to confirm this possibility.

---

## Conflicts of interest

The authors declare no conflicts of interest.

---

## REFERENCES

1. Castillo OA, Vitagliano G, Kerkebe M, Parma P, Pinto I, Díaz M. Laparoscopic adrenalectomy for suspected metastasis of adrenal glands: Our experience. *Urology*. 2007;69:637-41.
2. Shen WT, Sturgeon C, Duh Q-Y. From incidentaloma to adrenocortical carcinoma: The surgical management of adrenal tumors. *J Surg Oncol*. 2005;89:186-92.
3. Moinzadeh A, Gill IS. Laparoscopic radical adrenalectomy for malignancy in 31 patients. *J Urol*. 2005;173:519-25.
4. Pascual JI, Cuesta JA, Grasa V, Labairu L, Napal S, Ipiens A. Adrenalectomía laparoscópica. Consideraciones a propósito de 24 procedimientos. *Actas Urol Esp*. 2007;31:98-105.
5. Suzuki H. Laparoscopic adrenalectomy for adrenal carcinoma and metastases. *Curr Opin Urol*. 2006;16:47-53.
6. San Miguel Fraile P, Tardáguila Montero F, Ortiz Rey JA, Antón Badiola I, Zungri Telo E, De la Fuente Buceta A. Metástasis adrenal bilateral como primera manifestación clínica de un carcinoma pulmonar: presentación de un caso y revisión de la literatura. *Actas Urol Esp*. 2002;26:124-8.
7. Antonelli A, Cozzoli A, Simeone C, Zani D, Zanotelli T, Portesi E, et al. Surgical treatment of adrenal metastasis from renal cell carcinoma: a single-centre experience of 45 patients. *BJU Int*. 2006;97:505-8.
8. Parnaby CN, Chong PS, Chisholm L, Farrow J, Connell JM, O'Dwyer PJ. The role of laparoscopic adrenalectomy for adrenal tumours of 6 cm or greater. *Surg Endosc*. 2008;22:617-21.
9. Tanvetyanon T, Robinson LA, Schell MJ, Strong VE, Kapoor R, Coit DG. Outcomes of adrenalectomy for isolated synchronous versus metachronous adrenal metastases in non-small-cell lung cancer: a systematic review and pooled analysis. *J Clin Oncol*. 2008;26:1142-7.
10. Bonnet S, Gaujoux S, Leconte M, Thillois JM, Tissier F, Dousset B. Laparoscopic adrenalectomy for metachronous metastasis from renal cell carcinoma. *World J Surg*. 2008;32:1809-14.