

Image of the month

A rare cause of acute abdominal pain: Perforation of a hepatic hydatid cyst into the peritoneum



Una causa poco común de dolor abdominal agudo: perforación del quiste hidatídico hepático hacia el peritoneo

Gökhan Tonkaz^{a,*}, Cemre Akdeniz^a, Mehmet Tonkaz^a,
Duygu Erkal Tonkaz^b, Serdar Aslan^a

^aDepartment of Radiology, Faculty of Medicine, Giresun University, Giresun, Turkey

^bDepartment of Radiology, Gumushane State Hospital, Gumushane, Turkey

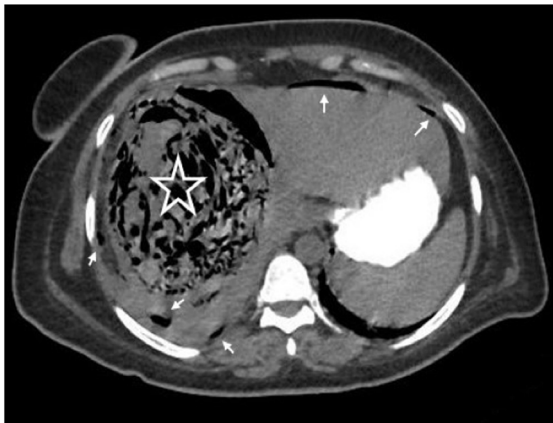


Fig. 1

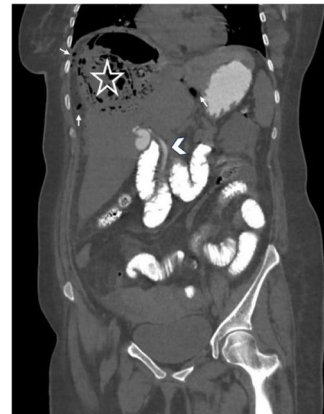

Fig. 2

A 37-year-old female patient was admitted to the emergency department with sudden-onset abdominal pain. On oral contrast-enhanced CT imaging, free air values were observed in the intraperitoneal area (Figs. 1 and 2, arrows) and within the cyst in the liver (Figs. 1 and 2, star). Furthermore, leakage of the administered oral contrast substance into the common bile duct was noted (Fig. 2, arrowhead). Radiological findings indicated intraperitoneal perforation of a hydatid cyst that had opened into the bile ducts. The patient underwent emergency surgery, and the diagnosis was confirmed. Hepatic hydatid cyst perforation may cause anaphylactic reaction, cholangitis or sepsis. Rapid diagnosis is vital in such patients, and CT is an essential tool.

Conflict of interest

The authors declare that they have no conflict of interest to the publication of this article.

* Corresponding author.

E-mail address: gokhantonkaz@gmail.com (G. Tonkaz).

<https://doi.org/10.1016/j.ciresp.2024.02.008>

0009-739X/© 2024 AEC. Published by Elsevier España, S.L.U. All rights reserved.