



CIRUGÍA ESPAÑOLA


www.elsevier.es/cirugia


Image of the month

Duplication of the transverse colon: A rare cause of abdominal pain in an adult male[☆]



Duplicación de colon transverso: Causa rara de dolor abdominal en el adulto

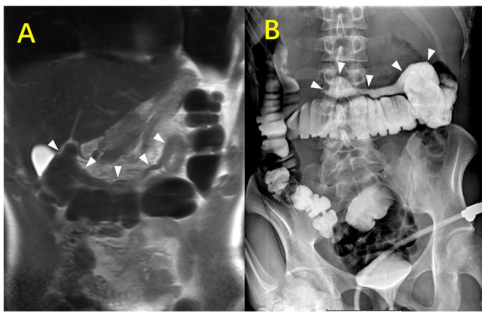
Chendong He^a, Wei Yang^{b,*}^a Department of Radiology, the first affiliated hospital of Bengbu medical college, Bengbu 233004, Anhui, China^b Department of Radiology, Jiangsu Province Hospital of Chinese Medicine & Affiliated Hospital of Nanjing University of Chinese Medicine, 155 Hanzhong Road, Qinhuai District, Nanjing 210029, Jiangsu, China

Fig. 1

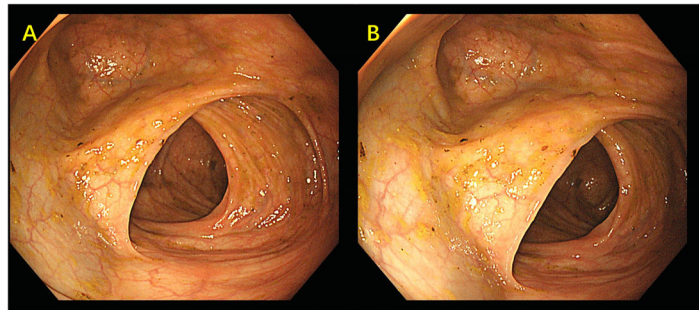


Fig. 2

A 30-year-old male patient presented with dull upper abdominal pain that he had been experiencing for one month. Abdominal magnetic resonance (Fig. 1A), barium enema (Fig. 1B) and colonoscopy (Fig. 2A&B) revealed a tubular structure connected to the transverse colon. The pathology results after partial transverse colectomy demonstrated intestinal duplication with chronic inflammation.

Intestinal duplication is a rare congenital disorder, and the ileum is the most common site. Few patients remain asymptomatic until adulthood, and most are diagnosed before the age of 2. Intestinal duplication is often misdiagnosed as an acute abdomen due to other causes. Surgical resection of the affected bowel segment is the treatment of choice.

Statement

All authors agree with the content of the manuscript. The content has not been published or submitted for publication elsewhere.

[☆] Please cite this article as: He C, Yang W. La duplicación del colon transverses una causa rara de dolor abdominal en un hombre. Cir Esp. 2023.

* Corresponding author.

E-mail address: youngwei0713@163.com (W. Yang).

<https://doi.org/10.1016/j.ciresp.2023.07.011>

0009-739X/© 2024 AEC. Published by Elsevier España, S.L.U. All rights reserved.

Ethics committee approval

N/A.

Funding

None.

Patient consent for publication

Written informed consent was obtained from the patient.

Conflict of interest

Nothing to declare.