

Patient 3 was a 66-year-old woman with lupus erythematosus and normal echocardiogram prior to initiating therapy who developed dilated cardiomyopathy after 25 months of treatment. The patient presented with exercise-induced dyspnea. Magnetic resonance imaging showed left ventricular dilatation with a slightly depressed ejection fraction, normal wall thickness, and no focal or segmental fibrosis in the late enhancement sequences. The drug was withdrawn and ventricular volumes returned to normal during subsequent follow-up. Hydroxychloroquine-induced cardiomyopathy was therefore suspected clinically. Endomyocardial biopsy was not performed.

These 3 cases of hydroxychloroquine-induced myocardial toxicity highlight the importance of periodic clinical assessment of these patients (even those who have been under treatment for a few months). In the event of minimal clinical suspicion, the use of imaging techniques should be considered to assess whether myocardial involvement is present.

#### Acknowledgments

We would like to thank Dr Nuria Padullés Zamora, hospital pharmacist, for her collaboration.

Francisco Di Girolamo,<sup>a</sup> Eduard Claver,<sup>a,\*</sup> Montse Olivé,<sup>b</sup> Joel Salazar-Mendiguchía,<sup>a</sup> Nicolás Manito,<sup>a</sup> and Ángel Cequier<sup>a</sup>

<sup>a</sup>Àrea de Malalties del Cor, IDIBELL, Hospital de Bellvitge, L'Hospitalet de Llobregat, Barcelona, Spain

<sup>b</sup>Servicio de Anatomía Patológica (Neuropatología) y Unidad de

Patología Neuromuscular, IDIBELL, Hospital de Bellvitge, L'Hospitalet de Llobregat, Barcelona, Spain

\* Corresponding author:

E-mail address: [eclaver@bellvitgehospital.cat](mailto:eclaver@bellvitgehospital.cat) (E. Claver).

Available online 18 May 2017

#### REFERENCES

1. Rainsford KD, Parke AL, Clifford-Rashotte M, Kean WF. Therapy and pharmacological properties of hydroxychloroquine and chloroquine in treatment of systemic lupus erythematosus, rheumatoid arthritis and related diseases. *Inflammopharmacology*. 2015;23:231–269.
2. Marmor MF, Kellner U, Lai TY, Lyons JS, Mieler WF. Revised recommendations on screening for chloroquine and hydroxychloroquine retinopathy. *Ophthalmology*. 2011;118:415–422.
3. Roos JM, Aubry MC, Edwards WD. Chloroquine cardiotoxicity: clinicopathologic features in three patients and comparison with three patients with Fabry disease. *Cardiovasc Pathol*. 2002;11:277–283.
4. Capel RA, Herring N, Kalla M, et al. Hydroxychloroquine reduces heart rate by modulating the hyperpolarization-activated current I<sub>f</sub>: Novel electrophysiological insights and therapeutic potential. *Heart Rhythm*. 2015;12:2186–2194.

<http://dx.doi.org/10.1016/j.rec.2017.04.017>  
1885-5857/

© 2017 Sociedad Española de Cardiología. Published by Elsevier España, S.L.U. All rights reserved.

### Percutaneous Ventricular Assist Device for Circulatory Support During Ablation of Atrial Tachycardias in Patients With Fontan Circulation



#### SopORTE circulatorio mediante asistencia ventricular percutánea durante la ablación de taquicardias auriculares en pacientes con circulación de Fontan

#### To the Editor,

In this article, we describe 2 patients with Fontan circulation who underwent successful ablation of a hemodynamically unstable atrial arrhythmia with the aid of a continuous flow percutaneous ventricular assist device (VAD).

A 34-year-old man was referred to our clinic for an ablation for symptomatic, frequently-recurring intra-atrial reentrant tachycardia (IART). He was diagnosed with tricuspid atresia and atrial and ventricular septal defect. At the age of 8 years, a Fontan circulation had been created and resulted in a pulmonary homograft between the right atrium and a hypoplastic right ventricle (Björk modification). Preprocedure examination revealed moderately reduced left ventricular function and a mildly stenosed homograft. The first ablation procedure was discontinued due to hemodynamic instability. During the repeat procedure, we decided to use hemodynamic support through a percutaneous VAD (Impella 3.5 CP catheter, Abiomed Inc, Danvers, MA, United States), which was placed via the right femoral artery in a retrograde approach across the aortic valve in the left ventricle (Figure 1A). A dense bipolar voltage map (Figure 1B) of the right atrium identified scarring in multiple locations. An IART was induced and ablation was performed during tachycardia. During ablation on the lateral wall, the tachycardia terminated. However, multiple different IARTs could be reinduced. After ablation of all

channels in the scar, no IART could be induced at the end of the procedure.

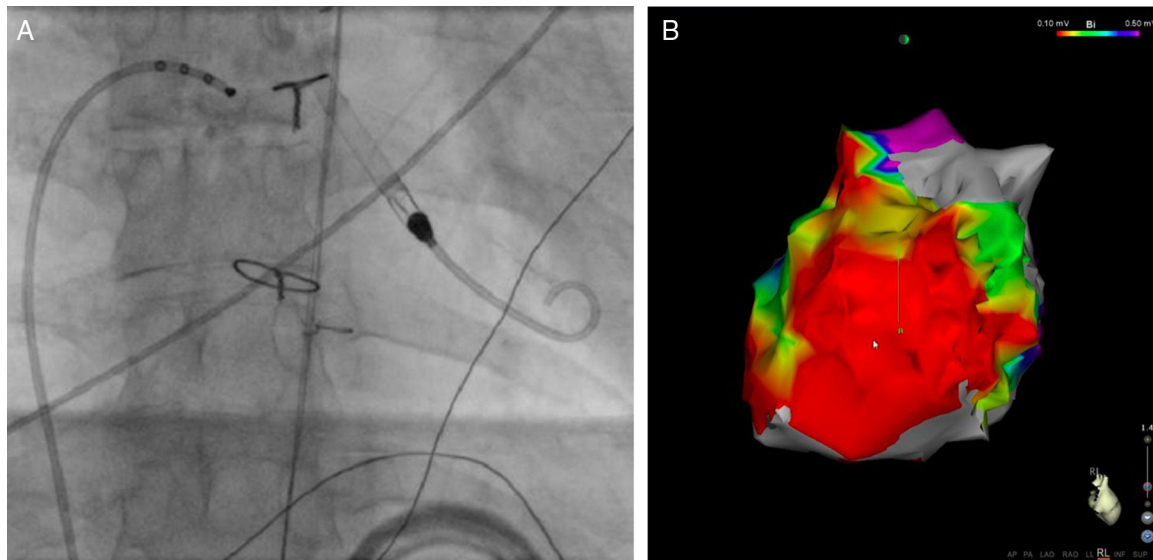
Initially, during atrial tachycardias, the patient was hemodynamically unstable. With a continuous blood flow of 2.7 L per minute, the tachycardias were tolerated, but only after correction of the preload. There have been no recurrences during a 30-month follow-up.

A 21-year-old man born with tricuspid valve atresia underwent a bidirectional Glenn anastomosis at 9 months. Completion of the Fontan circulation followed at the age of 2 when the right atrium was connected to the pulmonary artery.

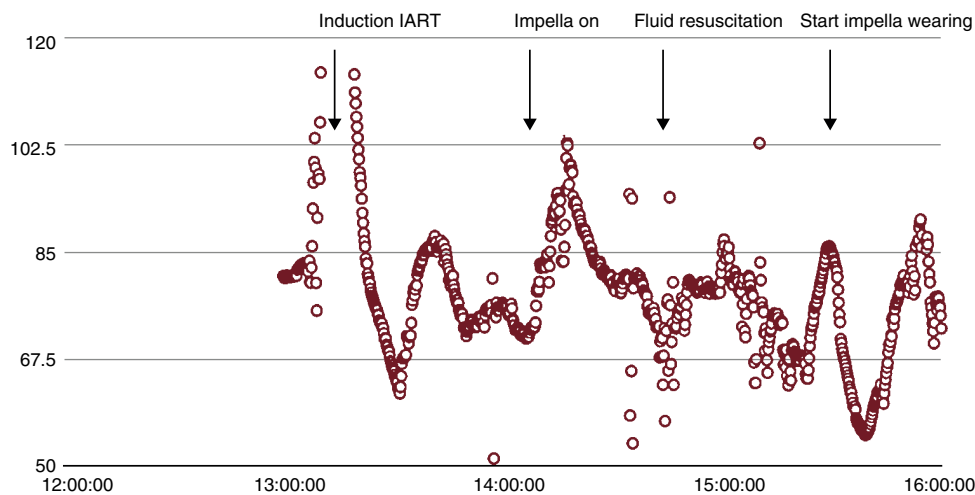
The patient was referred for catheter ablation because of multiple episodes of drug-resistant IART. The patient had deteriorated left ventricular function and subsequently overt congested heart failure. Because he was hemodynamically unstable during his tachycardias, we used hemodynamic support with an Impella 3.5 CP catheter (Abiomed Inc, Danvers, MA, United States) that was placed via the left femoral artery.

Bipolar voltage mapping illustrated an area of low voltage on the lateral wall of the right atrium, most probably the result of the atriotomy. Entrainment mapping suggested that the area of low voltage on the lateral right atrial wall was part of the induced IART circuit. Consequently, an ablation line in the target area led to termination of the IART. With the use of the percutaneous VAD and preload correction by administering 1.5 L lactated ringer's solution to obtain a left ventricular end diastolic pressure of more than 12 mmHg, the patient maintained stable hemodynamics (Figure 2) and a urine production of > 200 mL per hour.

The patient continued to receive sotalolol twice daily and experienced a single episode of atrial tachycardia in the subsequent year. In addition, his ventricular function improved, symptoms of heart failure ceased, and his functional class remained stable.



**Figure 1.** Radiographic image during the procedure (A), bipolar voltage map (B), case 1. A: a percutaneous ventricular assist device is placed via the right femoral artery in a retrograde approach across the aortic valve in the left ventricle. B: bipolar voltage map showing extensive scarring in the right atrium (right lateral view).



**Figure 2.** Mean arterial pressure during ablation, case 2. X-axis time in hours, Y-axis blood pressure in mmHg. During ablation the tachycardias were well tolerated under Impella support, but only after correction of the preload. IART, intra-atrial reentrant tachycardia.

To the best of our knowledge, this is the first report illustrating percutaneous circulatory left ventricle support as a human implant during complex atrial arrhythmia ablation in single-ventricle physiology.

Despite extended periods of hemodynamic instability during ablation, end-organ perfusion can be safely maintained by using circulatory support devices such as continuous flow percutaneous VAD. Hemodynamic support in VT ablation is widely accepted<sup>1</sup> but is uncommon during ablation of atrial arrhythmias. Instability during ablation may vary according to the type of arrhythmia and underlying structural morphology.

In both single-ventricle patients, with the use of percutaneous VAD, resulting in a blood flow of 2.7 L/min and 3.5 L/min, respectively, stable blood pressure and cardiac output was maintained. This allowed for extensive mapping and ablation<sup>2</sup> during prolonged periods of atrial arrhythmia without the development of hemodynamic compromise, as experienced by 1 of our patients in a previous ablation attempt.

Arrhythmias are a well-known long-term complication of the surgical repair of congenital heart defects, such as the Fontan operation.<sup>3</sup> The pathophysiology is a complex interplay between cardiac anatomy, chamber enlargement due to abnormal pressure and volume loads, cellular injury from cardiopulmonary bypass, and fibrosis at sites of suture lines and patches.<sup>4</sup> Cardiac failure due to loss of sinus rhythm was already recognized by Fontan in his first report.<sup>5</sup>

In conclusion, in single-ventricle patients with a Fontan-type repair, the use of percutaneous VAD combined with adequate preload results in stable cardiac output, facilitating mapping and ablation of atrial arrhythmias.

Astrid Hendriks,<sup>a</sup> Lennart De Vries,<sup>a</sup> Maarten Witsenburg,<sup>b</sup> Sing-Chien Yap,<sup>a</sup> Nicolas Van Mieghem,<sup>c</sup> and Tamas Szili-Torok<sup>a,\*</sup>

<sup>a</sup>Department of Clinical Electrophysiology, Erasmus Medical Center, Rotterdam, The Netherlands

<sup>b</sup>Department of Cardiology, Congenital Heart Disease, Erasmus Medical Center, Rotterdam, The Netherlands

<sup>c</sup>Department of Interventional Cardiology, Erasmus Medical Center, Rotterdam, The Netherlands

\* Corresponding author:

E-mail address: [t.szilitorok@erasmusmc.nl](mailto:t.szilitorok@erasmusmc.nl) (T. Szili-Torok).

Available online 18 April 2017

## REFERENCES

1. Cesario DA, Saxon LA, Cao MK, Bowdish M, Cunningham M. Ventricular tachycardia in the era of ventricular assist devices. *J Cardiovasc Electrophysiol*. 2011;22:359–363.

2. Miller M, Dukkipati S, Chinitz J, et al. Activation and Entrainment Mapping of Hemodynamically Unstable Ventricular Tachycardia Using a Percutaneous Left Ventricular Assist Device. *J Am Coll Cardiol*. 2011;58:1363–1371.
3. Triedman JK. Arrhythmia management of patients with Fontan physiology. *Pediatric Cardiol*. 2002;16:69–77.
4. Abrams D, Schilling R. Mechanism and mapping of atrial arrhythmia in the modified Fontan circulation. *Heart Rhythm*. 2005;2:1138–1144.
5. Fontan F, Baudet E. Surgical repair of tricuspid atresia. *Thorax*. 1971;26:240–248.

<http://dx.doi.org/10.1016/j.rec.2017.03.010>  
1885-5857/

© 2017 Sociedad Española de Cardiología. Published by Elsevier España, S.L.U. All rights reserved.

## Survivor of a Double Mechanical Complication After Myocardial Infarction: Papillary Muscle Rupture and Contained Free-wall Rupture

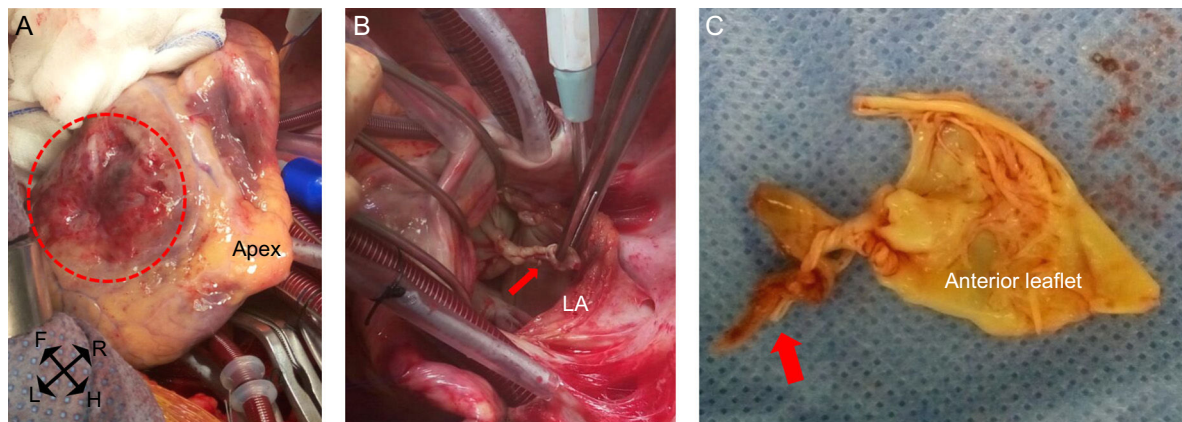


### Superviviente a doble complicación mecánica tras el infarto: rotura del músculo papilar posteromedial y rotura contenida de pared libre

To the Editor,

We present the case of a 75-year-old man, referred to our hospital in a state of cardiogenic shock, with a diagnosis of free mitral regurgitation following myocardial infarction. The patient attended the first hospital with a 3-week history of chest pain. In the emergency department, he was diagnosed with evolving inferoposterior myocardial infarction, with Q waves and new-onset inverted T waves on electrocardiogram and mildly elevated markers of myocardial damage. He was admitted to the intensive care unit (ICU) for treatment and underwent coronary angiography, which showed a 60% lesion at the right coronary artery (RCA) ostium and chronic distal disease in the presence of right dominance; therefore, it was decided to treat medically. During his stay in the ICU, he remained asymptomatic, so was discharged to the ward. After 2 days on the ward, the patient deteriorated, with hemodynamic compromise and acute pulmonary edema. Transthoracic echocardiography was performed, which showed free mitral regurgitation secondary to posteromedial papillary muscle (PM) rupture, with no other significant findings. In the

absence of a cardiac surgery team in the hospital, it was decided to perform emergency simple angioplasty of the RCA, and subsequently the patient was sent to a center with cardiac surgery facilities. On arrival, the patient required vasoactive support and intra-aortic balloon counterpulsation; therefore, emergency intervention was performed. The estimated surgical risk was 30.15% (logistic EuroSCORE). The inferior wall was examined via midline sternotomy and with conventional extracorporeal circulation, and a large infarcted area with friable tissue was observed (Figure 1A). Left atrial atriotomy was performed, which allowed the posteromedial PM rupture to be visualized (Figure 1B). The anterior leaflet of the mitral valve was resected, along with part of the muscle anchored to the primary chordae (Figure 1C). The valve was replaced with a 27-mm Carpentier Magna Ease (Edwards) biological mitral prosthesis and the inferior wall was revascularized with a saphenous vein graft to the posterolateral branch of the RCA. The surgery was uneventful, but the patient remained in the ICU for 2 weeks due to a tracheobronchitis that required prolonged intubation and antibiotics. After this resolved, the patient progressed well and was discharged home at 1 month after surgery. On postoperative transthoracic echocardiography, a 2.8 × 1 cm cavity was noted in the midregion of the inferior wall, with a 1.5-cm inlet and a gap in the ventricular wall with flow into the interior (Figures 2A and 2B), compatible with a pseudoaneurysm/contained free-wall rupture (FWR) following infarction. This finding was confirmed with computed tomography, which showed the close relationship to the artery that had caused the infarction



**Figure 1.** Intraoperative images. A: Arrested and emptied heart positioned for revascularization of the posterolateral artery. The infarcted area of the inferior wall can be seen (dashed circle). B: After left atriotomy was performed, the complete rupture of the posteromedial PM could be seen; the forceps are holding the head of the PM (arrow). C: Surgical specimen of the anterior leaflet of the mitral valve with the chordae tendineae anchored to the ruptured head of the PM (arrow). F, feet; H, head; L, left; LA, left atrium; PM, papillary muscle; R, right.