

ECG Contest

ECG, April 2017

ECG de abril de 2017



César Rainer Solórzano Guillén and Rafael Peinado Peinado*

Unidad de Arritmias, Servicio de Cardiología, Hospital Universitario La Paz, Madrid, Spain

A 62-year-old man presented to the emergency room with palpitations and dyspnea. The patient had a history of kidney disease and bicuspid aortic valve disease, with class III/IV heart failure and left ventricular dilatation and dysfunction (ejection fraction, 40%) but no history of palpitations, dizziness, or syncope. Physical examination on admission revealed blood pressure of 130/80 mmHg and no overt signs of heart failure. The admission ECG showed regular, wide-QRS tachycardia (Figure 1). Sinus rhythm was restored with electrical cardioversion (Figure 2).

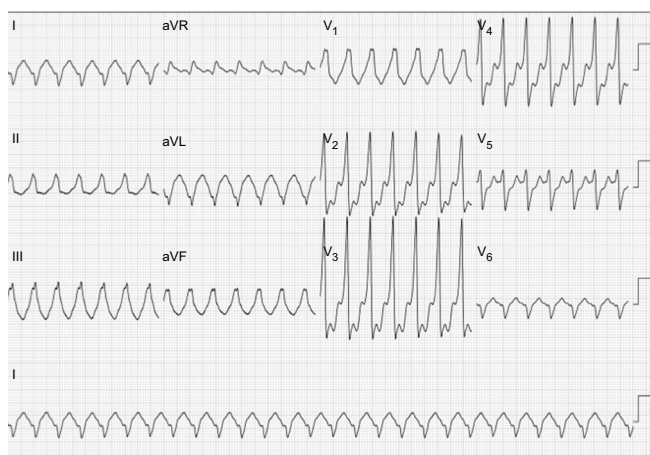


Figure 1.

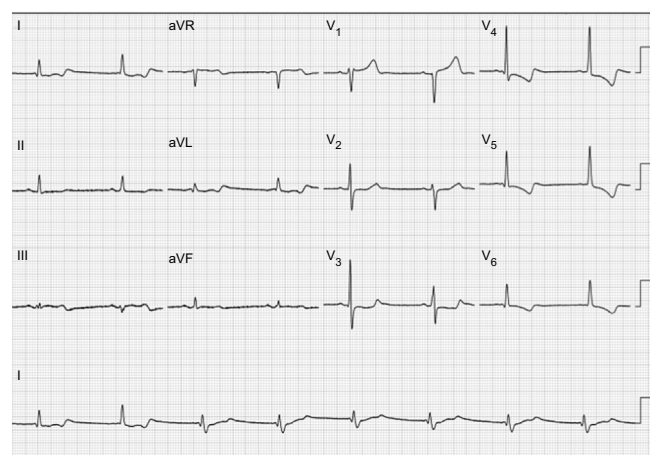


Figure 2.

What is the most mechanism in this patient?

1. Monomorphic ventricular tachycardia due to myocardial reentry.
2. Monomorphic ventricular tachycardia due to bundle branch reentry.
3. Nodal reentrant tachycardia with right bundle branch block.
4. Preexcited tachycardia.

Suggest a solution to this ECG Contest at <http://www.revespcardiol.org/es/electroreto/70/4>. The answer will be published in the next issue (May 2017). #RetoECG.

* Corresponding author:

E-mail address: rpeinado@secardiologia.es (R. Peinado Peinado).