

ECG Contest

ECG, September 2014



ECG de septiembre de 2014

Adolfo Fontenla

Unidad de Arritmias, Servicio de Cardiología, Hospital Universitario 12 de Octubre, Madrid, Spain

A 24-year-old man was referred for study. He had experienced syncope twice after getting up at night, during voiding. He had no medical history of interest. His mother had been diagnosed with vasovagal syncope, but there was no history of sudden death in the family. The physical examination and transthoracic echocardiography findings were normal. A baseline electrocardiogram was recorded (Figure 1). The abnormalities observed prompted an intravenous drug challenge with flecainide (Figure 2). What would your diagnosis be?

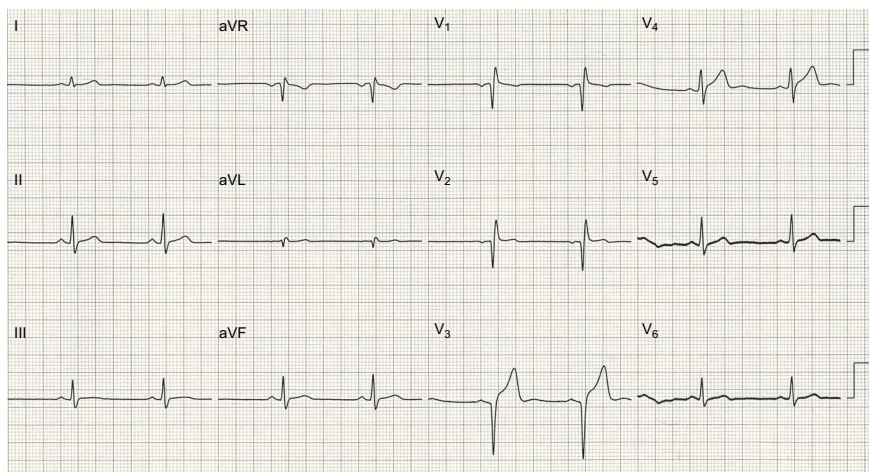


Figure 1.

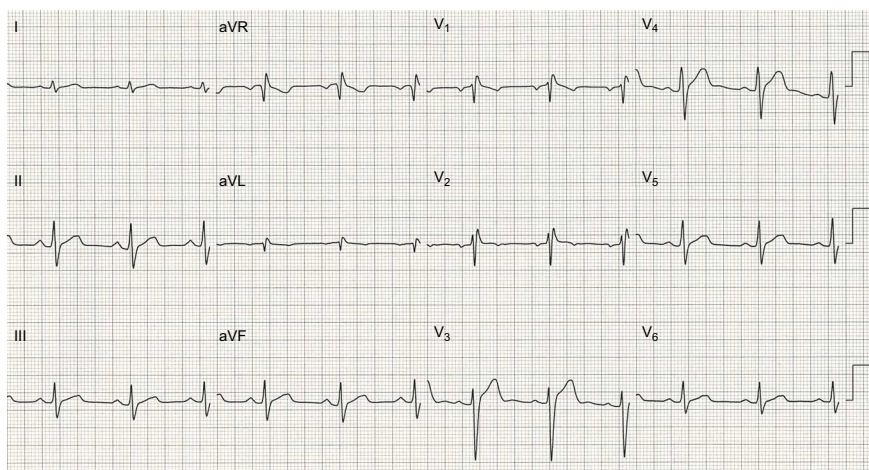


Figure 2.

Suggest a solution to this ECG Contest at <http://www.revespcardiol.org/es/electroreto/67/09> (only Spanish) #ECGSEP14. The answer will be published in the next issue (October 2014).

E-mail address: drfontenla@gmail.com

<http://dx.doi.org/10.1016/j.rec.2014.05.006>

1885-5857/© 2014 Sociedad Española de Cardiología. Published by Elsevier España, S.L.U. All rights reserved.