

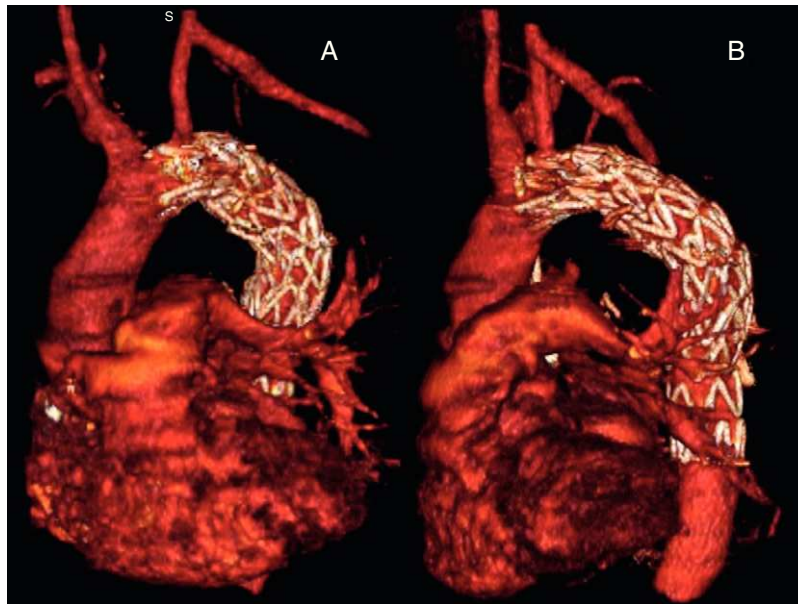Figure 2. Postoperative images. Note the left carotid-subclavian bypass. A: frontal view. B: lateral view.

involves the endovascular approach.⁴⁻⁶ However, the indication for long-term antibiotic therapy remains a subject of controversy.⁶ The use of these endovascular techniques has enabled surgeons to achieve a success rate of over 90%, with excellent medium-term results, considerably reducing the rates of morbidity and mortality associated with conventional surgery (from 15-41% to 6.6%).⁶

In short, endovascular treatment is a safe therapeutic alternative for the repair of an ABF, although long-term follow-up is necessary.

Without treatment, this condition is associated with a mortality rate of 100% and, thus, clinical suspicion is essential for immediate action to be undertaken. In our case, the time elapsed between surgery and the development of the ABF was 27 years, making this the case with the latest onset reported in the literature.

Emiliano A. Rodríguez-Caulo,* Carlos J. Velázquez,
José Miguel Barquero, and Mariano García-Borbolla

Servicio de Cirugía Cardiovascular, Hospital Universitario Virgen Macarena, Sevilla, Spain

* Corresponding author:

E-mail address: erodriguezcaulo@hotmail.com
(E.A. Rodríguez-Caulo).

Available online 13 April 2011

REFERENCES

1. Piciche M, De Paulis R, Fabbri A, Chiariello L. Postoperative aortic fistulas into the airways: etiology, pathogenesis, presentation, and management. *Ann Thorac Surg.* 2003;75:1998-2006.
2. Pirelli S, Bozzani A, Arici V, Odero A. Endovascular treatment of acute haemoptysis secondary to aortobronchial fistula. *Eur J Vasc Endovasc Surg.* 2006;32:366-8.
3. Von Kodolitsch Y, Aydin M, Koschyk D. Predictors of aneurysmal formation after surgical correction of aortic coarctation. *J Am Coll Cardiol.* 2002;39:617-24.
4. Thompson C, Ramaiah V, Rodríguez-López J, Vranic M, Ravi R. Endoluminal stent graft repair of aortobronchial fistulas. *J Vasc Surg.* 2002;35:387-91.
5. Quintana AL, Aguilar-Martínez E, Heredero-Fernández A, Riambau V, Paul L, Acín F. Aortobronchial fistula after aortic coarctation. *J Thoracic Cardiovasc Surg.* 2006;131:240-3.
6. Bockler D, Schumacher H, Schwarzbach M, Ockert S, Rotert H, Allenberg JR. Endoluminal stent-graft repair of aortobronchial fistulas: bridging or definitive long term solution? *J Endovasc Ther.* 2004;11:41-8.

doi:10.1016/j.rec.2010.11.013

Chiari's Network and Paroxysmal Atrial Fibrillation

Red de Chiari y fibrilación auricular paroxística

To the Editor,

An 11-year-old boy was admitted to the Emergency Room referring sudden episodes of palpitations followed by syncope; he has no past medical history. Blood tests including thyroid function were normal. Electrocardiogram (ECG) showed an atrial fibrillation with ventricular response at 180 bpm. No structural or functional pathology was established, and different antiarrhythmic drug

strategies were tried, but episodes continued to occur. Echo scan (Fig. 1) showed a strongly developed Chiari's network on his right atrium, with no atrial septal defect. Because of its size, we observed a continuous violent flicking against lateral wall of the atrium. No abnormality other than the presence of Chiari's network could explain these episodes despite an exhaustive electrophysiology study, which induced no arrhythmias.

After various antiarrhythmia treatments had no effect, he underwent surgical excision of Chiari's network (Fig. 2) through a simple thoracotomy, with no surgical complications.

To our knowledge, this is the first description of paroxysmal atrial fibrillation triggered by Chiari's network. It has been reported to appear in up to 4% of autopsy studies,^{1,2} and is frequently

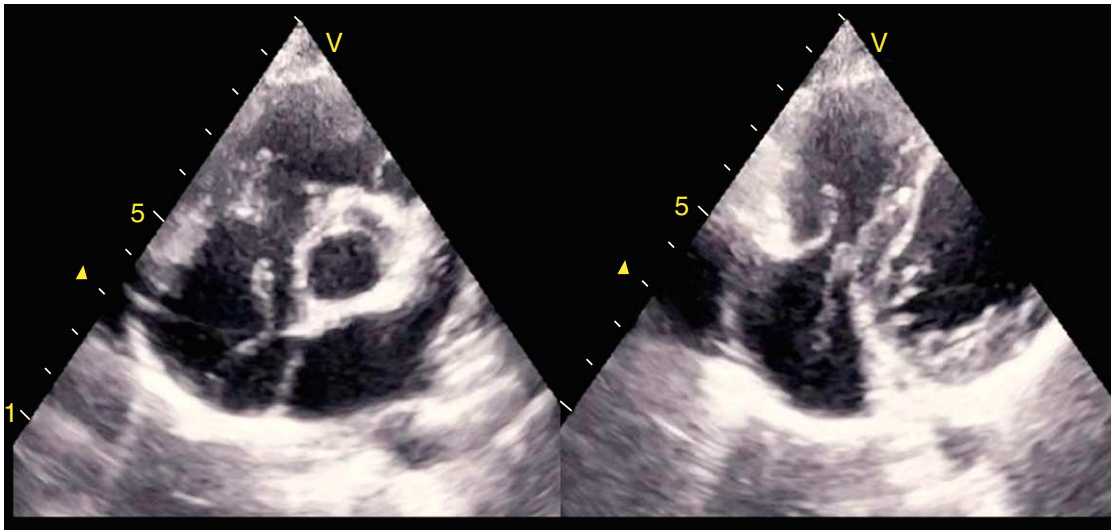


Figure 1. 2D-echocardiogram image showing Chiari's network in right atrium moving towards tricuspid valve.

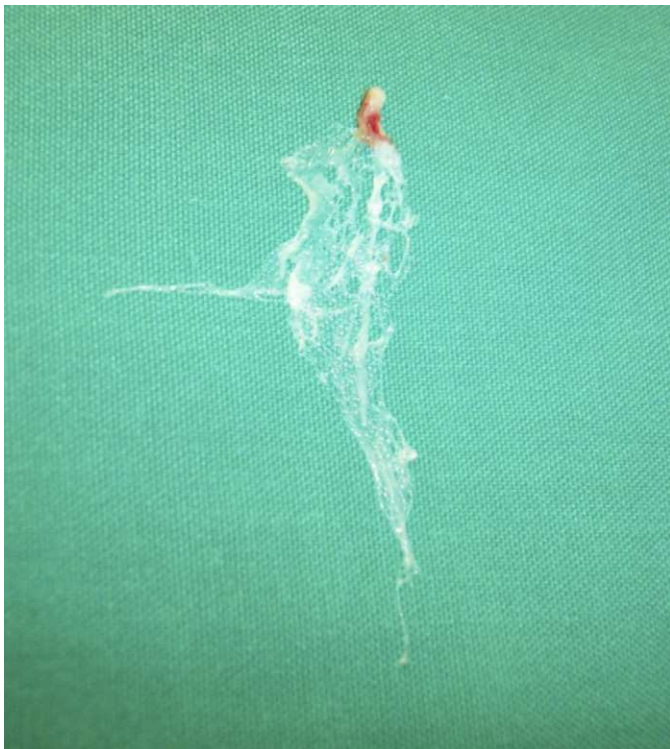


Figure 2. Surgical sample of a highly developed Chiari's network removed from right atrium.

associated with patent foramen ovale but is believed to be of little clinical consequence.³⁻⁵ Nevertheless, recent studies suggest some clinical role in some cases of thrombosis, causing embolic events.⁶⁻¹⁰

The surgical excision has been effective to date. No recurrence of arrhythmia or syncope has been detected after 4 years of follow-up and Holter ECG, the boy's development has been completely normal and he regularly engages in intense physical exercise.

Eduardo Alegría-Barrero,^{a,*} Ana Alegría-Barrero,^b
Juan José Gavira Gómez,^b and Gregorio Rábago Juan-Aracil^b

^aInstituto Cardiológico, Clínica Rotger, Palma de Mallorca, Baleares, Spain

^bDepartamento de Cardiología y Cirugía Cardiovascular, Clínica Universidad de Navarra, Pamplona, Navarra, Spain

*Corresponding author: Instituto Cardiológico, Clínica Rotger, Santiago Russiñol 9, 07012 Palma de Mallorca, Baleares, Spain.

E-mail address: ealegriabarrero@secardiologia.es

(E. Alegría-Barrero).

Available online 17 April 2011

REFERENCES

- Clements J, Sobotka-Plojhar M, Exlato N, Van Geijn HP. A connective tissue membrane in the right atrium (Chiari network) as a cause of fetal cardiac arrhythmia. *J Obstet Gynecol.* 1982;142:709-12.
- Pellet AA, Kerut EK. The Chiari network in an echocardiography study. *J Cardiovasc Ultrasound.* 2004;21:91-3.
- Chiari H. Über netzbildungen im rechten vorhofe des herzens. *Beitr Path Anat.* 1897;22:1-10.
- Helwig FC. The frequency of anomalous reticula in the right atrium of the human heart "Chiari network". Report of eight cases. *Am J Pathol.* 193;8:73-9.
- Schneider B, Hofmann T, Justen M, Meinertz T. Chiari's network: normal anatomic variant or risk factor for arterial embolic events? *J Am Coll Cardiol.* 1995;26:203-10.
- Pearson AC, Nagelhout D, Castello R, Gomez CR, Labovitz AJ. Atrial septal aneurysm and stroke: a transesophageal echocardiographic study. *J Am Coll Cardiol.* 1991;18:1223-9.
- Schuchlenz HW, Saurer G, Weihs W, Rehak P. Persisting Eustachian valve in adults: relation to patent foramen ovale and cerebrovascular events. *J Am Soc Echocardiogr.* 2004;17:231-3.
- Yamashita T, Ohkawa S, Imai T, Ide H, Watanabe C, Ueda K. Prevalence and clinical significance of anomalous muscular band in the left atrium. *Am J Cardiovasc Pathol.* 1993;4:286-93.
- Benbow E, Love E, Love H. Massive right atrial thrombus associated with a Chiari network and a Hickman catheter. *Am J Clin Pathol.* 1987;88:243-8.
- Maruyama T, Kurogouchi F. Entrapment of a tined lead by the Chiari network with preserved atrial sensing ability in a patient with atrioventricular block: a case report. *J Cardiol.* 2004;44:251-4.

doi:10.1016/j.rec.2010.11.003