

Transdermal nitroglycerin versus corticosteroid infiltration for rotator cuff tendinitis

S. Pons, C. Gallardo, J.C. Caballero and T. Martínez

Aims. To compare transdermal nitroglycerin (NTG) and corticosteroid infiltration in patients with rotator cuff tendinitis (RCT).

Design. Experimental, randomized controlled study.

Setting. Semirural basic health area in the Garraf region of Barcelona province, Spain, with a population of public health service users of 12000.

Patients and methods. Patients diagnosed as having RCT of less than 6 weeks' evolution who had not responded to treatment with oral nonsteroid antiinflammatory drugs. The patients were distributed randomly into two groups: *a*) group A, local infiltration via a posterior approach with a depot corticosteroid and local anesthesia, and *b*) group B, treated for 3 days with a 5-mg NTC patch.

Main measures. Age, sex, pain (measured with an analog visual scale) and adverse events. In patients who showed a partial response, treatment was repeated up to 3 times at 15-day intervals. Pain was tested after 7-10 days of treatment. Complete improvement was considered a reduction in pain of more than 5 points on the analog visual scale; partial improvement was considered a reduction of 3-5 points, and treatment failure was recorded when there was no improvement in pain or when there was a decrease of less than 3 points.

Results. A total of 48 patients were included; 33 (69%) were women and 15 (31%) were men. Mean age was 61 years. In group A, complete improvement was seen in 19 patients and partial improvement in 3; treatment failed in 2 patients. In group B complete improvement was seen in 5 patients, partial improvement in 5, and failure of treatment in 14. The difference between groups was statistically significant. Adverse events were mild pain at the injection site in 4 patients from group A, and headache in 15 patients from group B, 8 of whom abandoned treatment for this reason.

Conclusion. Treatment with NTG is not a clear alternative to infiltration of corticosteroids in patients with RCT, because of its lack of effectiveness and because of the greater number of patients who had adverse events that lead them to abandon treatment.

Key words: Rotator cuff tendinitis. Local infiltration. Transdermal nitroglycerin.

NITROGLICERINA TRANSDÉRMICA FRENTE A INFILTRACIONES EN LAS TENDINITIS DEL MANGUITO DE ROTADORES

Objetivo. Comparar la nitroglicerina transdérmica (NTG) con las infiltraciones en las tendinitis del manguito de los rotadores (TMR).

Diseño. Estudio experimental con asignación aleatoria y controlada de individuos.

Emplazamiento. Área básica semirural, en la comarca del Garraf (Barcelona), con una población asignada de 12.000 habitantes.

Pacientes y métodos. Pacientes diagnosticados de TMR de menos de 6 semanas de evolución que no hubiesen respondido a tratamiento con AINE por vía oral. Los pacientes se distribuyeron aleatoriamente en 2 grupos: *a*) grupo A: infiltración local por vía posterior con corticoide *depot* y anestésico local, y *b*) grupo B: parche de 5 mg de NTG durante 3 días.

Mediciones principales. Se valoraron edad, sexo, dolor (medido con la escala analógica visual) y efectos adversos. Si la respuesta era parcial, se repitió el mismo tratamiento hasta un máximo de 3 veces, con intervalos de 15 días y se realizó un control a los 7-10 días del tratamiento, considerando mejoría total la disminución del dolor más de 5 puntos en la EVA, mejoría parcial la disminución en 3-5 puntos y fracaso si no existía mejoría del dolor o bien disminuía en menos de 3 puntos.

Resultados. Se incluyeron 48 pacientes, 33 mujeres (69%) y 15 varones (31%) con una edad media de 61 años. En el grupo A obtuvieron mejoría total (MT) 19 pacientes, 3 lograron mejoría parcial (MP) y sólo hubo 2 fracasos. En el grupo B presentaron MT 5 pacientes, otros 5 mostraron MP y en 14 fracasó el tratamiento, con diferencias estadísticamente significativas al comparar los 2 grupos. En cuanto a efectos adversos, 4 pacientes del grupo A presentaron dolor leve en la zona de punción y 15 personas del grupo B tuvieron cefalea (8 de los casos abandonaron el tratamiento debido a ello).

Conclusión. El tratamiento con la NTG no es una clara alternativa a las infiltraciones en las TMR, dado que no es un tratamiento más efectivo y, por el contrario, hay un mayor número de pacientes con efectos adversos que deben abandonar el tratamiento.

Palabras clave: Tendinitis manguito rotadores. Infiltración local. Nitroglicerina transdérmica.

Spanish version available at
www.atencionprimaria.com/43.122

A commentary follows
this article (page. 456)

Área Básica de Salud de Garraf Rural, Barcelona.

Correspondence:
Sandra Pons Cuevas.
C/ Carlets, 32, 3.º, 2.ª, 08800
Vilanova i la Geltrú,
Barcelona, Spain.
Email: 32076spc@comb.es

Manuscript accepted for
publication 18.06.01.

Introduction

«Painful shoulder», which can significantly limit the patient's quality of life, is a frequent complaint in primary health care with an estimated yearly incidence of 11.2/1000 patients¹. The most frequent cause of this syndrome is rotator cuff tendinitis (RCT), although it can also arise from other disorders such as muscular injury, bursitis, or, less often, from joint problems. Treatment of this disorder is usually provided by the primary care physician, and the choice of treatment depends on the practitioner's preference, based mainly on acquired knowledge and personal experience. No clearly established criteria for choosing the most suitable treatment are available; despite the many published studies on this topic, there is little scientific evidence to support one option over another².

The three potential pharmacological treatments consist of transdermal nitroglycerin, infiltration with corticosteroids and local anesthesia, and nonsteroid antiinflammatory drugs. Transdermal nitroglycerin has been shown to be effective as an antiinflammatory and analgesic for different indications such as thrombophlebitis³, dysmenhorrea⁴ and RCT^{5,6}. Advocates of this approach explain these effects on the basis of the fact that nitroglycerin is transformed into nitric oxide in the vascular smooth muscle, and thus imitates the action of endogenous nitric oxide (produced in the endothelium) on the peripheral nervous system, and on the modulation of the inflammatory process⁵. On the other hand, infiltration of corticosteroids with local anesthesia has been found more effective than oral nonsteroid antiinflammatory drugs for RCT^{7,8}.

Given the high prevalence of RCT in our setting and the contraindications, the potential adverse effects of some treatments (i.e., oral antiinflammatory drugs) and the invasive nature of other treatments (i.e., local infiltration), we believed it worthwhile to investigate the efficacy of transdermal nitroglycerin for the treatment of pain in RCT. If this treatment were found to be at least as effective as conventional treatments, it might offer advantages (ease of application, low cost, nonaggressive nature) that would make nitroglycerin an attractive alternative.

The aim of this study was to compare the effects of transdermal nitroglycerin and local infiltration of corticosteroids in controlling the pain of RCT in patients who had not responded to oral nonsteroid antiinflammatory drugs.

Material and methods

This experimental study, in which patients were assigned randomly to receive one treatment or the other, was done at the primary health care center of a semirural basic health care area in the Garraf region, Barcelona province, Spain. The health care

center serves a population of approximately 12000 inhabitants, most of whom have received a moderate to low level of formal schooling. About 60% of the population are of legal working age, and the main types of employment are construction work (men) and cleaning work (women).

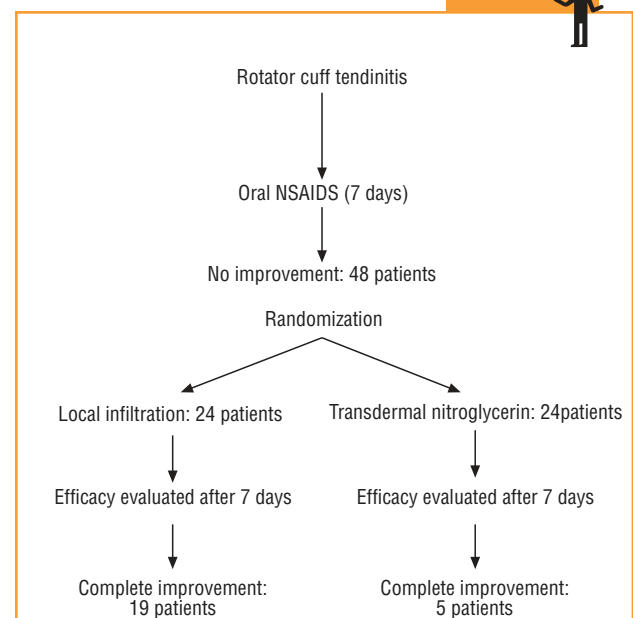
The participants were selected during a visit to the health center at which they were seen by members of one of three different primary care teams. The inclusion criteria were: *a*) clinical diagnosis of RCT, defined as pain on moving the arm through a 60–120° arc, positive impingement test and positive Jove (supraspinatus), Gerbe (subscapularis) or Pate (infraspinatus and teres minor) test¹⁰; *b*) symptoms present for less than 6 weeks at the time of diagnosis; and *c*) no response to previous treatment for one week with oral nonsteroid antiinflammatories. Patients were excluded if they had adhesive capsulitis (limited or painful passive mobility of the shoulder), biceps tendinitis (positive palm up test or Yergason test), allergy or intolerance of any of the drugs used in the study, or if they were receiving treatment with nitroglycerin patches for heart disease.

Sample size was calculated at 24 patients per group according to a comparison of proportions test for a unilateral hypothesis. Alpha error was set at 0.05, and beta error at 0.20. Keeping in mind that the efficacy of infiltration is 70–90%, we assumed that a difference of 30% or less would be clinically relevant.

The main variable in the study was pain, measured with a visual analog scale (VAS) at the time of inclusion in the study and after 7 days of treatment. Other variables studied were age, sex and adverse effects of both treatments.

From May 1999 to April 2000 all patients who came to the center and fulfilled the inclusion criteria were assigned to one of two

Material y métodos

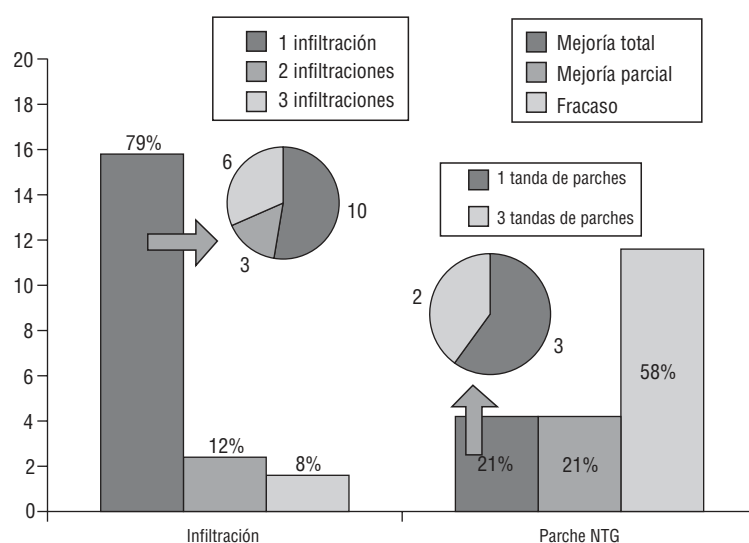


Scheme of the study design

Experimental study with randomized distribution of participants.

FIGURE 1

Analgesic efficacy of the two treatments.



groups (A or B) according to a random number table, if they gave their consent to take part after receiving verbal information about the study. Group A patients received infiltration via a posterior approach (1 cm below the outer edge of the posterior spine of the scapula) of 1 ml triamcinolone acetonide and 1 ml 2% mepivacaine delivered with a 21 G intramuscular needle. Group B patients were given a set of 5-mg nitroglycerin patches to be placed over the area of worse pain (lateral face of the shoulder) for 3 days. Each patient was trained in the proper way to apply the patch daily. During the treatment period no oral analgesics or antiinflammatories were allowed.

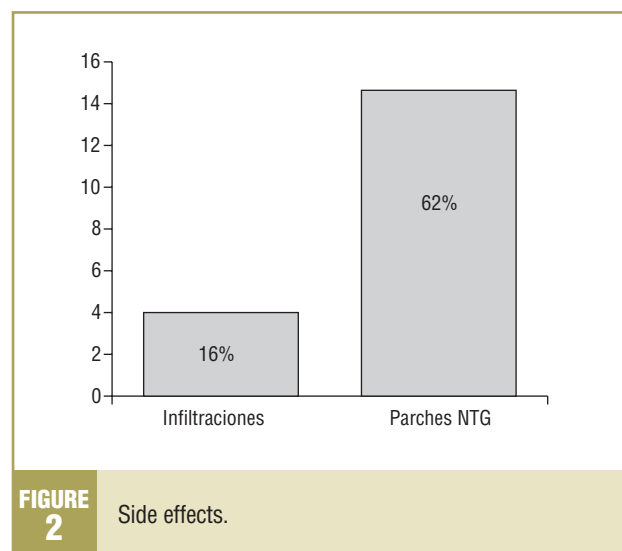
After 7 days of treatment we evaluated the dependent variables pain and adverse events. Complete improvement was considered a reduction in pain of more than 5 points on the VAS; partial improvement was considered a reduction of 3-5 points, and treatment failure was recorded when there was no improvement in pain or when the decrease was less than 3 points. Adverse effects were also recorded. Patients whose pain did not show complete improvement were given an appointment 15 days after treatment to receive nitroglycerin or infiltration depending on their initially assigned treatment, and pain and adverse events were again recorded one week later. This procedure was repeated up to 3 times. Scheme illustrates the overall design of the study.

The results were analyzed statistically by comparison of proportions with the SPSS. The results were expressed together with 95% confidence intervals (CI).

Results

A total of 48 patients (33 women, 69%, and 15 men, 31%) were studied. Mean age was 61 years. There were no significant differences between the groups in age or sex.

In group A complete improvement was seen in 19 patients (79%), partial improvement in 3 (12%) and treatment failure in 2 (8%). Of the 19 patients with complete improvement, this result was obtained with one infiltration in 10

**FIGURE 2**

Side effects.

participants, 2 infiltrations in 3, and 3 infiltrations in 6. In group B complete improvement was seen in 5 patients (21%), partial improvement in 5 (21%) and treatment failure in 14 (58%). Of the 5 patients with complete improvement, this result was obtained with one 3-day set of patches in 3, and with 3 sets of patches in 2 (fig. 1).

With regard to adverse effects, 4 patients (16%) in group A reported mild pain at the injection site, whereas in group B 15 patients (62%) reported headaches, which led 8 of them to abandon treatment (fig. 2).

When we compared patients who showed complete improvement with the other two outcome groups (partial improvement and treatment failure), we found a difference in the proportion of each treatment group of 0.58 (95%

CI: 0.35–0.81), which was statistically significant. When we compared the proportions of patients with complete and partial improvement, the difference in proportion between the two treatment groups was 0.500 (95% CI: 0.27–0.72), which was also statistically significant.

Discussion

The conclusions of this study indicate that the analgesic efficacy of corticosteroid injections is greater than that of transdermal nitroglycerin. Moreover, the frequency of adverse effects was higher with the latter treatment. The adverse effects of nitroglycerin were tolerated poorly by our patients, 53% of whom abandoned treatment for this reason. In contrast, the adverse effects of corticosteroid infiltration did not lead to any drop-outs.

A similar study done in 1999 in the Florida Nord basic health care area (L'Hospitalet de Llobregat), in which topical nitroglycerin was used for different locomotor disorders potentially treatable with infiltration, yielded similar results. Of the 31 patients who were treated, 22.6% attained complete improvement, 29% partial improvement, and 48% failed to respond. Moreover, 50% of the patients abandoned treatment because they could not tolerate the adverse effects (mainly headache). These findings are broadly similar to the results of the present study. However, a study by Berrazueta et al. that compared topical nitroglycerin and a placebo for RCT found significant differences in favor of nitroglycerin. It should nonetheless be noted that the statistical power and design of their study were problematic: only 10 patients were included in each group, and the response was evaluated after a very short treatment period (24 and 48 h).

In the present study, randomization bias was significantly reduced by a controlled, random process of assignment; thus our groups were comparable for prognostic factors. However, some limitations should be noted. The variable we used to measure treatment efficacy (decrease or no change in pain) is difficult to measure. It would be worthwhile to obtain information on other parameters such as functional improvement in the joint mobility. In addition, the best way to evaluate treatment is known to be by comparison against a placebo; hence our results should be interpreted with caution, despite the fact that other studies have reported very similar findings⁹. Finally, the high percentage of drop-outs as a result of adverse events needs to be taken into account in the evaluation of the response to treatment in the group that used transdermal nitroglycerin.

References

1. Van der Windt DA, Koes BW, De Jong BA, Bouter LM. Shoulder disorders in general practice: incidence, patient characteristics, and management. *Ann Rheum Dis* 1995; 54: 959-964.
2. Green S, Buchbinder R, Glazier R, Forbes A. Systematic review of randomised controlled trials of interventions for painful shoulder: selection criteria, outcome assessment, and efficacy. *BMJ* 1998; 316: 354-360.
3. Berrazueta JR, Fleitas M, Salas E, Amado JA, Poveda JJ, Ochoteco A et al. Local transdermic glyceryl trinitrate has an anti-inflammatory action on thromboflebitis induced by sclerosis of leg varicose veins. *Angiology* 1994; 45: 421-431.
4. Anónimo. Transdermal nitroglycerine in the management of pain associated with primary dysmenorrhoea: a multinational pilot study. The Transdermal Nitroglycerine/Dysmenorrhoea Study Group. *J Int Med Res* 1997; 25: 41-44.
5. Berrazueta JR, Losada A, Poveda J, Ochoteco A, Riestra A, Salas E et al. Successful treatment of shoulder pain syndrome due to supraspinatus tendinitis with transdermal nitroglycerin. A double blind study. *Pain* 1996; 66: 63-67.
6. Querol M, Puy L, Adroer R, Vives A, Montverde X, Solà M. Nitroglicerina transdérmica: una alternativa a les infiltracions locals de l'aparell locomotor? ABS Florida Nord, L'Hospitalet de Llobregat. Ponència en el XIV Congrés de Atenció Primària de la SCMFIC, 1999.
7. Adebajo AO, Nash P, Hazleman BL. A prospective double blind dummy placebo controlled study comparing triamcinolone hexacetonide injection with oral diclofenac 50 mg TDS in patients with rotator cuff tendinitis. *J Rheumatol* 1990; 17: 1207-1210.
8. Goupille P, Sibilia J. Local corticosteroid injections in the treatment of rotator cuff tendinitis (except for frozen shoulder and calcific tendinitis). *Clin Exp Rheumatol* 1996; 14: 561-566.
9. Querol M, Puy L, Adroer R, Vives A, Ballvé JL, Montverde X. Infiltracions a l'àrea bàsica. ABS Florida Nord. Ponència en el XIV congrés de Atenció Primària de la SCMFIC, 1999.
10. Arribas JM. Cirugía menor y procedimientos en medicina de familia. *Mafrid: Jarpyo*, 2000.

Discussion Key points



What is known about the topic

- Rotator cuff tendinitis is a frequent and incapacitating disorder.
- The available treatments are oral nonsteroid antiinflammatory drugs, local corticosteroid infiltration and transdermal nitroglycerin.
- Different treatments are often needed to attain improvement in symptoms and function.

What this study contributes

- The efficacy of treatment with local corticosteroid infiltration was compared with that of transdermal nitroglycerin.
- Local infiltration led to greater improvements than did nitroglycerin.
- The use of transdermal nitroglycerin led to more side effects.

COMMENTARY

Transdermal nitroglycerine versus corticosteroid infiltration for rotator cuff tendinitis

J.J. Rodríguez Alonso

Primary Care Center Villaviciosa de Odón, Madrid. Coordinator of the Traumatology Group in Primary Care.

The painful shoulder syndrome is a frequent cause of visits to primary care physicians. Between 10% and 20% of the population can expect to have at least one episode of this disorder¹.

The etiopathogenic mechanisms of painful shoulder have not been adequately established^{2,3}. In some cases there are clear antecedents of mechanical overload or traumatic injury, but in others these antecedents are lacking, or the patient has no recollection of any cause that might account for the pain. In addition, the disorder is more common against a background of certain clinical entities such as diabetes, although the causes of this relationship are unknown.

Conservative approaches to treatment offers several options⁴. Pharmacological treatment is based mainly on non-steroid antiinflammatories and analgesics, and on the infiltration of depot corticosteroids and anesthetics. Physiotherapy is another available option.

As yet there are no clear clinical criteria for choosing one option over another, for combining different treatments, or for deciding in which order to use different options. None of the treatments individually is infallible, and practitioners must rely on their own training and experience in deciding which option to use. Because of these uncertainties, new lines of research are being tried (and further possibilities also merit study) with the aim of developing appropriate treatments with lower risks.

Surprisingly, despite the high incidence of this disorder there are few well-structured studies that compare treatment alternatives⁵. The article in this issue by Pons et al. compares one treatment previously found to be superior to a placebo, i.e., local infiltration of corticosteroids⁶, with a newer option: nitroglycerin patches placed over the painful area. The results of their study show that nitroglycerin patches cannot be considered an additional treatment option: the hoped-for clinical benefits were not obtained, and moreover many patients abandoned treatment because of adverse effects.

Infiltration in Primary Care

- Painful shoulder is a highly prevalent disorder in our setting. Most patients are treated by their family doctor.
- Additional epidemiologic research is needed to evaluate the actual status of this disorder in primary care.
- Family physicians should have adequate skills to treat the disorder, including knowledge of local infiltration and physiotherapy, with the aim of reducing the patient's pain and functional limitations as promptly as possible.
- New approaches to treatment aimed at enhancing the results without increasing risks or side effects should be explored.

Bibliografía

1. Croft P. Soft tissue rheumatism. En: Silman AJ, Hochberg MC, editores. Epidemiology of the reumatic diseases. Oxford: Oxford University Press, 1993; 375-421.
2. Rathburn JB, Macnab I. The microvascular pattern of the rotator cuff. J Bone Joint Surg 1970; 52: 540-553.
3. Meer. Impingement lesions. Clin Orthop 1983; 173: 70-71.
4. Van der Windt, Koes B, Shoulder disorders in general practice: incidence, patient characteristics and management. Ann Rheum Dis 1995; 51: 959-964.
5. Green S, Buchbinder R. Systematic review of randomised controlled trials of interventions for painful shoulder: selection criteria, outcomes assessment, and efficacy. BMJ 1998; 316: 354-360.
6. Fernández A, Povedano J, Campos S, García-López A. Eficacia clínica de las infiltraciones con esteroides. Rev Esp Reumatol 1998; 25: 361-370.