

CLINICAL RESEARCH

Surgical repair of congenital mitral valve malformations

Pedro Curi-Curi,¹ Samuel Ramírez-Marroquín,² Jorge Cervantes-Salazar,³ Mauricio Soulé,¹ Julio Erdmenger,⁴ Juan Calderón-Colmenero.⁵

¹*Cirujano Cardiovascular Pediátrico.*

²*Jefe del Departamento de Cirugía Cardíaca Pediátrica y de Cardiopatías Congénitas.*

³*Subjefe del Departamento de Cirugía Cardíaca Pediátrica y de Cardiopatías Congénitas.*

⁴*Médico Ecocardiografista Pediátrico. Departamento de Cardiología Pediátrica.*

⁵*Subjefe del Departamento de Cardiología Pediátrica.*

Instituto Nacional de Cardiología Ignacio Chávez

Received in July 9, 2009; accepted in October 9, 2009.

KEY WORDS

Mitral valve repair;
Cardiac pediatric
surgery; Mexico.

Abstract

Surgical development of mitral valve repair techniques in pediatric patients has been slow because of the great variety in the presentation of congenital mitral valve malformations and the still unknown growing effect over the complex mitral valve apparatus. The aim of this study is to review our early and mid-term institutional outcomes in surgical repair of congenital mitral valve malformations. We studied retrospectively 14 patients with surgical repair of congenital mitral valve malformations in a 5 year period. Clinical and echocardiographic follow-up at a mean of 25 months was performed in all cases. Operative morbidity was 77% and operative mortality 7%. There were no late deaths. Clinical functional class stratification at the mid-term improved in 73% of survivors and did not change in the remaining 27%. Freedom from reoperation for mitral valve prosthetic replacement due to mitral valve repair failure was 84% at 30 days and 77% at 3.5 years. Surgical repair is probably the best technique option in the treatment of congenital malformations of the mitral valve, and transesophageal intraoperative echocardiography must be highly recommended for evaluation of results.

PALABRAS CLAVE

Reparación valvular
mitral; Cirugía cardíaca
pediátrica; México.

Reparación quirúrgica de las malformaciones congénitas de la válvula mitral

Resumen

El desarrollo de las técnicas de plastia mitral en el paciente pediátrico ha sido lento debido a la gran variabilidad de presentación de las lesiones mitrales congénitas, y al poco conocido efecto del crecimiento sobre el complejo aparato valvular mitral. El objetivo de este estudio fue

revisar nuestra experiencia institucional en el corto y mediano plazo en la reparación quirúrgica de las valvulopatías mitrales congénitas. En forma retrospectiva se estudió una serie de 14 pacientes operados de reparación quirúrgica por valvulopatía mitral congénita en un lapso de cinco años. Se realizó seguimiento clínico y ecográfico en todos los casos a los 25 meses en promedio. La morbilidad operatoria de la serie fue de 77% y la mortalidad operatoria de 7%. No hubo mortalidad tardía. En el mediano plazo, la capacidad funcional mejoró en 73% de los sobrevivientes y se mantuvo en 27%. El índice de sobrevida libre de re-operación para cambio valvular por falla de la plastia mitral fue de 84% a los 30 días y de 77% a los 3.5 años. La reparación valvular mitral en el paciente pediátrico es probablemente la técnica de elección en el tratamiento quirúrgico de la patología valvular mitral congénita, y la ecocardiografía transesofágica intraoperatoria debe ser considerada como una herramienta altamente recomendable para evaluar los resultados.

Introduction

The mitral valve is a complex morphologic and functional apparatus formed by the annulus, leaflet valves, tendineal chords, papillary muscles and left ventricular wall.¹ Pathologic lesions that affect one or more of these components result in a valvular stenosis and/or insufficiency.²

Appropriate diagnosis of the valvular malformation and the assessment of its severity by transthoracic echocardiography have been complemented by transesophageal echocardiography which improve knowledge of production mechanisms of the mitral lesions. This, in fact, has contributed to the development of the current interest in surgical repair techniques as an alternative to mitral valve prosthetic replacement.³

The advantages of mitral valve surgical repair techniques over mitral valve prosthetic replacement in adults has been widely accepted.⁴ However, the development of these techniques in pediatric patients has been slow because of the great variety in the presentation of congenital mitral valve malformations and the still unknown effect of growth over the complex mitral valve apparatus.⁵⁻¹⁶ Additionally, experience in surgery of mitral valve malformations in Mexico is poor and limited to stenotic lesions.¹⁷ Congenital insufficiency, which is the most frequent mitral valve lesion, is not well described in our country.

The objective of this study is to review, the early and mid-term results in the surgical repair of congenital mitral valve malformations at our institution.

Methods

Group of study. Between January 2002 and May 2007, we retrospectively studied all pediatric patients in whom surgical valve repair was performed because of mitral congenital malformation in the National Institute of Cardiology Ignacio Chavez.

From a total of 27 patients with surgical mitral valve repair, we excluded those with acquired mitral valve disease, cyanotic congenital heart disease, atrioventricular septal defect, L-transposition of great arteries, single ventricle, Marfan syndrome, and anomalous left coronary origin from pulmonary artery (ALCAPA). We included in our study 14 patients with congenital mitral valve malformations.

Preoperative echocardiography diagnosis of the mitral valve malformations was performed in all cases in order

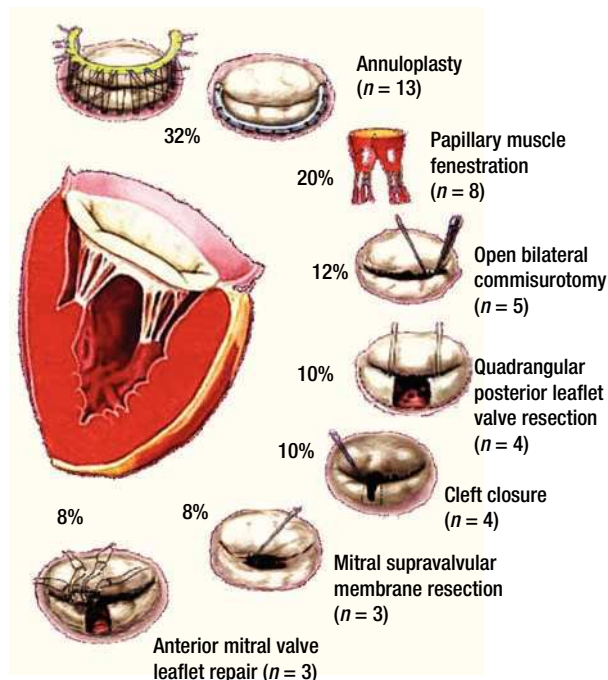


Figure 1. Schematic diagrams of surgical mitral valve repair techniques and number of cases.

to establish the type of valvular lesions according to the pathophysiological Carpentier's classification.⁸ In those patients with complex mitral valve lesions, the predominant lesion was used for their classification.

Surgical technique: Surgical approach for all patients was through a median sternotomy. Cardiopulmonary bypass was established by aortic and bicaval cannulation. After aortic cross clamp, we used moderate hypothermia and antegrade blood cardioplegia for myocardial protection. Only in one case we used crystalloid antegrade and retrograde cardioplegia. The mitral valve was approached by left atriotomy in all cases, and several mitral surgical repair techniques were used for every patient.

Figure 1 describes the surgical techniques used for mitral valve repair, and **Figure 2** the associated procedures. After weaning of cardiopulmonary bypass was completed, and before the decannulation time, we routinely

Table 1. Clinical features of the studied cases. CML= Complex mitral lesion, >= Predominance of, St.= stenosis, Insuf.= insufficiency.

Case	Age (years)	Weight (kg)	Diagnosis	Mitral echographic lesion grade
Case 1	9	20	Displasic mitral hammock-like valve with posterior leaflet valve cleft	Severe insuf.
Case 2	9	17	Mitral supralvalvular membrane with posterior leaflet tendineal chords fusion to left ventricle wall	CML > Severe insuf.
Case 3	2.5	10	Mitral parachute-like valve with fibrosis and commissural fusion and a single anteromedial papillary muscle	CML > Severe St.
Case 4	0.4	4.4	Mitral supralvalvular membrane and displasic retracted mitral valve with commissural fusion and fibrosed tendineal chords	CML > Severe Insuf.
Case 5	2	9	Mitral parachute-like valve with a single papillary muscle and commissural fusion	Moderate St.
Case 6	0.1	3.5	Displasic mitral valve with anterior leaflet cleft and prolapse	Severe Insuf.
Case 7	10	21	Dilated mitral annulus with a large redundant and prolapsant anterior leaflet with a flail tendineal chord	Svere Insuf.
Case 8	1.9	8.2	Displasic mitral valve with retraction of the posterior leaflet due to fibrosis and shortened subvalvular apparatus	Severe Insuf.
Case 9	9.1	26	Displasic mitral valve with anterior leaflet cleft and propapse due to elongated tendineal chords	Important Insuf.
Case 10	0.8	5.3	Displasic mitral valve with a single shortened and forked papillary muscle	Severe Insuf.
Case 11	0.4	6.8	Displasic mitral valve with anterior prolapsant leaflet due to anomalous implantation of its papillary muscle	Severe Insuf.
Case 12	0.3	4.5	Obstructive supralvalvular membrane with normal mitral valve	Moderate St.
Case 13	0.8	7.6	Mitral parachute-like valve with thickened leaflets, commissural fusion and a single papillary muscle	CML > Moderate Insuf
Case 14	16	50	Normal mitral valve with annulus dilatation	Moderate Insuf.

performed an intraoperative transesophageal echocardiography to evaluate mitral competence after valve repair.

Follow-up strategy: We carried out a clinical and echocardiographic early and mid-term follow-up. All survivors had a clinical follow-up evaluation of their functional class stratification using the New York Heart Association classification (NYHA) for children and young patients,¹⁸ and the modified Ross classification for neonates and infants.¹⁹ Echocardiographic follow-up was obtained in all of the symptomatic patients and in 50% of the asymptomatic ones. The degree of mitral echocardiographic insufficiency was estimated by a semiquantitative method based in the maximum lenght and width of the regurgitant jet in relation to the left atrium as follows: 0 = none, without regurgitation; 1 = mild, regurgitant jet less than 1/3 the lenght and width of the left atrium; 2 = moderate, regurgitant jet between 1/3 and 1/2 of this lenght and width; 3 = moderate to severe, regurgitant jet between 1/2 and 2/3; and 4 = severe, regurgitant jet larger than 2/3 of the lenght and width of the left atrium. We also evaluated the regurgitant jet direction. Degree of stenosis was minimum, moderate or severe depending on the transvalvular mitral valve gradient and the area of the orifice of this valve in relation to the patient's age and weight.²⁰

Statistical analysis: Information was obtained from our institutional clinical database, stored in an electronic Excell page and processed with a SPSS statistical software. Numeric results are presented as a mean, variability ranges, and percentages in relation to the risk population. Overall survival rate and freedom from reoperation for mitral valve prosthetic replacement survival rate were calculated using the Kaplan - Meier method.

Table 2. Associated congenital malformations.

Associated malformation	Number (n)	Percentage (%)
Ductus	3	38%
Ventricular septal defect	2	25%
Atrial septal defect	2	25%
Insufficient bicuspid aortic valve	1	12%

Results

Clinical features of the 14 patients (eight males and six females) of our study are summarized in **Table 1**. Age ranged between one month and 16 years (mean 4.4 years), with a mean weight of 13.8 kg (range, 3.5 to 50 kg), mean length of 92 cm (range, 50 to 155 cm), and body surface area of 0.6 m² (range, 0.22 to 1.46 m²).

Twelve (86%) of these patients did not have previous cardiovascular surgical or interventional procedures. Two cases had an associated aortic coartation that was treated by surgical coartectomy in one of them (7%). In the other case (7%) an interventional balloon dilatation of the coartated segment was performed. Associated congenital malformations occurred in eight patients (57%), as shown in **Table 2**.

Sinus rhythm was present in all patients at the time of admission to the hospital, and in two of them (14%) the electrocardiogram (ECG) showed a right bundle branch block. Half of the patients were in heart failure preoperatively, but only one (7%) required inotropic support before

Table 3. Patient groups according to Carpentier's pathophysiological classification.

MITRAL INSUFFICIENCY 79% (n = 11)	MITRAL STENOSIS 21% (n = 3)
Normal valve leaflets movement: 42%	Abnormal papillary muscles: 14%
Valvular leaflets cleft (n = 3)	Parachute-like mitral valve (n = 2)
Annular dilatation (n = 2)	
Obstructive chord (n = 1)	
Restrictive valve leaflets movement: 37%	Normal papillary muscles: 7%
Shortened chord (n = 4)	Supravalvular mitral membrane (n = 1)
Commissural fusion (n = 1)	

surgery. None of the patients needed mechanic ventilation, and all of them received an appropriate preoperative medical treatment in order to arrive to surgery in the best hemodynamic conditions as possible.

Mitral valve repair was possible in all of the cases, with a mean cardiopulmonary bypass time of 96min (range, 44 to 174min), aortic cross-clamp of 61 min (range, 18 to 134min) and 29°C hypothermia (range, 25 to 32°C). Mitral predominant lesion was incompetence in 11 patients (79%) and stenosis in three (21%). **Table 3** shows the groups of patients according to Carpentier's pathophysiological classification.⁸

The surgical techniques used were mitral annuloplasty, papillary muscles fenestration, open bilateral commissurotomy, valve cleft closure and supravalvular mitral membrane resection. Less frequently used techniques were anterior valve leaflet repair (with bovine pericardial patch enlargement, tendineal chords resuspension or reduction) and quadrangular posterior leaflet valve resection. We used bovine pericardium for all mitral annuloplasties, except in one case that received a rigid Carpentier hemiannulus. Concurrent repair of associated lesions included ductus closure in three cases, ventricular septal defect closure in two cases, and atrial septal defect closure

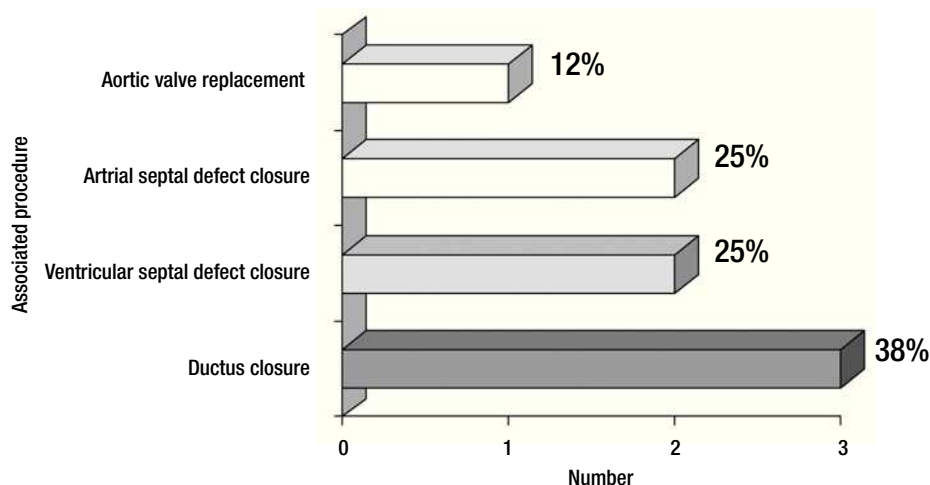
Table 4. Operative morbidity causes.

Operative morbidity causes		Number (n)	Percentage (%)
Cardiac (n = 8)	Right ventricular failure	1	3%
	Left ventricular failure	3	11.5%
	Biventricular failure	2	6%
	Tachi-arrhythmia	2	6%
Respiratory (n = 11)	Prolonged mechanic ventilation	5	16%
	Pulmonary hypertension	3	11.5%
	Neumothorax	1	3%
	Pleural effusion	1	3%
Infectious (n = 6)	Bilateral atelectasia	1	3%
	Neumonia	5	16%
	Pulmonary abscess	1	3%
Surgical (n = 3)	Residual mitral insufficiency	2	6%
	Mitral repair dehiscence	1	3%
Neurologic (n = 3)	Stroke	1	3%
	Convulsive syndrome	2	6%

in two cases. Additionally, we performed an aortic valve replacement in the oldest patient of our series (16 years) who had a severe regurgitant congenitally bicuspid aortic valve in association with a moderate mitral valve insufficiency (**Figure 2**).

There were no operative complications and operative morbidity rate was 77%. Morbidity events are described in **Table 4**. There was only one early death (operative mortality of 7%), from hypovolemic shock from a subclavian artery lesion due to a re-introduction of a central venous catheter.

The 13 survivors had a mean postoperative hospitalization stay of 15.5 days (range, 4 to 56 days), and 3.7 days (range, 1 to 11 days) in the Intensive Care Unit, with a mean mechanic ventilation time of 4 days (range, 2 hours to 20 days). There were four patients who

**Figure 2.** Number and percentage of associated surgical procedures.

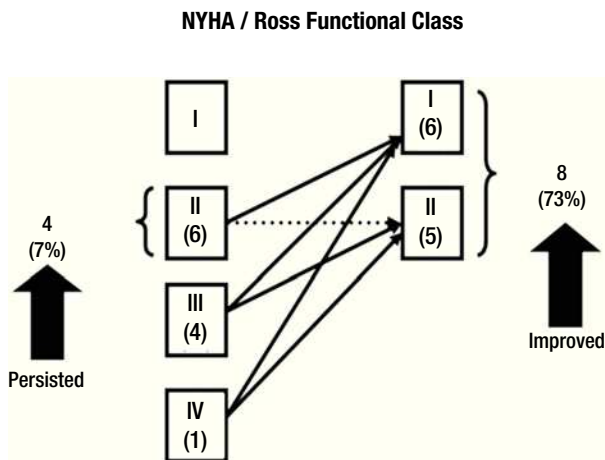


Figure 3. Change in NYHA/Ross functional class after mitral valve repair in patients with mitral insufficiency.

needed reoperation during the early postoperative period (30.7%), with a mean of 1.2 (range, 1 to 2) reoperations per patient with mean time of 11.5 days (range, 1 to 28 days) after the first surgery. In two cases, reoperations were needed for extracardiac reasons (tracheostomy with gastrostomy, and left superior lung abscess drainage). In another case, reoperation was to perform a pericardial window because of pericardial effusion. Finally, two of the reoperations were for mitral valve prosthetic replacement because of early failure of the mitral valve repair. The first patient was a six month male infant with a mitral supralvalvular membrane, a dysplastic stenotic mitral valve due to tendineal chord fibrosis, commissural fusion and retraction of the anterior mitral valve leaflet. In the operation we resected the mitral supralvalvular membrane, performed a commisurotomy and a bovine pericardial patch ampliation of the anterior mitral valve leaflet. Although transesophageal echocardiography reported a moderate residual mitral valve regurgitation, weaning of cardiopulmonary by-pass at the first time was successful without early hemodynamic deterioration. In the early postoperative period he developed clinical and radiologic signs of acute pulmonary edema, and six hours later was reoperated for mitral valve replacement with an aortic St. Jude 17 mechanical prosthesis placed invertedly in a supra annular mitral position, with a successful postoperative course. The second patient was a eight months female infant who had a dysplastic mitral valve with a single shortened and forked papillary muscle. We performed a bilateral commisurotomy, papillary muscle fenestration and an annuloplasty with a bovine pericardial hemiannulus. Additionally she had a ventricular septal defect that was repaired with a bovine pericardial patch and a patent ductus arteriosus that was closed at the same time. Moderate stenosis and regurgitation without residual septal defects was reported by the transesophageal intraoperative echocardiography. Postoperatively she had prolonged mechanic ventilation due to heart failure, and nine days later we decided to reoperate this patient for mitral valve replacement with a mechanical Carbomedics

17 mitral valve in annular position, with good postoperative results. Up to date, both patients are asymptomatic and with appropriate prosthetic valve performance at the echocardiographic control.

Clinical follow-up was made at a mean time of 29 months (range, 15 days to 57 months) in all of the survivors. **Figure 3** shows functional class stratification according to the NYHA and the modified Ross classification evolution between preoperative and mid-term follow-up in patients with mitral insufficiency. All of the patients with mitral stenosis which had III NYHA/Ross functional class improved to class I. Morbidity rate at mid time follow-up was of 15.3% (two patients). One of these patients developed an embolic stroke with left hemiplegia and gastroesophageal reflux. The other one required a mitral prosthetic valve replacement two years after the first operation, because of mitral valve repair failure. Additionally, a patient in our series developed mitral valve repair failure at the mid time (22 months), of no important clinical significance. In this case, optimum medical treatment has allowed us to delay the time of reoperation until he reaches the adequate age to perform a definitive prosthetic valve replacement.

We did an echocardiographic follow-up in eight of the 13 survivors (65%) at a mean time of 1.8 years (range, one month to 2.6 years). All the remaining patients who did not have echocardiographic follow-up were asymptomatic. Only three of the patients who had echocardiographic follow-up were symptomatic. Therefore, we made an echocardiographic follow-up in all the symptomatic patients and in 50% of the asymptomatic ones at a mean time of 21 months (range, 10 to 33 months). In **Figure 4** we resume the clinical outcome of our patients. There were no late deaths. **Figure 5** shows that the overall survival rate after surgical mitral valve repair is of 93% at 30 days and does not vary up to 3.5 year follow-up. It also shows freedom from reoperation for mitral valve prosthetic replacement survival curve in the early and mid time follow-up. We can say that the successful rate observed in our series for surgical mitral valve repair was 84% at 30 days and 77% at 3.5 years. The estimated freedom from reoperation for mitral valve prosthetic replacement survival curve at 5 years was 77% and 66% at 10 years follow-up.

Discussion

The spectrum of congenital mitral valve malformations ranges from the readily reparable anterior mitral leaflet cleft to the restrictive and challenging lesions of mitral stenosis. Whatever the abnormality, the incidence of associated heart defects is high^{6,9,11} and can have a significant impact on the eventual clinical outcome.

Because of the significant short- and long-term problems with mechanical and bioprosthetic mitral valves in children^{21,22}, considerable attention has been paid to mitral remodeling techniques^{9,11,15} for both incompetent and stenotic valves. This trend has lowered the perioperative mortality from as high as 21% to 43% for mitral valve replacement^{5,23,24} to as low as 0% to 5% for mitral valve repair.^{9,10,15,16,23} Our overall operative mortality is along with these trends.

One of the most common causes of mitral insufficiency in our series was anterior leaflet valve cleft, as well as

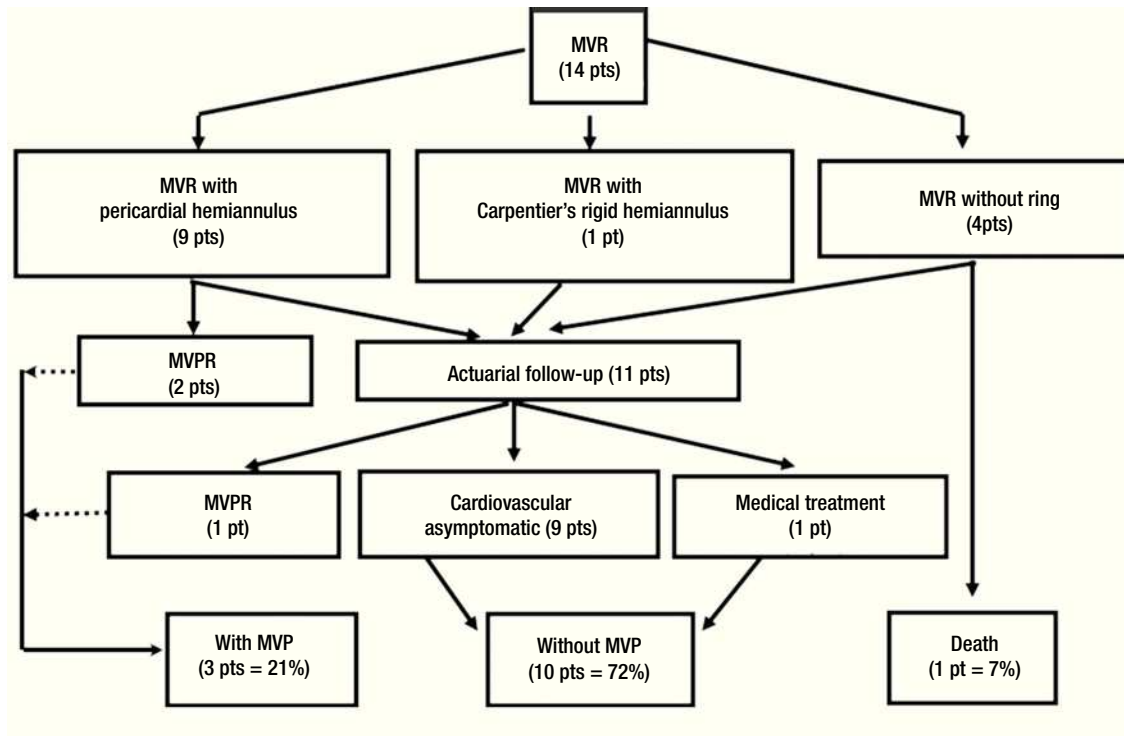


Figure 4. Clinical follow-up outcome of surgical treatment in congenital mitral valve malformations. MVR= Mitral valve repair, MVPR= Mitral valve prosthetic replacement, MVP= Mitral valve prosthesis, pt(s)= patient(s).

shortening of tendineal chords. The simple cleft closure with or without papillary muscles fenestration was the only procedure used for a correct mitral valve competence. More challenging is the infant and young child with annular dilatation and mitral insufficiency who will require native annular remodeling with a posterior hemiannulus. Although we used a rigid Carpentier hemiannulus in a young child, in infants and children in growing ages there are more problems in choosing a correct prosthesis size. Chavaud and associates⁹ have approached this problem by performing the posterior annular reduction without the use of a rigid prosthesis. Based on Rowlatt's,²⁵ measurements they used Goretex or pericardial hemiannulus for the reduction of the posterior native mitral annulus, because the anterior aspect does not enlarge as much due to its fibrous constitution. In our series we only used one Carpentier rigid hemiannulus in a young child. All of the other children received a bovine pericardial hemiannulus. This biologic tissue is similar to the autologous pericardium, but has the advantage in that it is easier to manipulate. The manufacturing of this material in our institution and its availability in different sizes and thickness without an additional economic cost, makes bovine pericardium the material of choice to perform the mitral hemiannular posterior reduction in infants and children at growing ages in our series.

The most common cause of mitral stenosis in our series was the parachute-like mitral valve, which was treated with fenestration of papillary muscles in most of the cases. Another cause was supravulvar mitral membrane,

usually associated with other stenotic lesions such as redundant valvular tissue, and commissure and/or papillary muscle fusion. For this reason, simple resection of the supravulvar membrane was not able to achieve an appropriate relief of the mitral stenosis, so we associated another procedure such as open mitral commissurotomy, papillary muscle fenestration, or resection of redundant valvular tissue.

There were three patients in our series who needed reoperation because of failure of the original mitral valve surgical repair. Transesophageal intraoperative echocardiography was very useful to evaluate the immediate results of surgical mitral valve repair, and identify early technical failure. We only had a patient who developed hemodynamic instability and needed mitral valve prosthesis replacement before chest closure. Hemodynamic status was acceptable in the other two cases after weaning of cardiopulmonary bypass. This fact allowed the surgeon for chest closure, but they developed cardiac failure in the Intensive Care Unit that requiring reoperation for mitral valve prosthetic replacement. One of them was reoperated before 30 days and the other after two years of the first mitral valve repair. The early reoperation rate compares favorably to other reports^{5,6,13,15} of mitral valve repair in children. The immediate reoperation rate before chest closure on the basis of hemodynamic findings and intraoperative transesophageal echocardiography is not widely reported. In our series the outcome of the 3 reoperated patients (23%) was favorable after the mitral valve prosthetic replacement. Most reports dealing

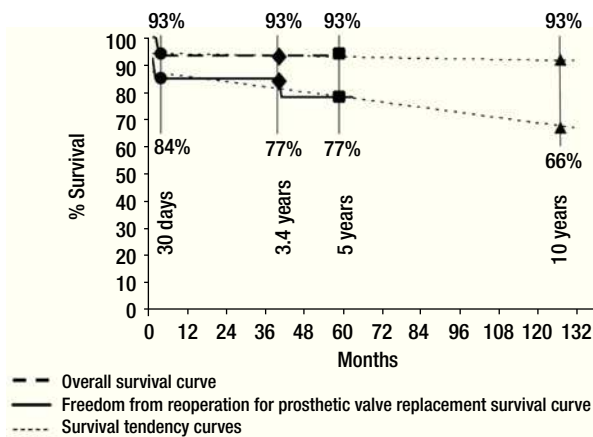


Figure 5. Early and mid-term curves and tendencies of overall survival and freedom from reoperation for mitral valve prosthetic replacement survival after surgical mitral valve repair.

with congenital anomalies^{5,9,10} recognize the importance of intraoperative transesophageal echocardiography for functional evaluation giving the surgeon the option for reintervention as deemed necessary.

Although we believe that intraoperative transesophageal echocardiography is an important method that allows the surgeon to decide which is the best surgical mitral repair technique to use and to evaluate the early results, our final decision depends on the type of patient we deal with. The low socioeconomic level of the majority of our patients and their rural environment difficults an appropriate oral anticoagulation treatment, because of the lack of INR laboratory resources close to home. This is the reason why we try to preserve their native mitral valve the longer time as possible, even if we know by echocardiographic evaluation that the result is not always entirely satisfactory.

Our overall survival early and mid-term rate, as well as the freedom from reoperation for mitral valve prosthetic replacement survival rate were favorable and similar to the experience of other centers.^{5,9,10,15,26} The low incidence of thromboembolic episodes observed in our patients is also consistent with the findings of others^{5,9,10,15,26} and contributes to the low postoperative morbidity. We believe that anticoagulation therapy is not needed for patients with surgical mitral valve repair except for the first three months postoperatively in our only case where Carpentier's rigid hemiannulus prosthesis was used. This is the time a rigid hemiannulus prosthesis requires to become endothelialized.

Conclusion

Malformations of the mitral valve are not a common pathology, and our experience with this study has the proper limitations of a retrospective one. Although this series cannot lead us to drive definite conclusions, we can say

that mitral valve repair in pediatric patients is probably the best technique option in the treatment of congenital malformations of the mitral valve, because of the satisfactory early and mid-term outcomes, low global mortality and a high freedom from reoperation for mitral valve prosthetic replacement survival rate. In addition, mitral valve repair allows preservation of the native valve without interfering with its growth, avoiding anticoagulation at an early age. On the other hand, the routine use of transesophageal intraoperative echocardiography must be highly recommended for evaluation of results in a surgical mitral valve repair procedure.

References

1. Perloff JK, Roberts WC. The mitral apparatus. *Circulation* 1972;46:227-239.
2. Carpentier A, Guerinon J, Deloche A, et al. Pathology of the mitral valve: Introduction to plastic and reconstructive valve surgery. En: Kalmanson D (ed): *The mitral valve, A Pluridisciplinary Approach*. Acton, England, Publishing Science Group, 176; p 65.
3. Enriquez-Sarano M, Schaff HV, Orszulak TA, et al. Valve repair improves the outcome of surgery for mitral regurgitation. A multivariate analysis. *Circulation* 1995;91:1022-1028.
4. Deloche A, Jebara VA, Relland JY, et al. Valve repair with Carpentier techniques. The second decade. *J Thorac Cardiovasc Surg* 1990;99:990-1002.
5. Aharon AS, Laks H, Drinkwater DC, et al. Early and late results of mitral valve repair in children. *J Thorac Cardiovasc Surg* 1994;107:1262-1271.
6. Almeida RS, Elliott MJ, Robinson PJ, et al. Surgery for congenital abnormalities of the mitral valve at the Hospital for Sick Children, London from 1969-1983. *J Cardiovasc Surg* 1988;29:95-99.
7. Anderson RH. Surgical treatment of congenital lesions of the mitral valve. *Cardiol Young* 1997;7:2-4.
8. Carpentier A, Chauvaud S, Mihaileanu S. Classification of congenital malformations of the mitral valve and their surgical management. In: Crupi G, Parenzan L, Anderson RG, eds. *Perspectives, En: pediatric cardiology*, vol. 2. Part 3, Pediatric cardiac surgery. Mt Kisco, NY: Futura Publishing Company, 1990;97-102.
9. Chauvaud SM, Mihaileanu SA, Gaer JAR, et al. Surgical treatment of congenital mitral valve insufficiency: "The Hospital Broussais" experience. *Cardiol Young* 1997;7:5-14.
10. Chauvaud SM, Mihaileanu SA, Gaer JAR, et al. Surgical treatment of congenital mitral valve stenosis: "The Hospital Broussais" experience. *Cardiol Young* 1997;7:15-21.
11. Coles JG, Williams WG, Watanabe T, et al. Surgical experience with reparative techniques in patients with congenital mitral valvular anomalies. *Circulation* 1987;76 (Suppl III):117-122.
12. Kadoba K, Jonas RA, Mayer JE, et al. Mitral valve replacement in the first year of life. *J Thorac Cardiovasc Surg* 1990;100:762-768.
13. Okita Y, Miki S, Kusuhaara, et al. Early and late results of reconstructive operation for congenital mitral regurgitation in pediatric age group. *J Thorac Cardiovasc Surg* 1988;96:294-298.
14. Ruckman RN, Van Praagh R. Anatomic types of congenital mitral stenosis: report of 49 autopsy cases with consideration of diagnosis and surgical implications. *Am J Cardiol* 1978;42:592-601.
15. Sousa UM, Galletti L, Gayet FL, et al. Surgery for congenital mitral valve disease in the first year of life. *J Thorac Cardiovasc Surg* 1995; 109:164-176.
16. Stellin G, Bortolotti U, Mazzucco A, et al. Repair of congenitally malformed mitral valve in children. *J Thorac Cardiovasc Surg* 1988;95:480-485.
17. Alva C, González B, Meléndez C, et al. Estenosis mitral congénita. Experiencia 1991-2001. *Arch Cardiol Mex* 2001;71 (3):206-213.

18. AHA Medical / Scientific Statement: 1994 revisions to classification of functional capacity and objective assessment of patients with diseases of the heart. *Circulation* 1994;90:644-645.
19. Ross RD, Daniels SR, Schwartz DC, et.al. Plasma norepinephrine levels in infants and children with congestive heart failure. *Am J Cardiol* 1987;59: 911-914.
20. Sheikh KH, Bengtson JR, Rankin JS, et al. Intraoperative transesophageal doppler color flow imaging used to guide patient selection and operative treatment of ischemic mitral regurgitation. *Circulation* 1991;84:594-604.
21. Borkon AM, Soule L, Reitz BA, et al. Five- year follow up after valve replacement with the St. Jude Medical valve in infants and children. *Circulation* 1986;74(Suppl):110-15.
22. Geha AS, Laks H, Stansel HC Jr, et al. Late failure of porcine valve heterografts in children. *J Thorac Cardiovasc Surg* 1979;78:351-364.
23. Kadoba K, Jonas RA, Mayer JE, et al. Mitral valve replacement in the first year of life. *J Thorac Cardiovasc Surg* 1990;100:762-768.
24. Williams WG, Pollock JC, Geiss DM, et al. Fowler RS. Experience with aortic and mitral valve replacement in children. *J Thorac Cardiovasc Surg* 1981;81:326-333.
25. Rowlatt UF, Rimoldi HJA, Lev M. The quantitative anatomy of the child's heart. *Pediatr Clin North Am* 1963;10:499 -588.
26. Zias E, Mavroudis C, Backer C, et al. **Surgical repair of the congenitally malformed mitral valve in infants and children.** *Ann Thorac Surg* 1998; 66:1551-1559.