

IMAGE IN CARDIOLOGY

## Image of an extensive aneurysm in a young patient

## Imagen de un aneurisma extenso en un paciente joven



Tatiana Chantal Castro-De la Torre<sup>a</sup>, Leticia Rodríguez-Mariscal<sup>a</sup>,  
Martha A. Hernández-González<sup>b</sup>, Sergio Solorio<sup>c,\*</sup>

<sup>a</sup> Servicio de Cardiología, UMAE 1 Bajío IMSS, León Gto, Mexico

<sup>b</sup> Servicio de Cardiología, HGZ 21 IMSS, León Gto, Mexico

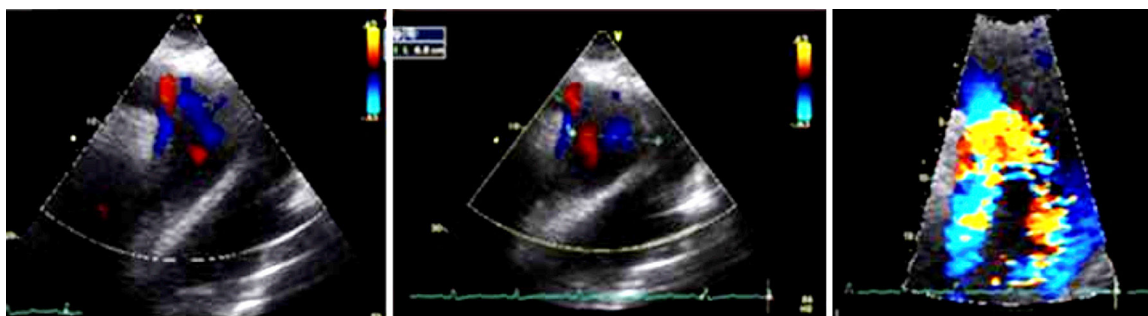
<sup>c</sup> Unidad de Investigación, UMAE 1 Bajío IMSS, León Gto, Mexico

Received 24 June 2015; accepted 17 February 2016

The acute aortic syndrome refers to a spectrum of life-threatening aortic emergencies. Acute aortic syndromes include non-traumatic entities as aortic dissection with an incidence of 80–90% of the cases, affecting 5–30 person-years, penetrating atherosclerotic ulcer with a incidence of 2.8% and intramural hematoma with incidence of 5–25%. Nowadays there are several imaging modalities for diagnosis, such as echocardiography, magnetic resonance imaging

and computed tomography angiogram without let out the clinical characteristics and keep in mind differential diagnosis for initial suspicion (Figs. 1 and 2).<sup>1–3</sup>

We report the case of a hypertensive 42-year-old, with obesity and obstructive sleep apnea. He starts with oppressive chest pain with adrenergic discharge at rest, lasting 40 min, blood pressure was documented to 180/111, electrocardiogram with positive slope of the ST in aVR and V1



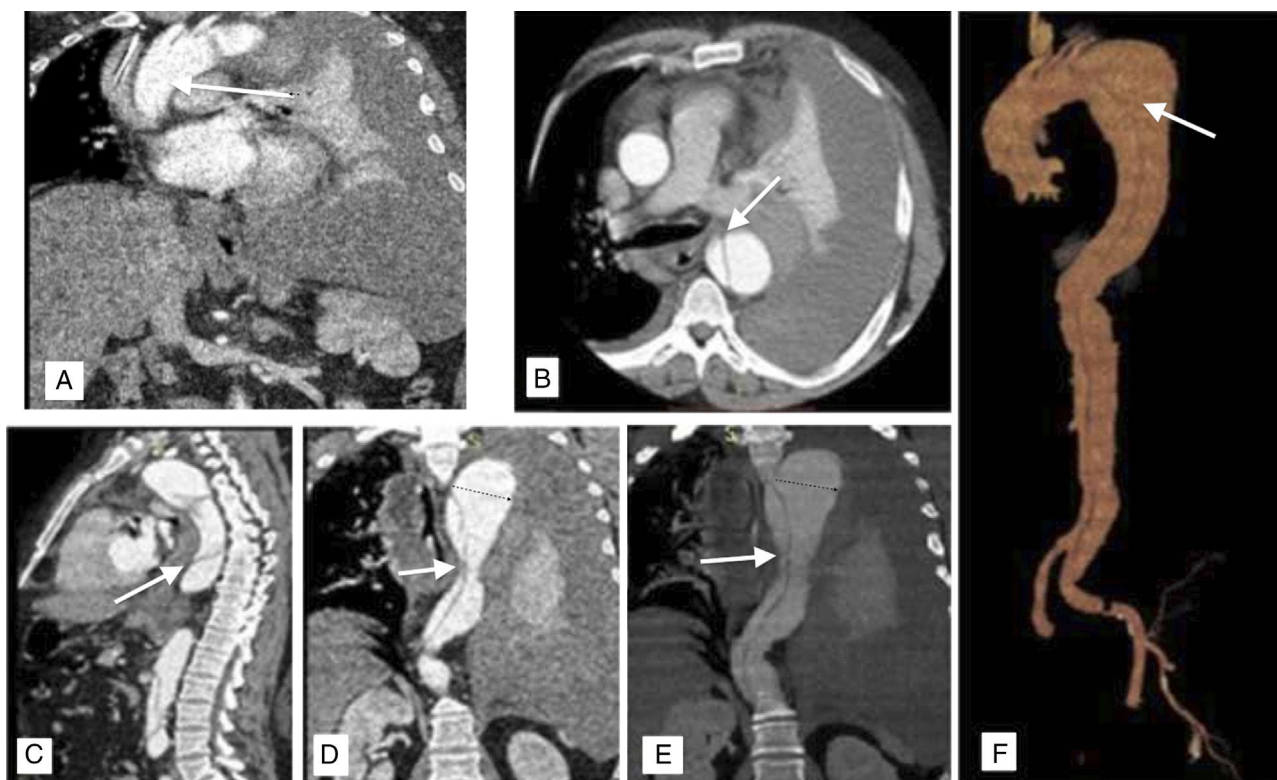**Figure 1** Axis suprasternal echocardiogram, aortic arch and descending aorta is observed, with double-lumen image.

\* Corresponding author at: Unidad de Investigación, UMAE 1 Del Bajío León IMSS, Blvd Lopez Mateos esq Insurgentes SN, León Gto, Mexico CP 37320, Mexico. Tel.: +52 477 7174800x31788.

E-mail addresses: [soloriosergio@aol.com](mailto:soloriosergio@aol.com),  
[sergio.solorio@imss.gob.mx](mailto:sergio.solorio@imss.gob.mx) (S. Solorio).

<http://dx.doi.org/10.1016/j.acmx.2016.02.002>

1405-9940/© 2016 Instituto Nacional de Cardiología Ignacio Chávez. Published by Masson Doyma México S.A. This is an open access article under the CC BY-NC-ND license (<http://creativecommons.org/licenses/by-nc-nd/4.0/>).



**Figure 2** (A and B) Chest CT sagittal and axial scans showing aneurysmal dilatation with extravasation area, left pleural effusion. (C–E) Sagittal and coronal section showing double lumen from descending aorta to common iliac. (F) Digital reconstruction of aorta.

and negative troponin. The patient developed cardiogenic shock and death.<sup>4–7</sup> Acute aortic syndrome should be identified early by clinical suspicion and supported by diagnostic studies to provide timely treatment because of its high mortality rate. Diagnostic imaging studies in clinical suspicion of dissection play an important role, such as confirmation of clinical suspicion, classification of dissection, localization of tears, assessment of extent of dissection and indicators of urgency.<sup>8</sup>

### Ethical responsibilities

**Protection of human and animal subjects.** The authors declare that no experiments were performed on humans or animals for this study.

**Confidentiality of data.** The authors declare that no patient data appear in this article.

**Right to privacy and informed consent.** The authors declare that no patient data appear in this article.

### Funding

No endorsement of any kind received to conduct this study/article.

### Conflict of interest

The authors declare no conflict of interest.

### References

1. Vilacosta I, San Ramon JA. Acute aortic syndrome. *Heart*. 2001;85:265–8.
2. Salvolini L, Renda P, Fiore D, et al. Acute aortic syndromes: role of multi-detector row CT. *Eur J Radiol*. 2008;65:350–8.
3. Hagan PG, Nienaber CA, Isselbacher EM, et al. The International Registry of Acute Aortic Dissection (IRAD): new insights into an old disease. *JAMA*. 2000;283:897–903.
4. Nienaber CA, Powell JT. Management of acute aortic syndromes. *Eur Heart J*. 2012;33:26–35.
5. Aboyans V, Kownator S, Lafite M, et al. Screening abdominal aorta aneurysm during echocardiography: literature review and proposal for a French nationwide study. *Arch Cardiovasc Dis*. 2010;103:552–8.
6. Lohou C, Lubniewski P, Fetnaci N, et al. Interventional planning and assistance for ascending aorta dissections. *IRBM*. 2013;34:306–10.
7. Bossone E, Pyeritz RE, O’Gara P, et al. Acute aortic dissection in blacks: insights from the International Registry of Acute Aortic Dissection. *Am J Med*. 2013;126:909–15.
8. Nienaber CA. The role of imaging in acute aortic syndrome. *Eur Heart J Cardiovasc Imaging*. 2013;14:15–23.