



## Revista Portuguesa de Estomatologia, Medicina Dentária e Cirurgia Maxilofacial

www.elsevier.pt/spemd



### Clinical case

## Posterior lingual bone depression diagnosis using 3D-computed tomography

Luís Silva Monteiro<sup>a,b,\*</sup>, Marco Infante Da Câmara<sup>a</sup>, Fausto Tadeu<sup>a</sup>,  
Filomena Salazar<sup>a</sup>, José Júlio Pacheco<sup>a</sup>

<sup>a</sup> Departamento de Ciências Dentárias, Instituto Superior de Ciências da Saúde Norte, Paredes, Portugal

<sup>b</sup> Serviço de Estomatologia e Medicina Dentária do Centro Hospitalar de São João – Pólo Valongo, Portugal

#### ARTICLE INFO

##### Article history:

Received 14 February 2012

Accepted 20 May 2012

Available online 31 July 2012

##### Keywords:

Bone cysts

Salivary glands

Mandible

Oral pathology

#### ABSTRACT

In 1942, Stafne described a series of asymptomatic unilocular radiolucent lesions, with well defined margins located near the angle of the mandible. These rare lesions represent non-progressive bone cavities where clinical and imaging control is preferred to invasive treatment. The evidence of a concavity with a lingual opening defined by an intact compact cortical excludes most of the differential diagnosis of other types of bone lesions for which surgical treatment is needed. This article reports the usefulness of three-dimensional computed tomography reconstruction for the confirmation of two cases of posterior lingual mandibular bone depressions and makes a review on pathogenesis and methods of investigation of these lesions.

© 2012 Sociedade Portuguesa de Estomatologia e Medicina Dentária. Published by Elsevier España, S.L. All rights reserved.

### Diagnóstico de depressão óssea lingual posterior utilizando tomografia computorizada 3D

#### RESUMO

Em 1942, Stafne descreveu uma série de lesões radiolúcidas uniloculares assintomáticas, de bordos bem definidos, localizadas perto do ângulo da mandíbula. Estas lesões raras representam cavidades ósseas não progressivas onde o controle clínico e imagiológico é preferido a tratamento invasivo. A evidência de uma concavidade com abertura lingual definida por uma cortical íntegra exclui a maior parte dos diagnósticos diferenciais de outras lesões ósseas para as quais o tratamento cirúrgico é necessário. Este artigo reporta a utilidade da tomografia computadorizada com reconstrução tridimensional na confirmação de dois casos de depressões ósseas mandibulares posteriores e realiza uma revisão sobre a patogénese e métodos de diagnóstico destas lesões.

© 2012 Sociedade Portuguesa de Estomatologia e Medicina Dentária. Publicado por Elsevier España, S.L. Todos os direitos reservados.

##### Palavras-chave:

Quistos ósseos

Glândulas salivares

Mandíbula

Patologia oral

\* Corresponding author.

E-mail address: lmonteiro\_md@hotmail.com (L.S. Monteiro).

## Introduction

In 1942, Edward Stafne described a series of 35 asymptomatic radiolucent lesions, located in the mandible, which he called "bone cavities situated near the angle of the mandible". These ovoid unilocular radiolucencies with well-defined margins of dense bone were all located between the first molar and the mandibular angle, below the mandibular canal.<sup>1</sup> Since then, several publications have classified these kind of lesions such as cyst, cavity, defect or depression.<sup>2-5</sup> Moreover some have suggested that these bone depressions are part of a group of mandibular concavities called mandibular bone depressions (MBD) that can be topographically systematized in four variants: lingual posterior, lingual anterior, lingual in the mandibular ramus and buccal in the mandibular ramus.<sup>5</sup>

Posterior lingual mandibular bone depressions (PL-MBD) are very rare with a frequency of 0.08–0.48% in clinical-radiographic studies and from 0.73 to 1.28% based on the observation of dry mandibles.<sup>5-9</sup> Male gender is more affected with a 6:1 ratio.<sup>5,6</sup> They have been described in ages ranging from 11 to 87 years, although they are more frequently detected in the 5th and 6th decades of life.<sup>5,6,10</sup> Almost all PL-MBD are asymptomatic, being detected occasionally in routine radiographic examination.<sup>5,10</sup>

The aim of this article is to describe the usefulness of computed tomography (CT) with three-dimensional reconstruction for the diagnosis confirmation of two cases of PL-MBD.

## Clinical cases

### Case 1

A 44-year-old Caucasian male was referred by his dentist on the finding, in a routine panoramic radiograph, of a left mandibular radiolucent image. During anamnesis he did not report any symptoms, and indicated a history of hepatitis C (already treated) and of tooth extractions. There was no previous history of facial trauma or surgery. Physical examination revealed no clinical evidence of intra-oral, facial or neck swellings. The patient presented a brachyfacial type profile. On dental examination it was evidenced the absence of the left mandible first molar and right mandible second molar. The panoramic radiograph demonstrated a well-demarcated, unilocular radiolucent lesion, measuring 1.5 cm in the mesio-distal diameter, in the posterior region of the left mandible with upper limit overlapping the mandibular canal (Fig. 1A). In order to obtain a definitive diagnosis we performed a CT-scan (multislice CT Thoshiba® Aquilion S16, Thoshiba Europe Medical System, Zoetermeer, Netherlands, 1 mm-thick slices) with three-dimensional reconstruction that revealed an osteolytic image measuring 1.3 cm in the mesio-distal diameter, with a lingual opening with an intact bony cortical lining, containing soft tissues compatible with lobe of the submandibular gland (Fig. 1B–C). The final diagnosis of this concavity was PL-MBD. No treatment of PL-MBD was performed. After 5 years of follow-up the defect remained without alterations.

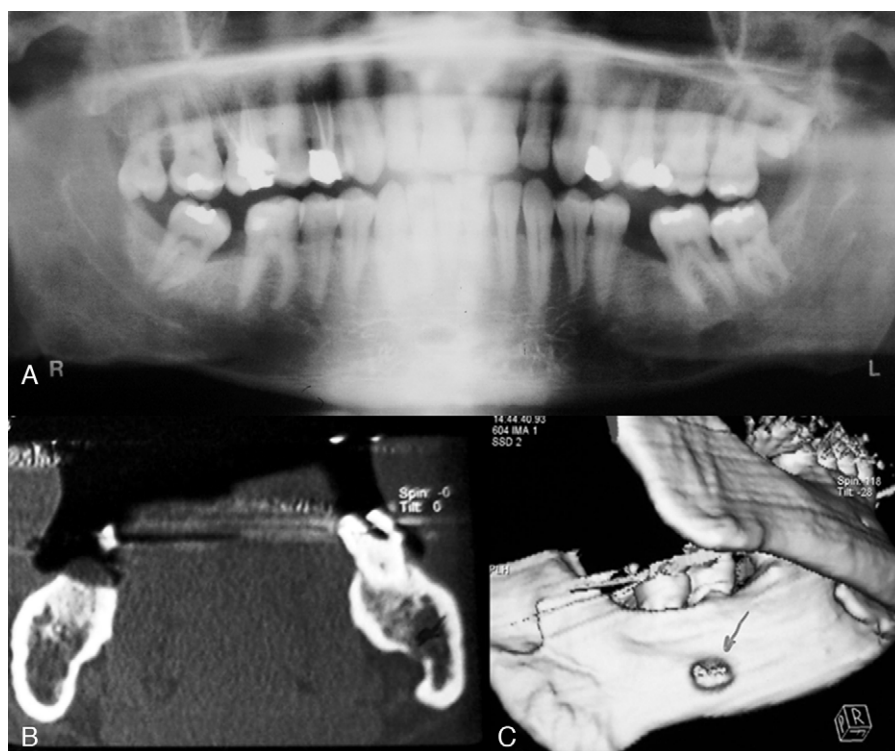
### Case 2

A 54-year-old Caucasian male, was referred by his dentist, on the finding, of a right mandibular radiolucent image, detected in a panoramic radiograph for a prosthetic rehabilitation study. During anamnesis the patient reported oro-facial diffuse pain, and did not mention any history of previous surgery or oro-facial trauma. No swellings were detected in intra-oral, facial and neck examination. The patient presented a brachyfacial type profile. Several teeth were absent. There was pain on palpation of the masticatory muscles. The panoramic radiograph revealed a well-demarcated, oval, unilocular radiolucent lesion, measuring 1.5 cm in the mesio-distal diameter, located in the posterior region of the right side of the mandible unrelated to teeth and beneath the mandibular canal (Fig. 2A). The orofacial pain was related with the absence of posterior inferior teeth and the mandibular lesion was a probable PL-MBD. A CT-scan with three-dimensional reconstruction was performed (multislice CT Thoshiba® Aquilion S16, Zoetermeer, Netherlands, 1 mm-thick slices) and revealed an osteolytic image of 1.5 cm in mesio-distal diameter, with a lingual opening limited by a bony cortical lining containing an image compatible with soft tissues (Fig. 2B–D). The final diagnosis of this concavity was PL-MBD. No treatment of PL-MBD was performed, keeping the patient under clinical and radiological surveillance. After 2 years of follow-up the defect remained without alterations.

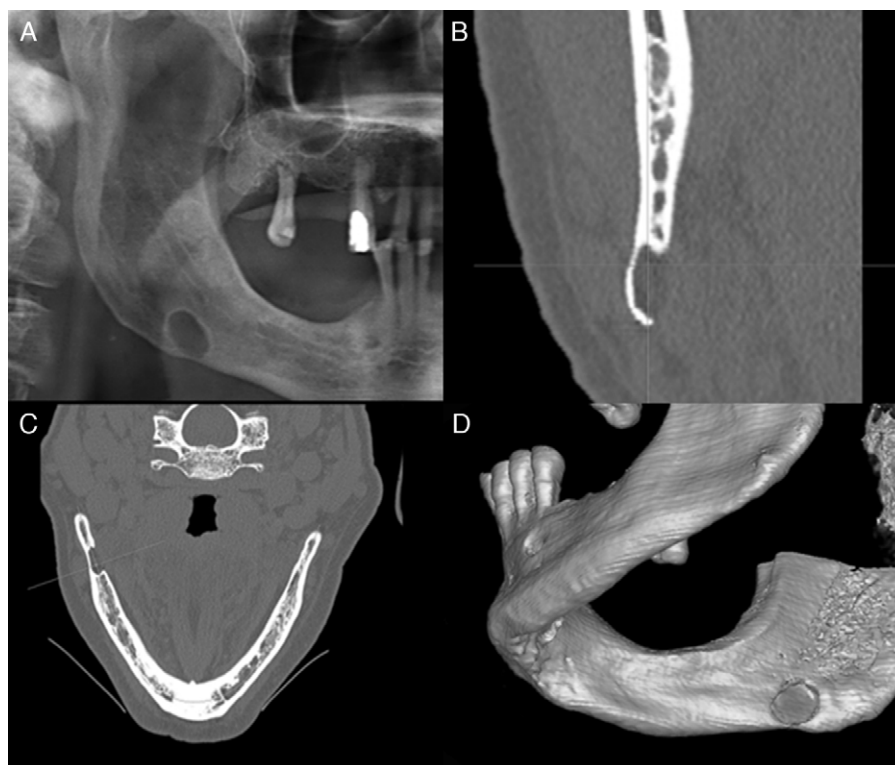
## Discussion

Since the first description of PL-MBD by Stafne, the pathogenesis of these cavities remains not fully understood. Stafne originally suggested that these cavities could result from a failure of normal deposition of bone in the Meckel's cartilage.<sup>1</sup> Fordyce, one of the first to identify the presence of glandular tissue in biopsies of two cases, believed it was an anatomical congenital defect caused by embryonic remnants of the submandibular gland trapped inside the body during its mandibular ossification.<sup>11</sup> However, there are few described cases in children and Stafne bone cavities have been found in mandibles that were previously normal.<sup>4,5,12</sup> Even Stafne, eventually abandoned its initial proposal on being a congenital defect.<sup>9</sup> Kay et al.,<sup>7</sup> suggested that the etiology was related to an abnormal facial artery vascular pressure, which, with its winding course along the inferior border of the mandible could lead to necrosis and bone resorption. For Lello and Makek<sup>13</sup> these cavities were a result of focal bone atrophy due to an ischemic process associated with degenerative arterial changes.

In recent years several imaging studies such as sialography, magnetic resonance imaging (MRI), CT and CT sialography confirmed the findings of the initial surgical approaches and of some histopathological analysis of these cavities showing the presence of the submandibular gland in many cases.<sup>4,9-11,14,15</sup> Other report by Harvey and Noble<sup>8</sup> observed areas with active bone remodeling in the lingual concavity, which indicates the existence of compression on the lingual cortical bone. Therefore, this cavity may be caused by hypertrophy/hyperplasia of submandibular gland, leading to focal bone remodeling



**Fig. 1 – (A)** Panoramic radiograph reveals a well-demarcated, unilocular radiolucent area in the lower left angle of the mandible. **(B)** Axial cone-beam CT showing a lingual opening of the PL-MBD, containing soft tissue inside compatible with glandular tissue. **(C)** CT with three-dimensional reconstruction image.



**Fig. 2 – (A)** Panoramic radiograph showing a well-demarcated, unilocular radiolucent area in the lower right angle of the mandible. Axial **(B)** and coronal **(C)** cone-beam CT showing a lingual opening of the PL-MBD. **(D)** CT with three-dimensional reconstruction image.

in response to a chronic pressure exerted on the cortical bone.<sup>4,5,10</sup> Identical cavities located lingual to the anterior mandible may be related to the sublingual gland, and more rarely on the buccal side of the posterior mandibular region associated with the parotid gland.<sup>5,12,16</sup> However, not all imaging or surgical approaches of these lesions revealed glandular tissue.<sup>3,17</sup> Some bone cavities were found to be occupied by adipose tissue, lymphoid tissue, neuromuscular tissue, fibrous tissue or even devoid of any content.<sup>13,17</sup> Interestingly, Arija et al.,<sup>3</sup> found glandular tissue in large lesions and in smaller lesions found only adipose tissue. Shimizu et al.,<sup>4</sup> observed that the submandibular gland on the cavity side was located anteriorly when compared with the contralateral side without Stafne bone defect, in some cases containing only fat tissue or other soft tissue content. Based on these observations, the authors attributed the cause of the Stafne's bone defect to the anterior dislocation of the submandibular gland.

All these reports lead to a more comprehensive pathogenesis view in that the PL-MBD appears as a result of continued pressure on the lingual cortical originating from herniation or hypertrophy of the submandibular gland or adjacent tissues including adipose, muscle, lymphoid or neuro-vascular tissues.<sup>3</sup> Our cases are similar, with soft tissue content compatible with the salivary gland. Interestingly all patients had a brachyfacial type profile. Can this feature lead to higher risk of pressure in the mandibular lingual cortical? No references in scientific literature to the facial type are mentioned and the limited cases of the present work make it difficult to establish this relationship.

The cases we present show the same epidemiological values of previous publications regarding PL-MBD such as prevalence in the 5th and 6th decade of life and in males. All cases were detected by radiographic findings in line with the asymptomatic nature of PL-MBD most described in literature.<sup>5,6,10,18,19</sup>

The PL-MBD diagnosis can be presumed in most cases with these radiographic characteristics, particularly in panoramic radiographs. However, in atypical cases, differential diagnosis with others lesions should be done including solitary bone cyst, traumatic bone cyst, dentigerous cyst, keratocystic odontogenic tumor, residual cyst, non-ossifying fibroma, focal osteoporotic bone marrow defects, fibrous dysplasia, ameloblastoma, central giant cell granuloma, giant cell tumor, vascular malformation, multiple myeloma or brown tumor of hyperparathyroidism.<sup>4,20</sup> To a definitive diagnosis other complementary diagnostic exams such as CT, MRI, sialography or biopsy should be performed.<sup>3,15,17,18,20</sup> One of the most important aspects in confirming this diagnosis is the demonstration of the opening of the concavity enclosed by an intact cortical on the lingual side of the mandible, below the milohyoid line.<sup>2,3</sup> In the first case the upper limit of the cavity was overlapping the mandibular canal and in the second case the patient referred diffuse oro-facial pain. In this view we decided to make a CT scan to a definitive diagnosis which demonstrate this opening of the concavity enclosed by an intact cortical on the lingual side of the mandible in all cases. Additionally, the possibility of a three-dimensional reconstruction of the lesion permits a clear and global visualization of the shape of the concavity opening to the lingual surface of mandible. With the development of these imaging techniques and taking in

account that these lesions represent non-progressive static entities, clinical and imaging control are preferred to any invasive treatment. Moreover, there are authors who use these cavities, especially in bilateral cases, to increase retention of lower dentures.<sup>21</sup> In cases with lesion progression or suspicion of other lesions biopsy or surgery approaches with its anatomic-pathological examination may be indicated.<sup>5,10,22</sup>

In conclusion this article demonstrates the usefulness of CT with three-dimensional reconstruction for confirmation of PL-MBD. Evidence of a concavity with a lingual opening defined by an intact compact cortical excludes most of the differential diagnosis of other types of bone lesions for which surgical treatment is needed.

## Ethical disclosures

**Confidentiality of data.** The authors declare that they have followed the protocols of their work center on the publication of patient data and that all the patients included in the study have received sufficient information and have given their informed consent in writing to participate in that study.

**Right to privacy and informed consent.** The authors have obtained the informed consent of the patients and/or subjects mentioned in the article. The author for correspondence is in possession of this document.

## Conflicts of interest

The authors have no conflicts of interest to declare.

## Acknowledgments

The authors would like to thank Suzana Cadilhe for invaluable English language consultation.

## REFERENCES

1. Stafne EC. Bone cavities situated near the angle of the mandible. *J Am Dent Assoc.* 1942;29:1969-72.
2. Junquera LM, Albertos JM, Ferreras J, Baladron J. Stafne bone cyst. Revision of four cases, one of them with bilateral affection. *Ann Otolaryngol Chir Cervicofac.* 1999;116:295-8.
3. Arija E, Fujiwara N, Tabata O, Nakayama E, Kanda S, Shirtsuchi Y, et al. Stafne's bone cavity. Classification based on outline and content determined by computed tomography. *Oral Surg Oral Med Oral Pathol Oral.* 1993;76:375-80.
4. Shimizu M, Osa N, Okamura K, Yoshiura K. CT analysis of the Stafne's bone defects of the mandible. *Dentomaxillofac radiol.* 2006;35:95-102.
5. Philipsen HP, Takata T, Reichart PA, Sato S, Suei Y. Lingual and buccal mandibular bone depressions: a review based on 583 cases from a world-wide literature survey, including 69 new cases from Japan. *Dentomaxillofac Radiol.* 2002;31:281-90.
6. Sisman Y, Miloglu O, Sekerci AE, Yilmaz AB, Demirtas O, Tokmak TT. Radiographic evaluation on prevalence of Stafne bone defect: a study from two centres in Turkey. *Dentomaxillofac Radiol.* 2012;41:152-8.
7. Kay LW. Some anthropologic investigations of interest to oral surgeons. *Int J Oral Surg.* 1974;3:363-79.

8. Harvey W, Noble WH. Defects on the lingual surface of the mandible near the angle. *Br J Oral Surg.* 1968;6:75-83.
9. Tsui S, Chan F. Lingual mandibular bone defect. Case report and review of the literature. *Aust Dent J.* 1994;39:368-71.
10. Quesada-Gómez C, Valmaseda-Castellón E, Berini-Aytés L, Gay-Escoda C. Stafne bone cavity: a retrospective study of 11 cases. *Med Oral Patol Oral Cir Bucal.* 2006;11:277-80.
11. Fordyce GL. The probable nature of so called latent haemorrhagic cysts of the mandible. *Br Dent J.* 1956;101:40-2.
12. Wolf J. Bone defects in mandibular ramus resembling developmental bone cavity (Stafne). *Proc Finn Dent Soc.* 1985;81:215-21.
13. Lello GE, Makek M. Stafne's mandibular lingual cortical defect: discussion of aetiology. *J Maxillofac Surg.* 1985;13:172-6.
14. Shibata H, Yoshizawa N, Shibata T. Developmental lingual bone defect of the mandible. Report of a case. *Int J Oral Maxillofac Surg.* 1991;20:328-9.
15. Li B, Long X, Cheng Y, Wang S. Cone beam CT sialography of Stafne bone cavity. *Dentomaxillofac Radiol.* 2011;40:519-23.
16. Turkoglu K, Orhan K. Stafne bone cavity in the anterior mandible. *J Craniofac Surg.* 2010;21:1769-75.
17. Minowa K, Inoue N, Izumiyama Y, Ashikaga Y, Chu B, Maravilla KR, et al. Static bone cavity of the mandible: computed tomography findings with histopathologic correlation. *Acta Radiol.* 2006;7:705-9.
18. Etöz M, Etöz OA, Sahman H, Sekerci AE, Polat HB. An unusual case of multilocular Stafne bone cavity. *Dentomaxillofac Radiol.* 2012;41:75-8.
19. Monteiro L, Sousa A. Depressão óssea mandibular lingual posterior. *Rev Port Estomatol Med Dent Cir Maxilofac.* 2005;46:13-9.
20. Branstetter BF, Weissman, Kaplan SB. Imaging of a Stafne bone cavity: what MR adds and why a new name is needed. *Am J Neuroradiol.* 1999;20:587-9.
21. Kursoglu P, Ari N, Calikkocaoglu S. Use of Stafne's mandibular defect in improving retention of mandibular complete dentures. *N Y State Dent J.* 2007;73:52-4.
22. Simpson W. A Stafne's mandibular defect containing a pleomorphic adenoma. *J Oral Surg.* 1965;23:553-6.