

## Revista Española de Cirugía Ortopédica y Traumatología

www.elsevier.es/rot



### ORIGINAL ARTICLE

# Lack of correlation between plantar arthrosis of the first metatarsal joint and sesamoids and pain in patients after *hallux valgus* surgery<sup>☆</sup>

C. Villas, R.J. Escribano\*, M. Alfonso

Departamento de Cirugía Ortopédica y Traumatología, Clínica Universidad de Navarra, Pamplona, Spain

Received 26 June 2011; accepted 3 October 2011

#### KEYWORDS

*Hallux valgus*;  
Arthrosis;  
Sesamoids

#### PALABRAS CLAVE

*Hallux valgus*;  
Artrosis;  
Sesamoideos

#### Abstract

**Objectives:** To determine the relationship between osteoarthritis in the plantar region of the first metatarsophalangeal joint of the foot and patient pain after *hallux valgus* surgery.

**Material and methods:** A total of 28 patients undergoing *hallux valgus* surgery were examined. The patients were examined for pain in the plantar region of the metatarsophalangeal joint (sesamoid bones area), by looking into their medical records and by means of palpation during the physical exam. X-rays were taken to look for metatarsophalangeal arthritis, and PASA and sesamoid displacement were measured. During the surgical procedure, the metatarsal head was macroscopically assessed for arthritis according to the ICRS Score.

**Results:** Of the 28 patients, 18 had no pain, 7 had mild pain (VAS 1–3) and 3 had moderate pain (VAS 4–6). Macroscopically, all the patients had some degree of plantar osteoarthritis. Only 5 patients had radiological signs of metatarsophalangeal arthritis. There was no correlation ( $P=0.44$ ) between pain and plantar osteoarthritis. There was a mild but non-significant correlation between PASA and osteoarthritis ( $P=0.06$ ). There was a weak but significant correlation between patient age and arthritis ( $P=0.04$ ).

**Conclusion:** Osteoarthritis in the plantar aspect of the first metatarsal head does not correlate with patient symptoms or with pain intensity in patients undergoing *hallux valgus* surgery.

© 2011 SECOT. Published by Elsevier España, S.L. All rights reserved.

#### Falta de correlación entre artrosis plantar del primer metatarsiano y sesamoideos y dolor en pacientes intervenidos de *hallux valgus*

#### Resumen

**Objetivos:** Valorar la aparición de artrosis en la zona plantar de la primera articulación metatarsal (primera MTTF) en pacientes operados de *hallux valgus* y correlacionarla con la existencia de dolor preoperatorio.

<sup>☆</sup> Please cite this article as: Gómez Fernández JM, et al. Ausencia congénita unilateral del escafoides carpiano y displasia del hueso grande. A propósito de un caso. Rev esp cir ortop traumatol. 2012;56(2):115–9.

\* Corresponding author.

E-mail address: [ricardoescri@gmail.com](mailto:ricardoescri@gmail.com) (R.J. Escribano).

**Material y métodos:** Se valoraron 28 pacientes a intervenir de *hallux valgus* mediante osteotomía en «Scarf». Se observó si presentaban dolor en la zona plantar de la primera MTTF (área de los sesamoideos) en la anamnesis y la exploración. Se buscaron signos radiográficos de artrosis metatarsofalángica y se midieron el PASA preoperatorio y el grado de desplazamiento del metatarsiano respecto al sesamoideo medial. En la intervención se observó el grado de artrosis de la cabeza del primer metatarsiano y se valoró por la escala ICRS.

**Resultados:** Dieciocho pacientes no tenían dolor, 7 tenían dolor leve (EVA 1–3) y 3 moderado (EVA 4–6). Macroscópicamente todos los pacientes presentaban artrosis en la cara plantar del primer metatarsiano. En las radiografías solo 5 pacientes mostraban signos de artrosis metatarsofalángica. No hubo correlación significativa ( $p=0,44$ ) entre dolor y artrosis plantar del primer metatarsiano. Se observó cierta relación entre aumento del PASA y mayor grado de artrosis, pero no se encontraron diferencias significativas ( $p=0,06$ ). Se encontró una correlación débil, pero significativa ( $p=0,04$ ) entre la edad de los pacientes y la artrosis del primer metatarsiano.

**Conclusión:** La artrosis en la articulación de la cabeza del primer MTT con los sesamoideos no se corresponde con la existencia de síntomas o la intensidad del dolor en esa zona en pacientes con *hallux valgus*.

© 2011 SECOT. Publicado por Elsevier España, S.L. Todos los derechos reservados.

## Introduction

*Hallux valgus* is one of the most common problems in foot pathology, causing pain and function limitation in many patients and often requiring surgery to correct it.<sup>1–3</sup> The deformity produced in the first metatarsophalangeal joint can only be corrected satisfactorily by an operation and, in fact, there are more than 200 techniques described for correcting it, whether by acting on the bone or on the soft tissues.<sup>4–6</sup>

Within the physiopathology of *hallux valgus*, several known phenomena have been described, such as the retraction of the hallux flexor and abductor, as well as dislocation with respect to the sesamoid bones caused by the deviation of the first metatarsus. It has been proposed that these mechanisms tend to perpetuate the deformity and can, in the long run, influence the appearance of osteoarthritis in the first metatarsus. Other influential factors in the appearance of osteoarthritis could be caused by increased mobility of the first ray, the relative position of the metatarsals or by their relative position due to the deformity.<sup>4,7,8</sup> First metatarsus osteoarthritis contributes to the appearance of pain in these patients.

In *hallux valgus* surgery, osteoarthritis normally appears in the joint section of the head of the first metatarsal and in the zone of what is called the ‘bunion’. In our experience, we have also observed various degrees of chondral ulcers in the plantar region of the head, in the area of articulation with the sesamoid bones, during these operations. Various authors have associated the appearance of these chondral lesions to factors as different as what is improperly called sesamoid bone deviation (the bone that is deviated is the first metatarsal) or the change in the distribution of pressure on the first metatarsal head when it shifts in the valgus direction and rotates. Other authors have tried to relate the chondral lesions under the first metatarsal head with different radiological parameters.<sup>9</sup> Although such chondral lesions are well described in some studies in

the literature,<sup>9–13</sup> hardly any attention has been given to whether this osteoarthritis is related to patient pain. Consequently, the relation that there could be between the degree of osteoarthritis under the first metatarsal head and the patient’s clinical symptoms and the prognosis of *hallux valgus* surgery is not well known.

## Material and methods

We took a transversal sample from 28 patients to be operated on for *hallux valgus* correction in our centre. All of the patients were assessed in consultation before the surgery. The appearance of pain upon palpating under the first metatarsal head during this examination was evaluated, using a visual analogue scale (VAS). All of the patients presented an intermetatarsal angle greater than 15° in the preoperative radiographs.

Immediately after beginning the anaesthetic procedure, the patients were again asked about the appearance of pain under the first metatarsal head, exploring whether pain appeared when this area was palpated. The same surgeons operated on all of the patients, using the same technique. We corrected the deformity in all of the patients by scarf osteotomy stabilised with 2 screws. A medial approach was performed at the first metatarsal. When the first metatarsal head was exposed, we evaluated the state of the cartilage in the plantar and classified it according to the International Cartilage Research Society (ICRS) scale.

In the consultation, we took anteroposterior and lateral preoperative radiographs of the foot to operate in the load position. The type of foot was then determined from these images based on the length of the first metatarsal with respect to the second. We also assessed the proximal articular set angle [PASA]). In 2 cases, we could not recover the perioperative radiographs to calculate the PASA, so 26 patients were analysed. In addition, we evaluated the relative sesamoid position based on the abbreviated classification proposed by Malabar,<sup>4</sup> which separates 5 degrees

**Table 1** Relationship between the grades of intraoperative osteoarthritis found, based on the International Cartilage Research Society (ICRS) scale, and the pain the patients had, based on the analogical visual scale (AVS).

Pain	AVS 0	AVS 1–3	AVS 4–6	AVS >7	Total
<i>Osteoarthritis</i>					
1	5	2	0	0	7
2	2	2	1	0	5
3	7	0	1	0	8
4	4	3	1	0	8
Total	18	7	3	0	28

according to the ratio of the medial sesamoid with the first metatarsal axis. Likewise, we recorded any signs of degeneration in the metatarsophalangeal joint as present or absent.

Statistical analysis was performed with the SPSS 14.0 using Pearson's correlation coefficient, and the Chi square test for variables grouped in categories. A significance level of  $P < 0.05$  was used.

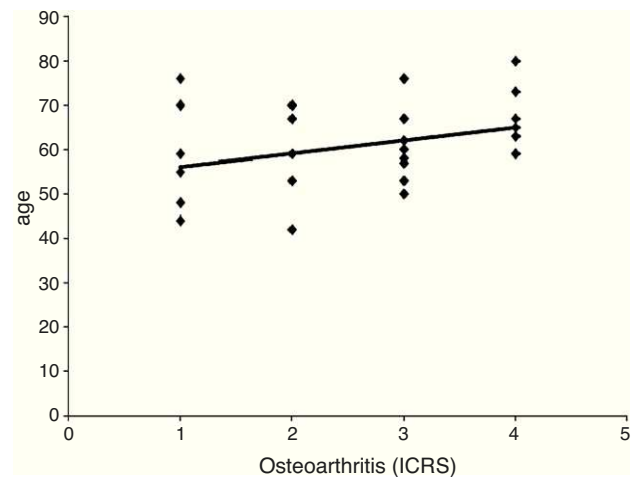
## Results

We assessed 28 feet from 27 patients, 2 males and 25 females. Of the total, 11 were left feet and 17, right. In 21 cases, the toe formula was index minus, in 2 cases it was index plus and in 5 cases it was index plus minus. The mean age of the patients was 60.8 years (minimum: 42; maximum: 80).

In the case histories, none of the patients reported pain in the first metatarsal support area just before surgery. Upon examination, 18 of the 28 feet operated were asymptomatic (analogical visual scale [AVS] = 0), the pain was slight (AVS = 1–3) in 7 cases and moderate (AVS = 4–6) in 3. With respect to cartilage integrity in the area of articulation with the sesamoid bones, 7 feet had Grade 1 damage, 5 patients had Grade 2 lesions, 8 had Grade 3 and 8 patients presented Grade 4. Only 5 patients had radiological signs of moderate or severe metatarsophalangeal osteoarthritis. The patients with radiographic signs of osteoarthritic damage showed macroscopic cartilage damage of Outerbridge Grade 4 on assessing the articulations during the operation.

No significant correlation was found between the osteoarthritis lesions in the first metatarsal and the pain the patients presented (Table 1). The 3 cases of moderate pain (the highest AVS scores registered, 4–7) had Grades 2, 3 and 4 damage in the 3 feet, respectively. Among the 18 asymptomatic patients, 5 had Grade 1 lesions, 2 had Grade 2, 7 of them had Grade 3 damage and 4 had Grade 4 damage.

We found a weak, but significant, positive correlation between patient age and degree of intraoperative osteoarthritis found ( $r = 0.398$ ;  $P = 0.04$ ) (Fig. 1). Combining the patients in age groups, no significant differences were found between the groups. However, in the groups of older patients (60s–70s), the proportion of patients with a greater degree of first metatarsal osteoarthritis was higher. In the 60–70 group, 6 of the 10 patients had Grade 3–4; in those older than 70 (4 patients), 2 had Grade 4 osteoarthritis and 1, Grade 3 (Table 2).



**Figure 1** Graph showing the correlation between patient age and osteoarthritis grade. The value of the correlation coefficient is  $r = 0.398$  with  $P = 0.04$ .

**Table 2** Relationship between the intraoperative osteoarthritis grade found, according to the ICRS scale, and patient age.

Age	40–50	50–60	60–70	>70	Total
<i>Osteoarthritis</i>					
I	3	2	1	1	7
II	1	2	2	0	5
III	0	4	3	1	8
IV	0	2	4	2	8
Total	4	10	10	4	28

We did not find any correlation or significant differences with osteoarthritis grade and degree of displacement relative to the sesamoids ( $P = 0.3$ ), or for the preoperative PASA ( $P = 0.06$ ).

## Discussion

One of the aspects related to the deformities produced by *hallux valgus* is the appearance of osteoarthritis under the first metatarsal head. Ito et al.<sup>7</sup> observed the radiographs of patients having osteoarthritis of the first metatarsal and *hallux valgus*, comparing them with controls having only *hallux valgus*; they found variations in the length and adduct displacement of the metatarsals in the first group. Aseyo et al.<sup>14</sup> studied the morphology of the relation between the medial sesamoid and the plantar face of the first metatarsal head in patients with *hallux valgus*. They found osteoarthritis in up to 32% of the patients, and a greater relationship between the degree of deformity and the degree of osteoarthritis. Some authors have speculated, even though only theoretically, about the possibility of early corrective surgery for *hallux valgus*, to prevent the dislocation of the first metatarsal with respect to the sesamoid bones and the consequent appearance of osteoarthritis.<sup>9</sup>

In our study, we found no correlation between the osteoarthritis under the first metatarsal head and the pain the patients reported in that area. Cho et al.<sup>15</sup> found an associated between patient pain and degree of deformity in epidemiological studies, although they did not assess the degree of osteoarthritis macroscopically. Some authors

found that the patients with osteoarthritis in the preoperative radiograph obtained worse medium-term clinical results. Largey et al.<sup>13</sup> did attempt to correlate the degree of metatarsal displacement with osteoarthritis in the plantar face of the first metatarsal and patient pain, measured by means of questionnaires. In our case, we tried to assess patient pain by looking directly at the location of the pain during the physical examination. Most of the patients experienced pain attributable to bursitis in the medial face of the first metatarsal head (what is called a bunion). Other patients gave more weight to the central ray overload or Morton syndrome concomitant with their *hallux valgus* and did not complain of discomfort under the first metatarsal head. This has also been reported by other authors.<sup>16</sup> On the other hand, Lui et al.<sup>17</sup> performed arthroscopy on the metatarsophalangeal joint in 121 patients, finding osteoarthritis to a greater or lesser degree in all of the patients, as well as joint synovitis. The author indicated that 90% of the patients improved after synovectomy in the same operation. This would mean that the cartilage was not directly responsible for the pain, at least in those cases.

The influence of sesamoid position in the deformity produced in *hallux valgus* has frequently been studied. Although the classification systems described<sup>4</sup> confirm the position of the sesamoids with the first metatarsal, it is known that it is the latter that, as it is displaced in varus, loses its natural relationship with the sesamoids while they remain in their place. Some authors, having studied the appearance of osteoarthritis related to first metatarsal displacement with respect to the sesamoid bones,<sup>13</sup> proposed various techniques aimed at recovering the original relationship between the first metatarsal and the sesamoids. In our case, we did not find a special relationship between the degree of metatarsal osteoarthritis and first metatarsal displacement with respect to the sesamoid bones.

The presence of osteoarthritis under the first metatarsal head seems to correlate with patient age, which is logical: the older the patient, the greater the probability of developing degenerative joint changes, including in the toes. In our study, this relationship was statistically significant, although with only a weak correlation. Taking a population with a wide age range helped assess the appearance of osteoarthritis in different stages of life, although *a priori* it could appear to be a study limitation from using an apparently divergent population. With respect to the relationship between PASA and the degree of postoperative osteoarthritis, we did not find any statistically significant differences. However, when the patients were grouped, the proportion of osteoarthritic changes was greater in the patients having the most increased PASA. Thordarson et al.<sup>18</sup> did not find any differences between the degree of *hallux valgus* deformity and the clinical results of the patients. Other authors have found greater osteoarthritis in the metatarsals with the most elevated PASA levels.<sup>9,11,19</sup>

The absence of pain in these patients makes us reconsider the need for early correction of the *hallux valgus* deformity to prevent the appearance of osteoarthritis, as well as the need to obtain total congruence of the plantar sesamoid bones with the first metatarsal head. Given that the patients do not report any pain, it makes no sense to spend surgery time and efforts re-establishing this sesamoid-first metatarsal congruence, possibly adding

greater morbidity during the operation. We also feel that it is not necessary to worry about preventing the development of osteoarthritis under the first metatarsal head. Even when this appears in our patients, it does not cause any complaints in the initial consult or in the perioperative period. It is important to emphasise that, although pain under the first metatarsal head is not a clinically important factor (so it is not necessary to take direct action on it), it is still essential to obtain the appropriate correction of the deformity to prevent its reoccurrence.

A limitation of this study is that the correlation between the pain and the osteoarthritis was performed transversally over time. Our goal was to establish if there could be a relationship between patient clinical signs and symptoms and the discovery of osteoarthritis that we found at the specific moment of surgery. It would be of interest to assess whether patients present pain under the first metatarsal head during their postoperative evolution. We are carrying out a prospective follow-up of these patients to provide these data in a future article.

## Ethical disclosures

**Protection of human and animal subjects.** The authors declare that no experiments were performed on humans or animals for this investigation.

**Confidentiality of Data.** The authors will declare that they have followed the protocols of their work centre on the publication of patient data and that all the patients included in the study have received sufficient information and have given their informed consent in writing to participate in that study.

**Right to privacy and informed consent.** The authors must have obtained the informed consent of the patients and/or subjects mentioned in the article. The author for correspondence must be in possession of this document.

## Level of evidence

Level of evidence IV: transversal study.

## Conflict of interests

The authors have no conflict of interests to declare.

## References

1. Gilheany MF, Landorf KB, Robinson P. Hallux valgus and hallux rigidus: a comparison of impact on health-related quality of life in patients presenting to foot surgeons in Australia. *J Foot Ankle Res.* 2008;11:1–14.
2. Coughlin MJ, Jones CP. Hallux valgus: demographics, etiology, and radiographic assessment. *Foot Ankle Int.* 2007;28:759–77.
3. Abhishek A, Roddy E, Zhang W, Doherty M. Are hallux valgus and big toe pain associated with impaired quality of life? A cross-sectional study. *Osteoarthritis Cartilage.* 2010;18:923–6.
4. De Prado M. Hallux valgus. In: De Prado M, Ripoll PL, Golano P, editors. *Cirugía percutánea del pie*. Barcelona: Masson; 2003. p. 57–98.
5. Ferrari J, Higgins JP, Prior TD. Interventions for treating *hallux valgus (abductovalgus)* and bunions. *Cochrane Database Syst Rev.* 2009;15:CD000964.

6. Ford LA, Hamilton GA. Procedure selection for hallux valgus. *Clin Podiatr Med Surg.* 2009;26:395–407.
7. Ito K, Tanaka Y, Takakura Y. Degenerative osteoarthritis of tarsometatarsal joints in hallux valgus: a radiographic study. *J Orthop Sci.* 2003;8:629–34.
8. Myerson MS, Badekas A. Hypermobility of the first ray. *Foot Ankle Clin.* 2000;5:469–84.
9. Roukis T, Lowell Jr S, Lowell Sr S, Landsman A. Predicting articular erosion in hallux valgus: clinical, radiographic and intraoperative analysis. *J Foot Ankle Surg.* 2005;44:13–21.
10. Haines WRW, Mc Dugall A. The anatomy of hallux valgus. *J Bone Joint Surg.* 1954;36-B:272–93.
11. Breslauer C, Cohen M. Effect of proximal articular set angle correcting osteotomies on the hallucal sesamoid apparatus: a cadaveric and radiographic investigation. *J Foot Ankle Surg.* 2001;40:336–73.
12. Smith RW, Reynolds JC, Stewart MJ. Hallux valgus assessment: report of the research committee of american orthopaedic foot and ankle society. *Foot Ankle.* 1984;5:92–103.
13. Largey A, Canovas F, Roussanne Y, Hebrard W, Bonnel F. Degenerative cartilage changes in metatarsosesamoidal joint and Scarf procedure results for hallux valgus: a prospective study of 100 cases. *Rev Chir Orthop.* 2008;94:685–92.
14. Aseyo D, Nathan H. Hallux sesamoid bones. Anatomical observations with special reference to osteoarthritis and hallux valgus. *Int Orthop.* 1984;8:67–73.
15. Cho NH, Kim S, Kwon DJ, Kim HA. The prevalence of hallux valgus and its association with foot pain and function in a rural Korean community. *J Bone Joint Surg.* 2009;91-B:494–8.
16. Wang X, Jiang JY, Ma X, Huang JZ, Gu XJ. Management of the second and third metatarsal in moderate and severe hallux valgus. *Orthopedics.* 2009;32:892–6.
17. Lui TH. First metatarsophalangeal joint arthroscopy in patients with hallux valgus. *Arthroscopy.* 2008;24:1122–9.
18. Thordarson D, Ebrahimzadeh E, Moorthy M, Lee J, Rudicel S. Correlation of hallux valgus surgical outcome with AOFAS forefoot score and radiological parameters. *Foot Ankle Int.* 2005;26:122–7.
19. Fuhrmann RA, Zollinger-Kies H, Kundert HP. Mid-term results of scarf osteotomy in hallux valgus. *Int Orthop.* 2010;981–9.