

# Metacarpal Hand Reconstruction by Combined Second and Third Toe Transfer

F. del Piñal, F.J. García-Bernal, J. Delgado, M. Sanmartín, J. Regalado and C. Santamaría

Dr. Piñal & Associates, Institute for Plastic and Hand Surgery and Mutua Montañesa Hospital. Santander.

**Introduction.** Multidigital amputations are a formidable challenge for the surgeon. In the case of amputations near the digital commissure the best reconstruction can be achieved using a combined flap of the 2nd and 3rd toes. The aim of this study is to present the functional results achieved in 5 patients who underwent combined 2nd and 3rd toe transplants to rehabilitate severely mutilated hands.

**Materials and methods.** Since 1995 we performed 95 toe-to-hand transplants with a survival rate of 94/95. Five patients (ages 21–53 years) that had suffered amputations of 5 fingers (3 cases), and 4 fingers (2 cases), underwent 2nd and 3rd toe flap combined transplants. All were operated on during the acute or subacute phase. Four of the patients that had suffered a thumb amputation underwent reconstruction by means of a big toe transplant in 3 cases and emergency ectopic middle toe reimplantation in 1 case. Thumb reconstruction was considered a priority and performed one week before the toe flap tandem transplants.

**Results.** All the transplants survived. Minimum postoperative followup was 6 months. In all cases at least one stable tripod pincer grasp was achieved. As to the foot, there were no cases of toe crossover, permanent pain during gait or manifest functional impairment. The objective survey on cosmetic sequelae revealed that these were important to us but not so important for the patients. The patients would all choose to undergo the operation again and would advise other patients in the same situation to have this type of surgery.

**Conclusions.** The complexity involved in the reconstruction of a metacarpal hand implies consideration of such issues as the position and number of toes to be transplanted and the management of associated tissue loss and blood supply. The

combined transplant of the 2nd and 3rd toes allows recovery of a tripod pincer grasp and results in a high degree of patient satisfaction. The greater cosmetic sequelae are offset, in our opinion, by the greater pincer grasp stability. This type of surgery is recommended for patients that have suffered amputations of three fingers with three phalanges proximal to the commissural fold.

**Key words:** multidigital amputation, toe-to-hand, metacarpal hand.

## Transferencias del segundo y tercer dedo del pie en tándem para reconstrucción de la mano metacarpiana

**Introducción.** Las amputaciones multidigitales representan un auténtico desafío para el cirujano. En amputaciones proximales al pliegue comisural, el método óptimo de reconstrucción es un colgajo combinado de segundo y tercer dedos del pie. El objetivo de este trabajo es presentar los resultados funcionales conseguidos en cinco pacientes, los cuales recibieron transferencias del segundo y tercer dedo del pie en tándem para rehabilitar mutilaciones graves de la mano.

**Material y método.** Desde 1995 hemos realizado 95 transferencias de dedos del pie a la mano con una supervivencia de 94/95. Cinco pacientes de edades comprendidas entre los 21 y 53 años, que habían sufrido amputaciones de 5 dedos (3 casos) y 4 dedos (2 casos), fueron tratados mediante la transferencia de un colgajo combinado de segundo y tercer dedo en tándem. Todos fueron intervenidos en fase aguda o subaguda. Cuatro de ellos habían sufrido la amputación del pulgar, cuya reconstrucción se realizó mediante trasplante de dedo gordo del pie en los tres casos y con reimplante ectópico del dedo medio (de urgencia) en un caso. La reconstrucción del pulgar primó sobre las otras y se hizo una semana antes que la de los dedos con el colgajo tándem.

**Resultados.** Todos los trasplantes sobrevivieron. El seguimiento mínimo fue de seis meses tras la operación. En to-

Corresponding author:

F. del Piñal.  
C/ Calderón de la Barca 16-entlo.  
39002 Santander.  
E-mail: drpinal@drpinal.com

Received: January 2005.  
Accepted: November 2005

dos los casos se consiguió, al menos, una pinza trípode estable. En el pie no hubo casos de entrecruzamiento, dolor permanente en la marcha o déficit funcionales manifiestos. La encuesta sobre la secuela estética objetiva revela que ésta es importante para nosotros, pero no tanto para el enfermo. Todos repetirían y aconsejarían la misma a otros enfermos que se encontrasen en igual situación.

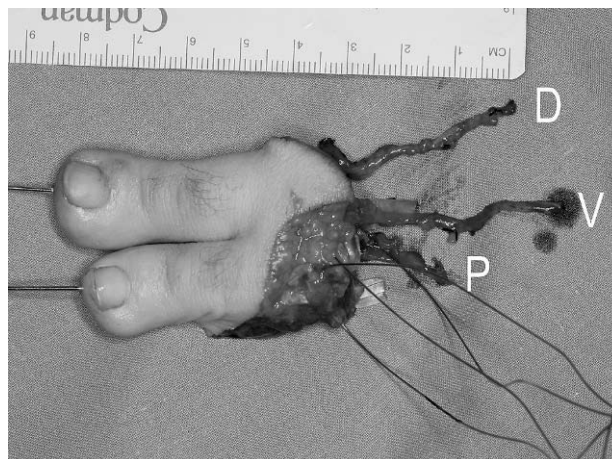
**Conclusión.** La complejidad de la reconstrucción de la mano metacarpiana implica consideraciones en la posición y número de dedos transferidos, en el manejo de la pérdida de sustancia asociada y en la gestión de vasos receptores. La transferencia combinada del segundo y tercer dedo permite la recuperación de la pinza trípode y un alto grado de satisfacción de los pacientes. La secuela, estéticamente mayor, es compensada en nuestra opinión por la mayor estabilidad en la prensión y en la pinza. La intervención es recomendable para pacientes que hayan sufrido amputaciones de tres dedos trifalángicos proximales al pliegue comisural.

**Palabras clave:** amputación multidigital, dedo de pie a mano, mano metacarpiana.

The management of multiple finger amputations is complex and is undoubtedly one of the most difficult challenges posed by the treatment of the «traumatic hand». One must avail oneself of classical techniques (flaps, tendinous transfers, lengthening, etc.) and others that are not so avant-garde anymore like toe transfers or free flaps.

What can be achieved in the severely mutilated hand by means of toe transfers goes far beyond the possibilities of classical techniques (basic grip and object grasping functions)<sup>1,2</sup>. Toes make it possible to increase the grip diameter and therefore make it possible for the patient to hold larger objects; they also provide sensitivity and the ability to grip smaller objects.

Although having a toe on each end of the grip is an achievement vis-à-vis conventional methods, most authors consider that the goal should not be a basic grip but rather a tripod grip, in which at least two fingers are confronted with the thumb, giving rise to a stronger and more stable grip and pinch.



**Figure 1.** Combined second and third digit flap. D: first dorsal intermetatarsal; P: second plantar intermetatarsal; V: dorsal subcutaneous vein.

The second and third toe tandem flap was introduced with the aim of enabling severely mutilated hands to perform a tripod grip<sup>3-5</sup>. After an initial teething period during which the donor site sequelae were minimized and indications defined, the tandem flap is nowadays considered the best reconstruction method for multiple finger amputations proximal to the commissural fold<sup>6-10</sup> (Fig. 1).

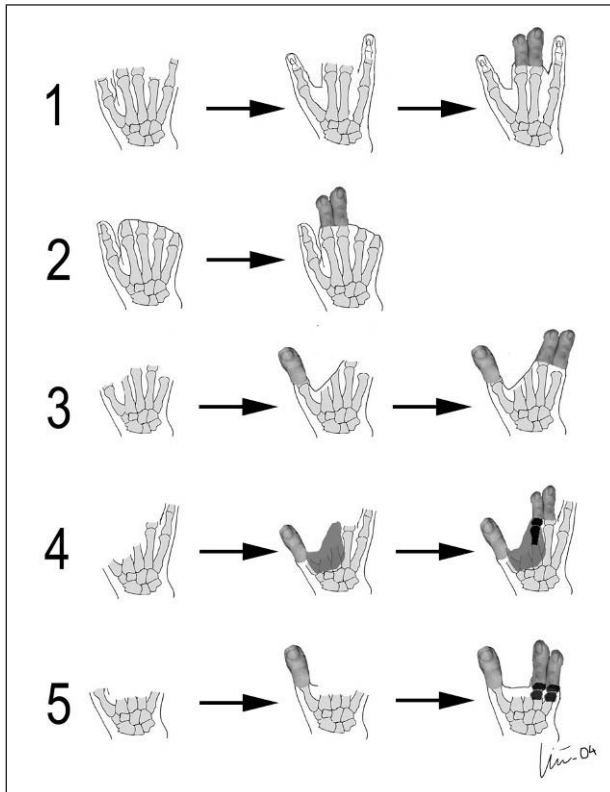
The goal of this paper is to present the results of our experience in 5 consecutive patients with severely mutilated hands, in whom we performed a tandem flap transfer.

## MATERIALS AND METHODS

Between February 1995 and November 2004 we performed 95 toe transfers to the hand, with a survival of 94/95. The series includes 5 cases of combined second and third-toe transfer, which are the purpose of this paper (Table 1). All patients in this group had suffered severe hand mutilations: 3 patients had undergone amputation of 5 digits and 2 had lost 4 (one of these preserved the thumb and the other a portion of the little finger). The hand involved was the dominant one in 4 cases. In all cases the injuries were sus-

**Table 1.** Characteristics of five patients subjected to tandem transfers of the second and third toe

	Case 1	Case 2	Case 3	Case 4	Case 5
Age	29	30	21	31	53
Side	Dominant	Dominant	Non-dominant	Dominant	Dominant
Classification	III A	I A	III A	II	III B
Emergency treatment	Reimplantation 4 to 1, 3 to 5	Remodelling	Remodelling	Desbridement	Remodelling
Position	3-4(-2)	2-3	4-5	3-4	4-5
Associated flap	–	–	<i>Dorsalis pedis</i> Fasciosubcutaneous	<i>Gracilis</i>	<i>Dorsalis pedis</i> Fasciosubcutaneous
Follow-up (months)	41	30	19	9	7



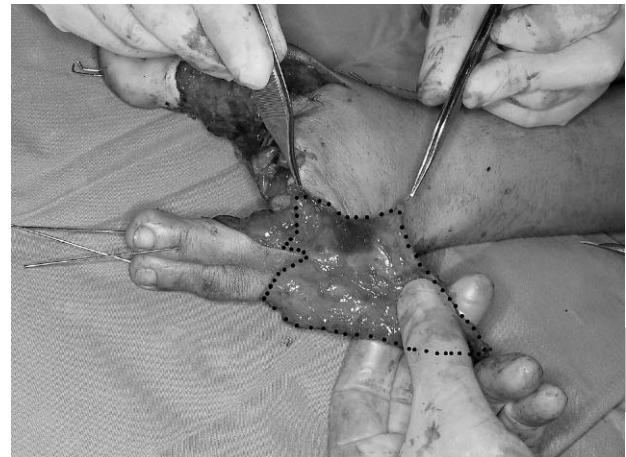**Figure 2.** Schematic representation of the defects and their reconstruction (from top to bottom cases 1 to 5). The intermediate step corresponds to the transfer of the newly formed thumb (cases 3, 4 and 5) or to ectopic reimplantations (case 1). In all cases, the second transfer was carried out a week after the big toe transplant.

tained in the workplace: two patients were maintenance mechanics, two were operators of press-like machine and the fifth was a butcher (Fig. 2).

We have classified lesions into three groups. Type I: All triphalangeal fingers are missing; type II: The radial digits are missing, including the thumb, only one finger on the ulnar side being present and type III: all digits, including the thumb, are missing. These categories are in turn subdivided into subclasses A-D depending on the degree of thumb amputation.

Two patients were seen in the emergency setting. In one patient, who had a crush-avulsion of the five digits (case 1), it was possible to reimplant a small segment of the middle finger in the thumb position and the ring finger in the little finger position. The other (case 4) had had his hand trapped in a thermal sealing press and, except for a portion of the little finger, had suffered a deep burn involving the intrinsic and metacarpals. In these two patients, after an emergency debridement we started reconstruction 72 hours later. The other three patients were referred to us for an assessment between 3 and 5 weeks after the accident.

The most severe lesions (types II and III) were associated to the loss of concomitant substance and had to be ad-



**Figure 3.** Tandem flap with fasciosubcutaneous extension (dotted) to cover moderate defects.

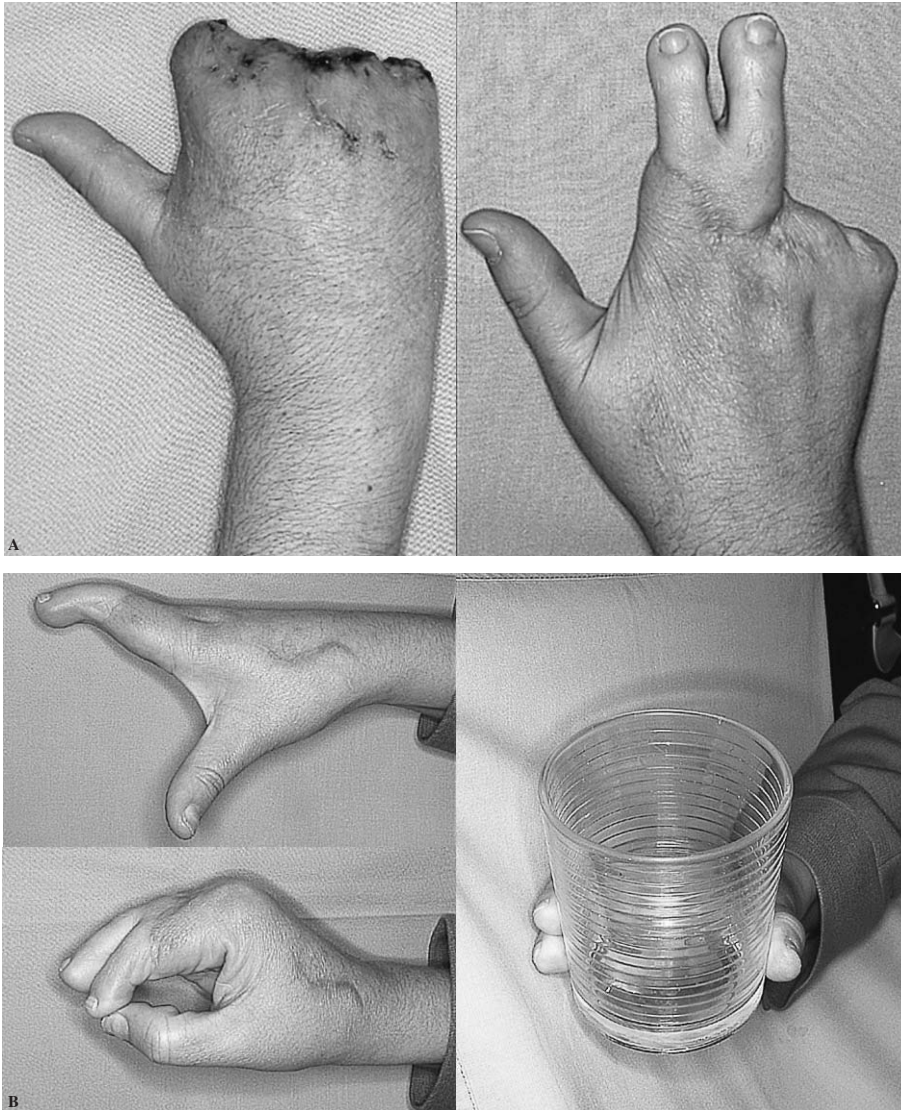
ressed by means of additional procedures. One case of massive substance loss required a free gracilis muscle flap, which was transferred in the same surgical session as thumb reconstruction. In the other two cases (cases 3 and 5) we addressed the defects by means of fasciosubcutaneous flaps of the dorsum of the foot associated to the toe<sup>11</sup> (Fig. 3).

The flap raising technique has been described in the literature<sup>3-6</sup>. We have added the possibility to include a fasciosubcutaneous section that eliminates the need of additional skin flaps<sup>12-14</sup> in cases of moderate substance loss<sup>11</sup>. As regards the skin included with the fingers, it never exceeded the vortex of the first and third commissures, except in two cases in which the fasciosubcutaneous extension mentioned was used. In all patients the skin was approximated with no tension and the closing of the donor site was achieved primarily. In the donor site we did not attempt to collapse the empty space by the transferred toes, nor any form of stabilization of the metatarsals or a reconstruction of the intermetatarsal ligament<sup>8</sup>. In the immediate post-op, the foot was kept elevated with a soft bandage, weight-bearing being allowed as tolerated.

Immediately before flap reperfusion, all patients were given a 1000 IU bolus of heparin. In the post-op a mixture of 500 ml of a 5% solution of dextran 40,000 was administered with 5.000 IU of heparin at a perfusion rate of 25 ml/hour (Standard dose for a patient weighing 70 kg) for 4 days. During the first 48 hours, flaps were controlled hourly by nursing staff that was familiar with microsurgery by means of a doppler probe in each finger; they assessed color and capillary filling. From the third day onwards, controls were carried out every 3 hours until the patients were discharged on the fifth day.

At the last control visit, patients were given a non-anonymous questionnaire in which they were encouraged to suggest possible improvements for the future. Patients





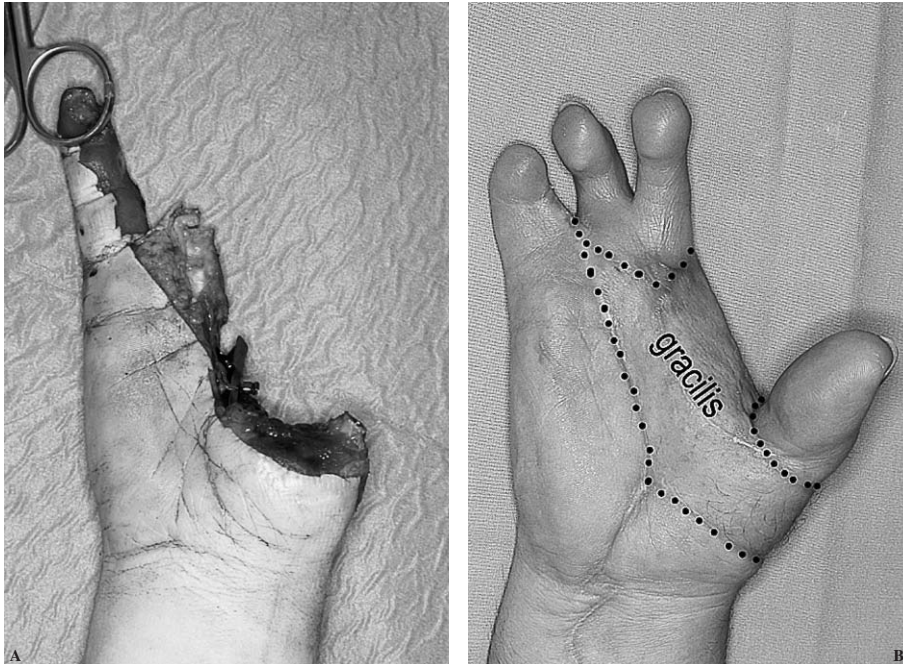
**Figure 4.** Case 2. Type I hand. View of the hand before surgery (A) and two and a half years post-op (B).

used a Visual Analog Scale (VAS) to assess functional hand and foot sequelae (no limitation, no pain = 0; disabling limitation, unbearable pain = 10) as well as esthetic ones (normal = 0; highly deformed = 10). We also assessed foot sequelae according to the AOFAS15 scale, excluding the sections dealing with mobility and digit alignment because having been transferred they were absent from the foot. Finally, they were asked whether they would undergo this surgery again and if they would recommend individuals in similar circumstances to subject themselves to it. Moreover, a group of 10 volunteers who had come to consultation for a different reason agreed to assess the foot's esthetic sequela with the same scale and rules as the patients, looking at the photos in a computer, oblivious to the reason for surgery and to the functional outcome obtained.

## RESULTS

### Transfers

The flap was based on two arteries in 4 cases and on three in one. The anastomoses were carried out either on the palm or in the ulnar region. Venous drainage was performed through a vein in the dorsum of the hand. All the nerves that were isolated in the donor flap were sutured to collaterals or commissurals as necessary. As regards tendons, the only ones that were repaired were the long flexors of the foot to the superficial flexors of the hand, in order to achieve independent function. All flaps had a 100% survival rate (Figs. 4-6). Two patients had to be re-explored because there were signs of artery failure, at 12 and 48 hours respectively. In the first case (case 1) a hematoma on the palm was detected which had obstructed the anastomoses. In the second, one



**Figure 5.** Case 4. Type II hand. A: after debridement. B: result after a gracilis flap and a toe transplanted in a single stage, and a combined second and third-digit flap a week after transplantation.

of the digits showed signs of hypovascularization given the sheer length of the artery. After cutting off the redundant artery, a second anastomosis was performed and the digit was reperfused with no further complications.

### On the hand's function

All patients, except for case 4, achieved the goal of obtaining a stable and independent grip (cases 1, 2, 3 and 5), with a maximum grip span of 9.6 cm on average and a grip strength of 12.4 kg on average (Table 1). Patient is due to be subjected to a few capsulotomies in order to try and improve the mobility of the transplanted digits and of the fifth finger. The mobility restrictions in the autologous metacarpophalangeals is probable due to greater damage than initially foreseen, influenced by the need to preserve at all costs the metacarpophalangeals of the forth and fifth digits (Table 2).

All patients consider their hand to be useful or very useful. Objective records of strength and grip are a far cry from the parameters of the healthy hand (38% on average). Records of sensitivity are even lower, especially in patients with a short follow-up (discrimination of two points: 7-13 mm).

### On the donor sequela

In all cases the donor defect was closed primarily. Three patients who had undergone a double transfer of a big toe and, a week later, a combined transfer of the second and third toes, assessed the discomfort and limitations on both feet. Patient 3 reported that he had no trouble, except when

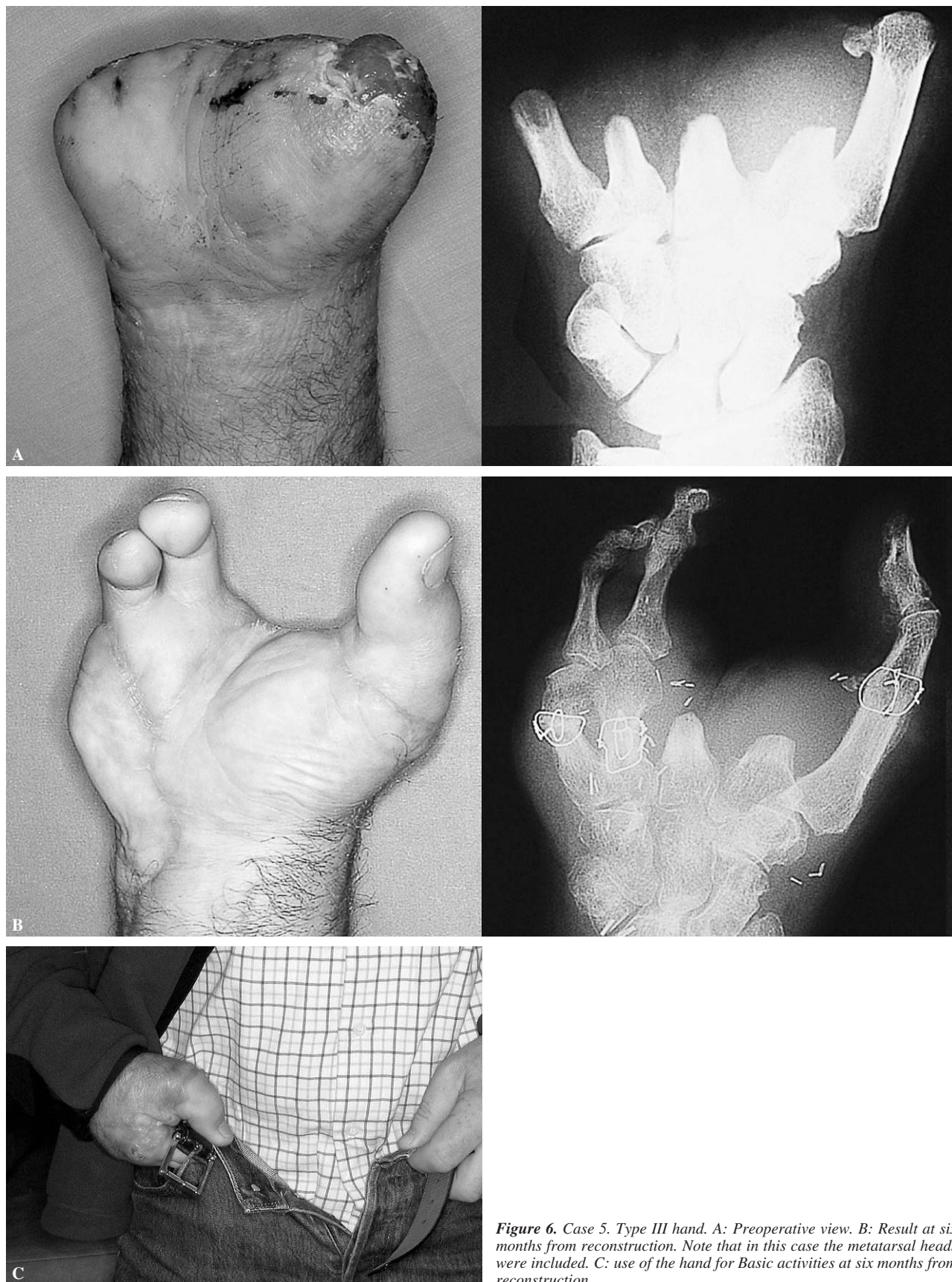
he stood on tiptoe because the foot where the bid toe was missing failed him. Patient 4 felt greater discomfort in the foot with a tandem flap, whereas patient 5 initially had more trouble in the foot where the big toe had been excised, although now he feels the same degree of discomfort on both feet and reports fatigue on walking several kilometers. The general evaluation of the foot where the tandem flap was taken as regards pain on walking was 2/10, reaching 3/10 points when long distances (1 hours) were covered and up to 3.4/10 when running was involved. Regarding esthetic appearance, the patients' assessment was 3/10 whereas that of the volunteers that participated in the study was 4.2/10. However, the patients who also had the big toe of the contralateral foot resected gave a lower score to the esthetic sequela on that foot. Lastly, the mean value on the AOFAS scale was 38 out of 65 (Table 3).

Only patient 2 returned to her job as a butcher. The others had to change jobs, although they were still manual ones: agricultural work, household chores or mechanics classes. They all considered that the transfer had been extremely useful and would recommend it to other patients (in fact patient 3 recommended the procedure to patient 5, who came from a neighboring town).

### DISCUSSION

The key to the management of the severely mutilated hand lies in the establishment of an achievable goal and in the design of a plan to attain that goal. For that reason, it is essential to analyze what exists (metacarpals, thenar emi-





**Figure 6.** Case 5. Type III hand. A: Preoperative view. B: Result at six months from reconstruction. Note that in this case the metatarsal heads were included. C: use of the hand for Basic activities at six months from reconstruction.

**Table 2.** Assessment of the reconstructed hand

HAND	Case 1	Case 2	Case 3	Case 4	Case 5
Would you recommend this surgery to others?	Yes	Yes	Yes	Yes	Yes
Maximum opening (cm)	10	10	11	9	8
Fist strength (kgf)	15	12	15	8	12
Grip strength (kgf)	5	3	4	—	2
Sensitivity (D2P) 2 <sup>nd</sup> toe	9	9	9	11	13
Sensitivity (D2P) 3 <sup>rd</sup> toe	11	7	9	7	13

**Table 3.** Assessment of the donor foot

FOOT	Case 1	Case 2	Case 3	Case 4	Case 5
Pain on walking*	1	2	1	3	3
Fatigue on walking*	2	3	2	4	4
Difficulty to run*	3	4	2	4	4
Return to sports activity	Yes	-	Yes	-	No
Esthetic assessment of foot	3	3	2	4	3
AOFAS score	37	37	47	37	32

\*Subjective data provided by patient (from 0 to 10).

nence, trapeziometacarpal joint, tendons, recipient vessels, etc.) and what you want to achieve. One should assess on the one hand the morbidity of the donor site, which will not be able to tolerate indiscriminate aggression, and on the other the patient and his/her surroundings. Each step should be carefully explained and taken with maximum security since there is no margin for error.

The goal in any reconstruction is to achieve a functional, esthetic and useful hand; we have called such a hand an “acceptable hand”<sup>16,17</sup>: a hand with three moving digits (plus the thumb) at the proximal interphalangeal joint (PIJ), with a degree of sensitivity as close to normal as possible and with a harmonic silhouette.

The notion of the “acceptable hand” is a utopia when we talk about a metacarpal or a mutilated hand. The principles, however, remained unaltered: achieving a mobile thumb and fingers that are as long as possible and restoring harmony as regards digit-length.

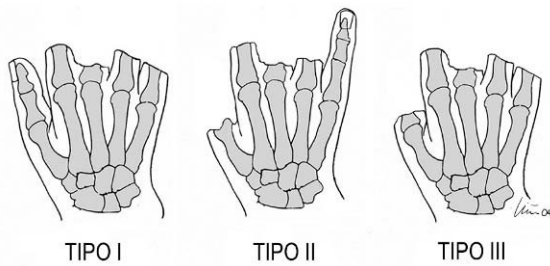
Although we all know that a metacarpal hand is the most severe aggression that a hand can suffer before amputation, authors do not seem to agree on a universal definition. We prefer that given by Michon<sup>1</sup>, who defines it as a hand that has no prehensile ability except to function as a hook. Wei<sup>7</sup> defines it as a hand where all fingers have been amputated proximal to the middle third of the proximal phalanx of the fingers. He subclassifies it into two groups: type I: the thumb is present; type II: thumb has been amputated.

Although useful, Wei’s classification<sup>7</sup>, is incomplete and inconsistent. In the first place, the term “metatarsal hand” ought to be reserved to one in which all digits, including the thumb, have been amputated (Wei’s type II). In the second place, and linked to the concept of severity men-

tioned above, it is unfair for a hand that only had one digit with no thumb not to be included in the “metacarpal hand” group and for a hand that has its thumb (Wei’s type I) to be included since the former is more disabling than the latter. For that reason, we believe a new type should be added that corresponds to toe amputations where, like in patient 4, only one digit remains, which may sometimes be partially functional.

These types of injuries are more disabling and more difficult to reconstruct than type I ones, and more often than not they are associated with coverage losses that must be resolved. That is why we suggest a three-group classification of the metacarpal hand: I (thumb is present), II (only one triphalangeal digit remains), and type III (all digits have been amputated) (Fig. 7). In this way, any severely mutilated hand could be included in the term «metacarpal hand», which conceptually denotes a very severe injury.

Classically, the goal in rehabilitating a metacarpal hand has been to achieve a grip<sup>1,2</sup>. The introduction of the toe within the reconstructing alternatives made it possible to exceed by far those expectations: longer digits were achieved that were more sensitive and could hold larger objects. In an attempt to increase grip length, Morrison<sup>18</sup> recommended to transplant the ring finger of the healthy hand to the annular-finger position. Although long-term results are spectacular, we have not come across – except for one pediatric case published by Büchler<sup>19</sup>, any other surgeon or team that has indicated the transfer of a healthy ring finger to a metacarpal hand. Most authors try to achieve a tripod grip using digits from the foot; what tells them apart is the way in which they do it. Foucher<sup>20</sup> considers that the tandem flap should never be an indication because of the sequelae to the



**Figure 7.** Classification of the different types of metacarpal hand, according to the authors of this paper.

donor site and prefers to transplant a toe from each foot. When the thumb is also missing, i.e. the true metacarpal hand, this author prefers to achieve a basic grip (with one toe from each foot) or uses a prosthesis<sup>21</sup>. In children, Kay<sup>22</sup> considers sequelae in the foot unacceptable and even if he does not hesitate to transplant two toes at the same time, he only takes one additional toe from each foot to limit morbidity in the donor site. El-Gammal<sup>23</sup>, however, has not found significant problems in children and recommends a tandem flap for the metacarpal hand. On the other end of the spectrum, there are authors who do not hesitate to transplant three toes (1-3) in a pedicle to rehabilitate cases of bilateral metacarpal hand<sup>10</sup> or for severely mutilated hands<sup>24</sup>.

In support of Wei's recommendations<sup>7</sup>, we try to achieve a tripod grip and do not have qualms about transplanting a tandem flap to attain this goal. In our view, although on paper two second toes may seem tantamount to a tandem flap, the latter has many advantages. Firstly, digits rest on the ground and are correctly aligned<sup>25</sup>, it can be performed in a single surgical stage and during the second procedure you do not need to work on healed sections, which complicates surgery on the tendons and especially the dissection of recipient vessels. Recipient vessel management is essential in situations in which two or more flaps will be transplanted, since in these cases scar-free recipient arteries are required. Our policy is to carry out all anastomoses of the vessels irrigating the thumb on the dorsum, in the anatomical snuffbox, from end to side, leaving the palm and the dorso-ulnar area intact for the veins.

In contrast, we prefer to base tandem flaps on the intermetatarsal veins (at least in the case of the second plantar one) and connect them end-to-end to the commissural in the palm of the hand. Although all cases had at least double arterial irrigation, we had a very high reoperation rate (40%) in comparison with our global experience of toe transfers (reoperations rate around 10%). Given the small number of cases it is difficult to draw conclusions, but the Taipei group also found a higher complications rate in a review that comprised a larger number of cases<sup>26</sup>.

A careful analysis of functional cases is highly complicated and, in our opinion, not very useful since it cannot be



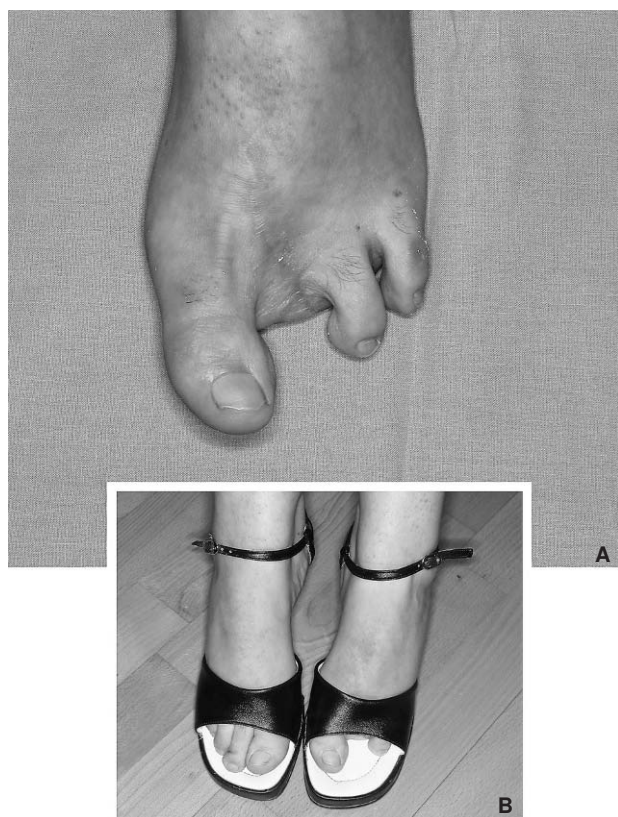**Figure 8.** Patient 4. Integration of the hand into the patient's bodily pattern (the image corresponds to the patient's wedding album, 5 months after trauma).

interpolated with other studies. Firstly, and fortunately, in developed countries the number of cases tends to be very low. Secondly, the factors influencing the results are myriad: involvement of the intrinsic musculature (cases 4 and 5), involvement of the motor structures of the forearm (patient 1 had a forearm compartmental syndrome treated as an emergency on admission and presented with all his flexors avulsed from the musculo-tendinous junction), associated thenar involvement (case 4), associated loss of substance (cases 3-5), level of amputation of the thumb and the fingers, patients' age, etc. It should be underlined that we achieved a sensitive tripod grip in all cases with a high degree of satisfaction. The alternative to toe transfer is a prosthesis, which in cases with this degree of amputation merely have an esthetic function<sup>27-30</sup>. Prostheses are expensive, there are problems matching colors and they need to be replaced every 2-3 years. We offer our patients the possibility of an esthetic orthosis, but in our setting the notion of a «plastic hand» does not appeal either to the patient or his relatives. On the other hand toes, which are short, distally bulky and ugly in general<sup>16</sup>, are warm, sensitive and are rapidly accepted by the patient and his relatives as their own (Fig. 8).

Finally, we have the donor site analysis. In the first cases donor site sequelae could outnumber the benefits of the surgery, but eventually the amount of tissue transferred came to be limited. Another factor to be taken into account is that few patients complain about donor site sequelae (Fig. 9). The fact that some patients initially reject the procedure is due to the donor site sequelae but, in our experience, the patients operated on gladly accept the exchange.

In all cases the toe transfer performed provided fully incapable hands with the capacity for large object prehension and in 4 cases we gave patients the ability to grasp small objects as well. We should mention the fact that patients use





**Figure 9.** Esthetic sequela in the foot (case 2) (A). The patient has no limitation as regards footwear or any concern relative to the deformity (B).

their hand for daily activities without hiding it from others, which is a fact that has influenced their high level of satisfaction; the sequelae on the foot were not disabling.

## ADDENDUM

From the time this paper was submitted for publication to the present (October 2006) we have reconstructed another 10 metacarpal hands (one of them being a 7-year-old child). In 4 of them, a tandem flap was used; in another, a bilateral metacarpal hand, a triple flap was used in one of the hands and a big toe plus coverage in the other. In all cases, we managed to rehabilitate the patients' grip and provide them with a certain prehension ability (similar to what was reported earlier). The global survival rate for toe transfer has not changed substantially with respect to the data of our paper, although the number of transfers is logically greater (143/141).

With respect to the donor site, the result obtained remains longer. We have not observed any subsequent changes in the cases operated. Although several authors claim that there are no sequelae when the metatarsophalangeal joints are taken with the tandem flap, the only patient that at the last examination still reported discomfort on walking several kilometers was the patient where the two metatarsophalangeals were included to reconstruct the metacarpophalangeals (case 5). For that reason, we have changed our policy and we now prefer to transplant two second toes (one from each foot) in one single surgical stage for cases requi-

ring reconstruction of both metacarpophalangeals. This policy has enabled us to minimize the esthetic and functional sequela in the foot, i.e. removing a second toe. On the other hand, the procedure is more complicated and tiresome than using a tandem flap since one must transplant two toes with their corresponding pedicles.

On the basis of our experience, we conclude that tandem flaps are indicated for mutilating hand lesions and that the result that can be expected is highly satisfactory.

## REFERENCES

1. Michon J, Dolich BH. The metacarpal hand. *Hand*. 1974;6:285-90.
2. Buck-Gramcko D. The metacarpal hand. En: Foucher G, editor. *Reconstructive surgery in hand mutilation*. London: Martin-Dunitz; 1997. p.109-19.
3. Tsai TM. 2nd & 3rd toe transplantation to a transmetacarpal amputated hand. *Ann Acad Med Singapore*. 1979;8:413-8.
4. Tsai TM, Jupiter JB, Wolff TW, Atasoy E. Reconstruction of severe transmetacarpal mutilating hand injuries by combined second and third toe transfer. *J Hand Surg Am*. 1981;6A:319-28.
5. Tsai TM. Transplantation of second and third toes to the hand (letter). *J Hand Surg Am*. 1996;21A:532.
6. Wei FC, Colony LH, Chen H C, Chuang CC, Noordhoff MS. Combined second and third toe transfer. *Plast Reconstr Surg*. 1989;84:651-61.
7. Wei FC, el-Gammal TA, Lin CH, Chuang CC, Chen HC, Chen SH. Metacarpal hand: classification and guidelines for microsurgical reconstruction with toe transfers. *Plast Reconstr Surg*. 1997;99:122-8.
8. Wei FC, Santamaria E. Toe-to-finger reconstruction. En: Green DP, Hotchkiss RN, Pederson WC, editors. *Green's operative hand surgery*, vol. 2. 4<sup>th</sup> ed. New York: Churchill Livingstone; 1999. p. 1327-52.
9. Wei FC, Lutz BS, Cheng SL, Chuang DC. Reconstruction of bilateral metacarpal hands with multiple-toe transplantations. *Plast Reconstr Surg*. 1999;104:1698-704.
10. Yu Z-J, Huang Y. Sixty-four cases of thumb and finger reconstruction using transplantation of the big toe skin-nail flap combined with the second toe or the second and third toes. *Plast Reconstr Surg*. 2000;106:335-41.
11. Piñal F del, García Bernal JF, Delgado J, Regalado J, Sanmartín M, Fernández-García D. Overcoming soft tissue deficiency in toe to hand transfer using a dorsalis pedis fasciosubcutaneous-toe free flap: Surgical technique. *J Hand Surg Am*. 2005;30A:106-14.
12. Lister GD, Kalisman M, Tsai T-M. Reconstruction of the hand with free microvascular toe-to hand transfer: Experience with 54 toe transfer. *Plast Reconstr Surg*. 1983;71:372-84.
13. Chuang DCC, Colony LH, Chen HC, Wei FW. Groin flap design and versatility. *Plast Reconstr Surg*. 1989;84:100-07.
14. Wei FC. Tissue preservation in hand injury: The first step to toe-to-hand transplantation (Editorial). *Plast Reconstr Surg*. 1998;102:2497-501.
15. Espinar Salom E. Sistemas de valoración de los resultados clínicos en la cirugía del pie. En: Núñez-Samper Pizarroso M, editor. *Técnicas quirúrgicas de cirugía del pie*. Barcelona: Masson; 2003. p. 361-70.

16. del Piñal F, Herrero F, García Bernal FJ, Jado E, Ros MJ. Minimizing impairment in laborers with finger losses distal to the proximal interphalangeal joint by second toe transfer. *Plast Reconstr Surg*. 2003;112:1000-11.
17. del Piñal F. Invited personal view article. The indications for toe transfer after «minor» finger injuries. *J Hand Surg Br*. 2004;29B:120-9.
18. Hofer SO, Cronin KJ, Morrison WA. A long-term study of ring finger transfer in the reconstruction of transmetacarpal amputations. *J Hand Surg (Am)*. 2002;27A:1087-94.
19. Büchler U. Symbrachidactyly. En: Gupta A, Kay SPJ, Scheker LR, editors. *The growing hand*. London: Mosby; 2000. p. 213-23.
20. Foucher G. Discussion. *Plast Reconstr Surg*. 1998;102:2413.
21. Foucher G. Indications for reconstruction in finger mutilations. En: Foucher G, editor. *Reconstructive surgery in hand mutilation*. London: Martin-Dunitz; 1997. p. 109-19.
22. Kay SP, Wiberg M. Toe to hand transfer in children. Part 1: technical aspects. *J Hand Surg Br*. 1996;21B:723-4.
23. El-Gammal TA, Wei FC. Microvascular toe transfer in children. En: Gupta A, Kay SPJ, Scheker LR, editors. *The growing hand*. London: Mosby; 2000. p. 1000-8.
24. García Julve G, Martínez Villen G. The multiple monoblock toe-to-hand transfer in digital reconstruction. a report of ten cases. *J Hand Surg Br*. 2004;29B:222-9.
25. Buncke GM, Buncke HJ, Oliva A, Lineaweaver WC, Siko PP. Hand reconstruction with partial toe and multiple toe transplants. *Clin Plast Surg*. 1992;19:859-70.
26. Cheng M-H, Wei F-C, Santamaria E, Cheng S-L, Lin C-H, Cheng SHT. Single versus double arterial anastomoses in combined second- and third-toe transplantation. *Plast Reconstr Surg*. 1998;102:2408-12.
27. O'Farrell DA, Montella BJ, Babor JL, Levin LS. Long-term follow-up of 50 Duke silicone prosthetic fingers. *J Hand Surg Br*. 1996;21B:696-700.
28. Pillet, J. Aesthetic prostheses. En: Foucher G, editor. *Reconstructive surgery in hand mutilation*. London: Martin Dunitz; 1997. p. 169-78.
29. Didierjean A. Psychological aspects. En: Foucher G, editor. *Reconstructive surgery in hand mutilation*. London: Martin Dunitz; 1997. p. 151-4.
30. Pillet J, Didierjean-Pillet A. Aesthetic hand prosthesis: gadget or therapy? Presentation of a new classification. *J Hand Surg*. 2001;26B:523-8.

**Conflict of interests:** We, the authors, have not received any economic support to carry out this study. Nor have we signed any agreement with any commercial firm to receive benefits or fees. On the other hand, no commercial firm has provided nor will provide economic support to non-profit foundations, educational institutions or any of the other non-profit organizations that we are members of.